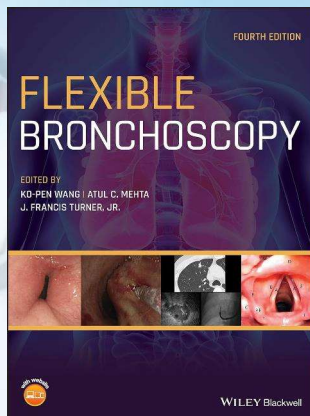
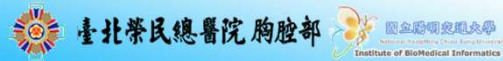

介入性支氣管鏡概論

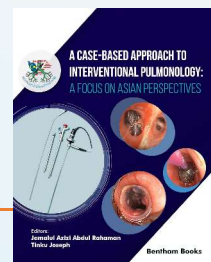
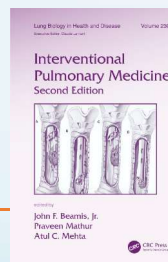



Introduction of Interventional bronchoscopy

趙恒勝 (Heng-sheng Chao)

Department of Chest Medicine, Taipei Veterans General Hospital
Institute of Bio-Medical Informatics, National Yang-Ming University
Email: hschao2@vghtpe.gov.tw



Outline/Range/definition for Interventional bronchoscopy



<p>1. 介紹</p> <ul style="list-style-type: none"> - 介入性支氣管鏡的定義 - 介入性支氣管鏡的發展歷史 - 介入性支氣管鏡的重要性 	<p>3. 介入性支氣管鏡的適應症</p> <ul style="list-style-type: none"> - 氣道異物的移除 - 支氣管狹窄的治療 - 氣管內止血和栓塞治療 - 氣管內支架置入 - 肺容積減除(手)術 	<p>6. 介入性支氣管鏡的品質控制</p> <ul style="list-style-type: none"> - 設備的維護和消毒 - 操作者的培訓 - 常規監測和異常報告
<p>2. 介入性支氣管鏡的設備</p> <ul style="list-style-type: none"> - 支氣管鏡的類型 - 軟式支氣管鏡 - 硬式支氣管鏡 - 介入性支氣管鏡的專用設備 - 氣道異物夾 - 氣球擴張導管 - 電燒和雷射探頭 - 支架置入系統 - Endobronchial valve 	<p>4. 介入性支氣管鏡的操作技術</p> <ul style="list-style-type: none"> - 患者準備和麻醉 - 支氣管鏡的操作 - 各種介入性技術的重點 - 併發症的預防和處理 	<p>7. 肋膜腔鏡</p>
	<p>5. 介入性支氣管鏡的新進展</p> <ul style="list-style-type: none"> - 支氣管鏡導航系統 - 機器人輔助支氣管鏡 - 3D列印支架 	<p>8. 總結</p> <ul style="list-style-type: none"> - 介入性支氣管鏡在臨床治療中的重要作用 - 介入性支氣管鏡技術的發展前景




介入性支氣管鏡

定義：

- 廣義的定義：
所有的支氣管鏡檢查/治療，
都屬於侵入性檢查/治療
(反正都是要簽同意書)
- 狹義的定義
僅指治療性支氣管鏡
 - 排除了biopsy, EBUS-TBNA, mini-probe +/- guide-sheath biopsy, BAL, etc.....

2020 AJRCCM

Check for updates

STATE OF THE ART

Interventional Bronchoscopy

Gerard J. Criner^{1*}, Ralf Eberhardt², Sebastian Fernandez-Bussy³, Daniela Gompelmann², Fabien Maldonado⁴, Neal Patel⁵, Pallav L. Shah⁶, Dirk-Jan Stebos⁸, Arshang Valipour⁷, Momen M. Wahidi⁹, Mark Weir¹, and Felix J. Herth²

¹Lewis Katz School of Medicine at Temple University, Philadelphia, Pennsylvania; ²Pneumology and Critical Care Medicine, Thoraxklinik, University of Heidelberg, Heidelberg, Germany; ³Division of Pulmonary Medicine, Mayo Clinic, Jacksonville, Florida; ⁴Department of Medicine and Department of Thoracic Surgery, Vanderbilt University, Nashville, Tennessee; ⁵Respiratory Medicine at the Royal Brompton Hospital and National Heart & Lung Institute, Imperial College, London, United Kingdom; ⁶Department of Pulmonary Diseases, University Medical Center Groningen, University of Groningen, Groningen, the Netherlands; ⁷Department of Respiratory and Critical Care Medicine, Krankenhaus Nord, Vienna, Austria; and ⁸Division of Pulmonary, Allergy, and Critical Care Medicine, Department of Medicine, Duke University School of Medicine, Durham, North Carolina

ORCID IDs: 0000-0003-1267-3483 (G.J.C.); 0000-0002-9052-4638 (P.L.S.).

2009 Respirology

Official Journal of the Asian Pacific Society of Respirology

Respirology



Free Access

Management of complications from diagnostic and interventional bronchoscopy

Pyng LEE✉, Atul C. MEHTA, Praveen N. MATHUR

First published: 02 September 2009 | <https://doi.org/10.1111/j.1440-1843.2009.01617.x> | Citations: 20

介入性支氣管鏡

定義：

- 廣義的定義：
所有的支氣管鏡檢查/治療，
都屬於侵入性檢查/治療
(反正都是要簽同意書)
- 狹義的定義
僅指治療性支氣管鏡
 - 排除了biopsy, EBUS-TBNA, mini-probe +/- guide-sheath biopsy, BAL, etc.....

介入性支氣管鏡的適應症

- 腫瘤 tumor
- 異物 Foreign body
- 狹窄 tracheal-bronchial stenosis
- 支架 Stenting
- 減容 Lung volume reduction
- 止血 bleeding
- 注射 injection
- 全肺灌洗 whole lung lavage

介入性支氣管鏡


介入性支氣管鏡的設備-1

- 硬式支氣管鏡
- 治療用軟式支氣管鏡 1T290
- 雷射主機
- 電燒/ APC主機
- 冷凍主機
- PDT主機
- 維生系統：high-flow、呼吸器、麻機、ECMO

介入性支氣管鏡的設備-2


- 夾子，異物夾，forceps, basket
- 電燒探頭，電燒loop，APC探頭
- 雷射探頭
- PDT diffusion probe
- 冷凍探頭, cryospray
- 氣球擴張設備
- 支架置入系統
- 內視鏡注射
- Endobronchial valve/plug/coil
- Thermal vapor ablation
- Bronchial thermoplasty, Rheoplasty, Targeted/Total lung denervation

病灶的量測、治療規劃；Lesion/Timing Evaluation

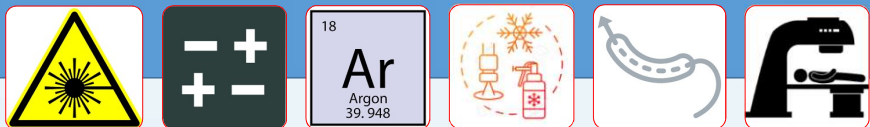


2W
2CM


生命支持系統；Life Support



最適用的儀器設備；Tools/Equipment



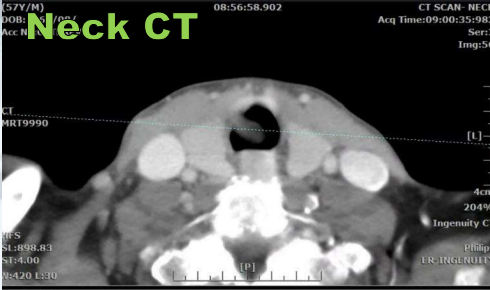
效果維持；Maintenance



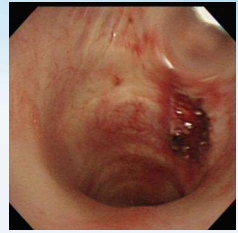
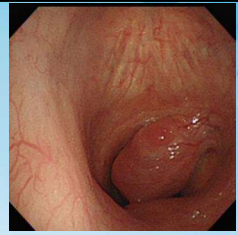
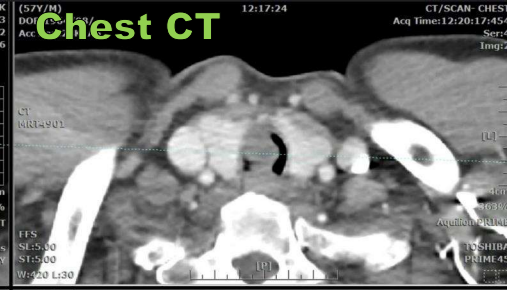病灶的量測、治療規劃
治療前的功課

A pliable tracheal tumor -- A Neurofibroma

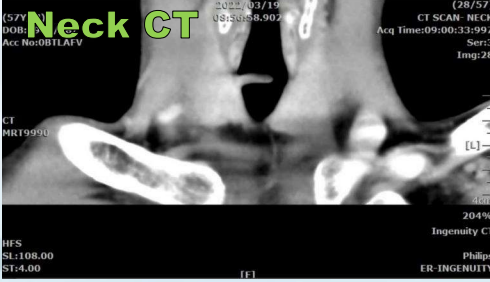Neck CT



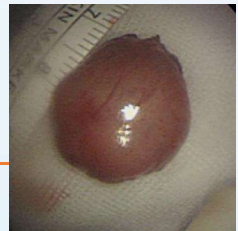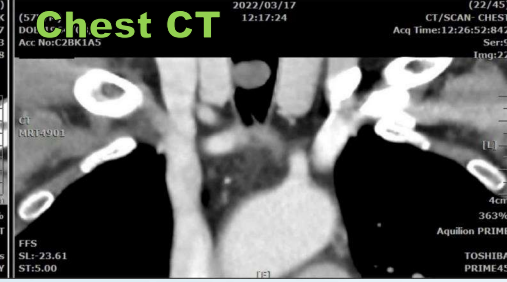Chest CT



Neck CT



Chest CT





治療時 生命支持系統
的選擇

地點的選擇

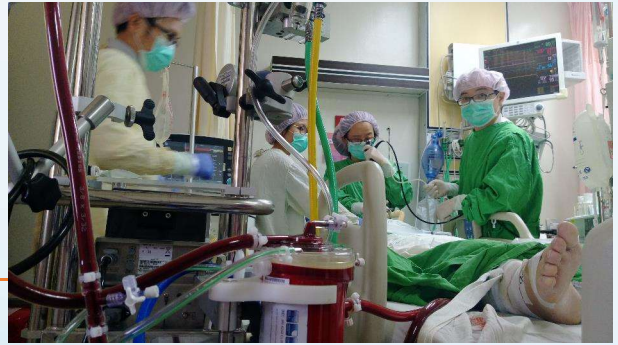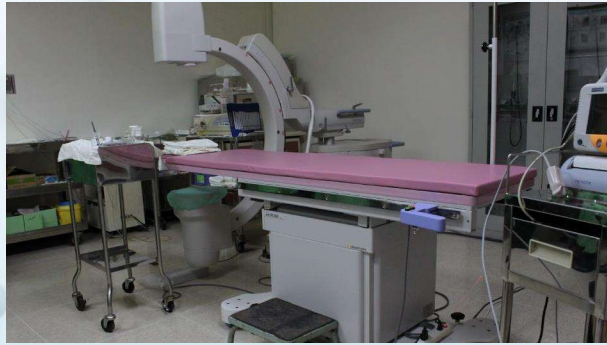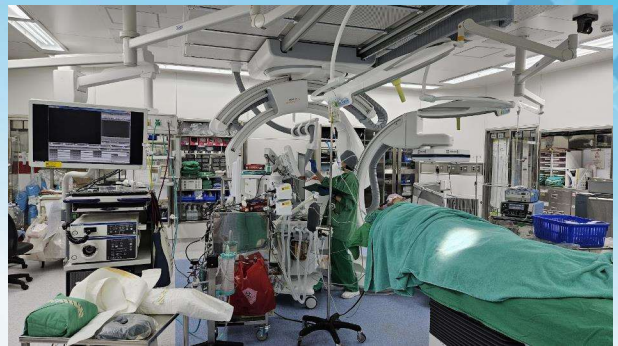術式的選擇

麻醉的選擇 (life support?)

Hybrid-OR 
CS OR
ENT OR

 氣管鏡室 (+/- fluoroscopy)

ICU 



介入性支氣管鏡的器械

介入性支氣管鏡

介入性支氣管鏡的設備-1

- 硬式支氣管鏡
- 治療用軟式支氣管鏡 1T290
- 雷射主機
- 電燒/ APC主機
- 冷凍主機
- PDT主機
- 維生系統：high-flow、呼吸器、麻機、ECMO

介入性支氣管鏡的設備-2

- 夾子，異物夾，forceps, basket
- 電燒探頭，電燒loop，APC探頭
- 雷射探頭
- PDT diffusion probe
- 冷凍探頭, cryospray
- 氣球擴張設備
- 支架置入系統
- 內視鏡注射
- Endobronchial valve/plug/coil
- Thermal vapor ablation
- ~~Bronchial thermoplasty,~~
Rheoplasty, Targeted/Total lung denervation

夾子，異物夾，forceps，basket



治療儀器分類

熱治療

電燒 (Electrocoagulation)
 雷射 (Laser)
 電漿 (Argon Plasma)
 熱蒸氣 (Vapor)
 Thermoplasty
 RFA, microwave

冷治療

Cryoablation
 Cryobiopsy
 Cryospray

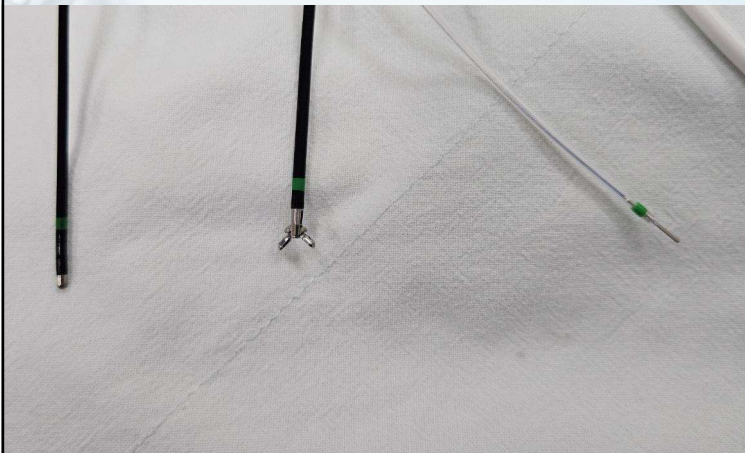
光化學治療

Photodynamic therapy

物理治療

stent, valve, coil,

電燒探頭，電燒loop，APC探頭
 雷射探頭
 冷凍探頭, cryospray



氣管支氣管 氣球擴張



катетры для баллонной дилатации бронхов и трахеи. Катетры для баллонной дилатации бронхов и трахеи. Катетры для баллонной дилатации бронхов и трахеи.

катетры для баллонной дилатации бронхов и трахеи. Катетры для баллонной дилатации бронхов и трахеи. Катетры для баллонной дилатации бронхов и трахеи.

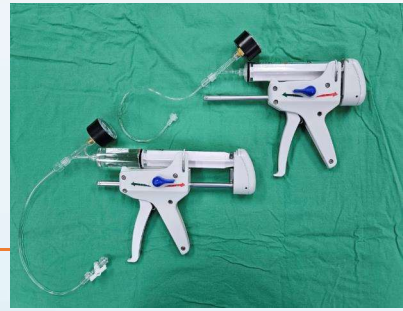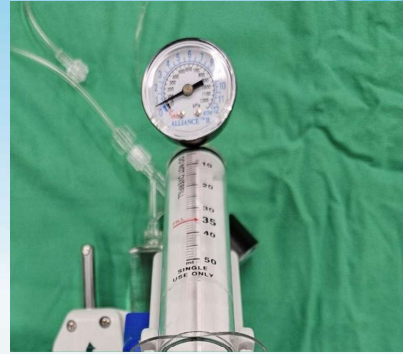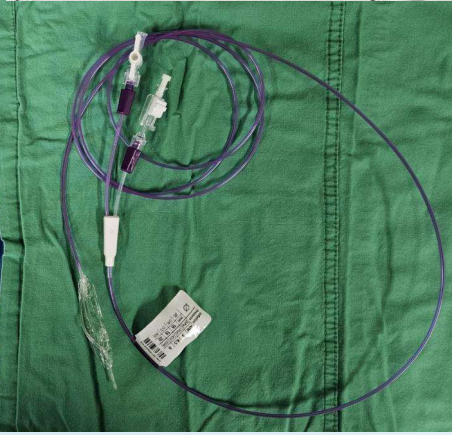
Состав (1)

Ø	mm	12	13.5	15
Ø	mm	120	140.5	145
Inflation Pressure (kPa)	ATM	3	4.5	8
	(kPa)	304	436	811

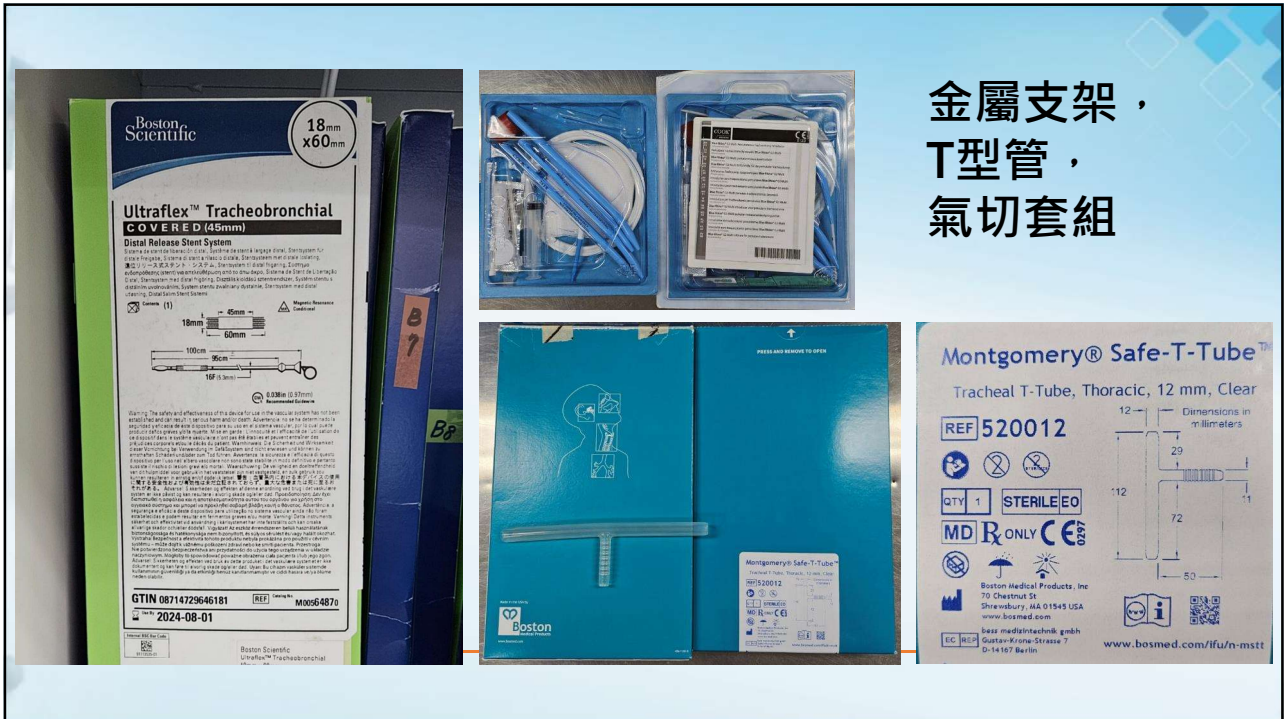*Maximum Inflation Pressure DO NOT EXCEED

Includes: Dilator

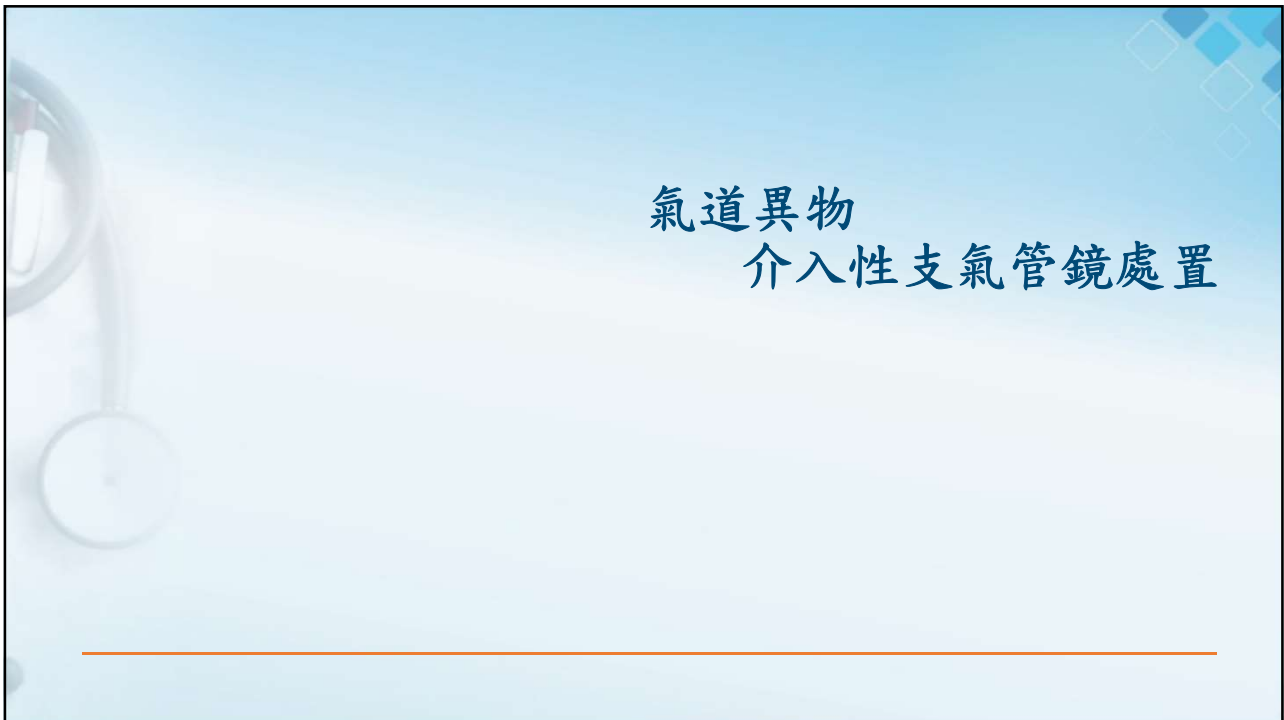Ø 2.8mm Minimum Size



氣管、支氣管的植入物

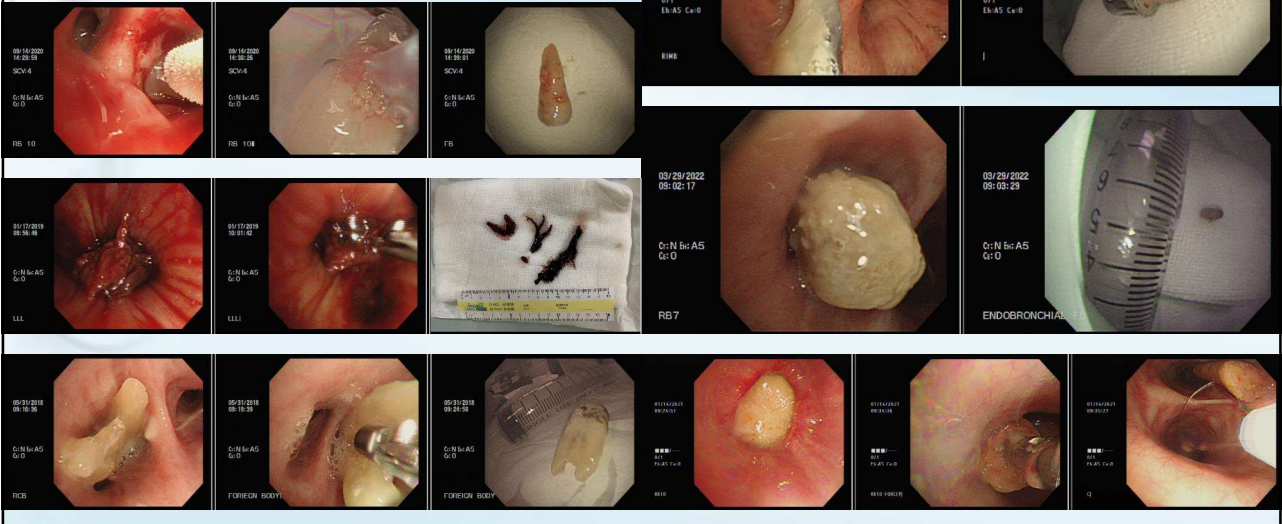


金屬支架，
T型管，
氣切套組

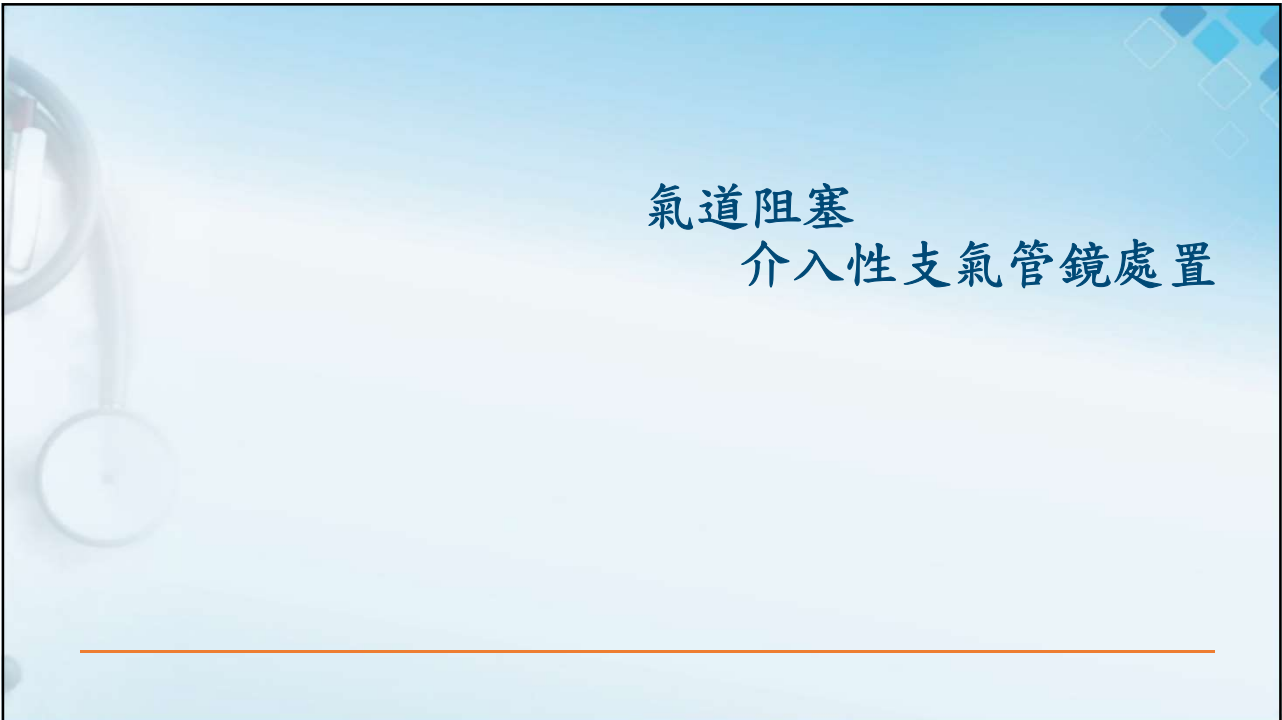

氣道異物
介入性支氣管鏡處置

氣道異物 Airway Foreign Body

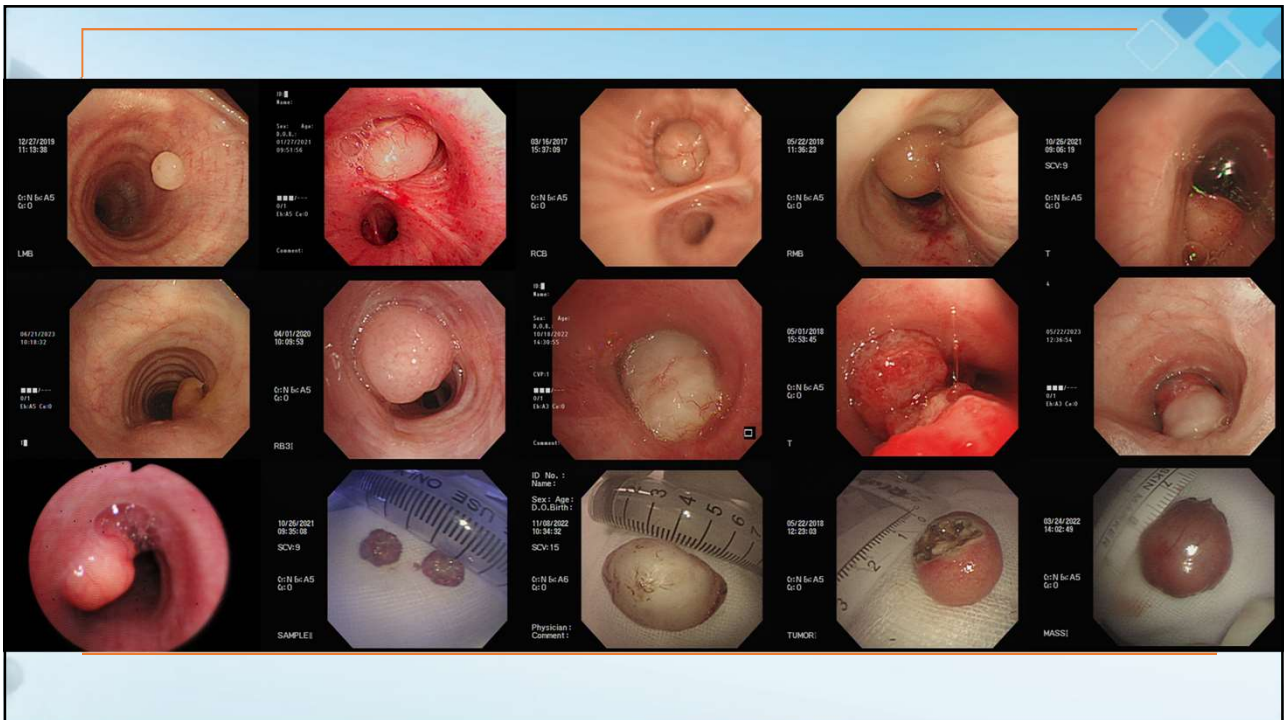
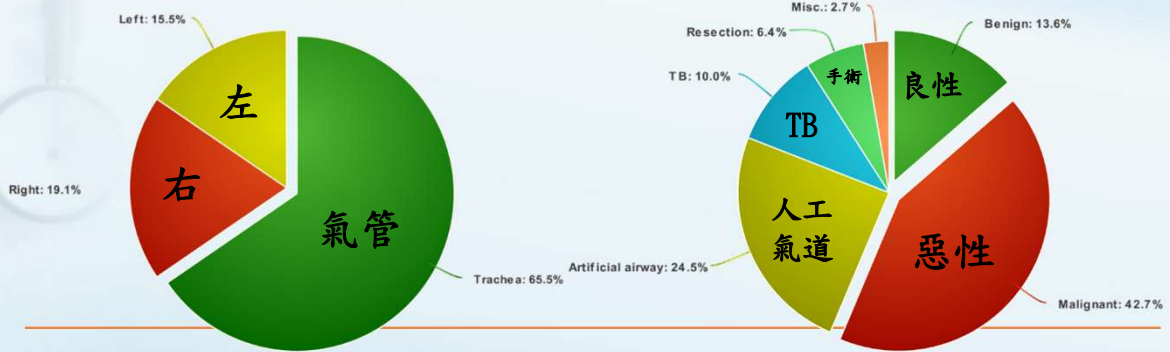


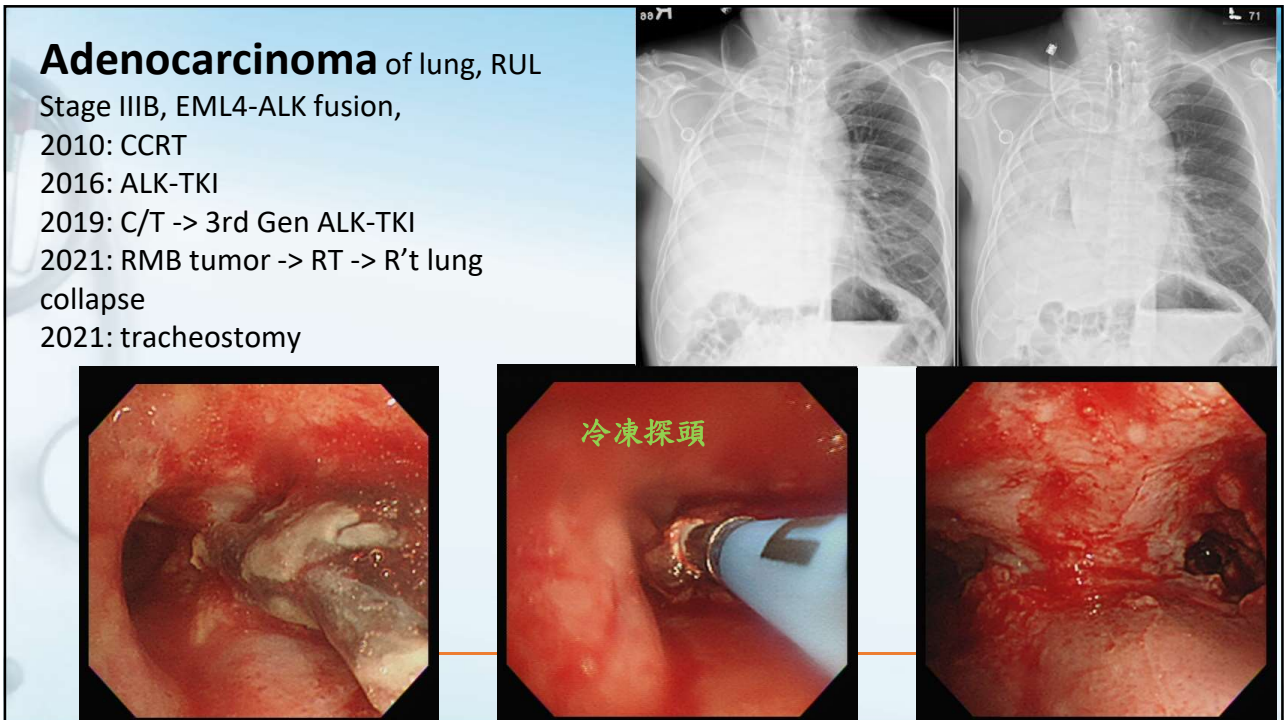
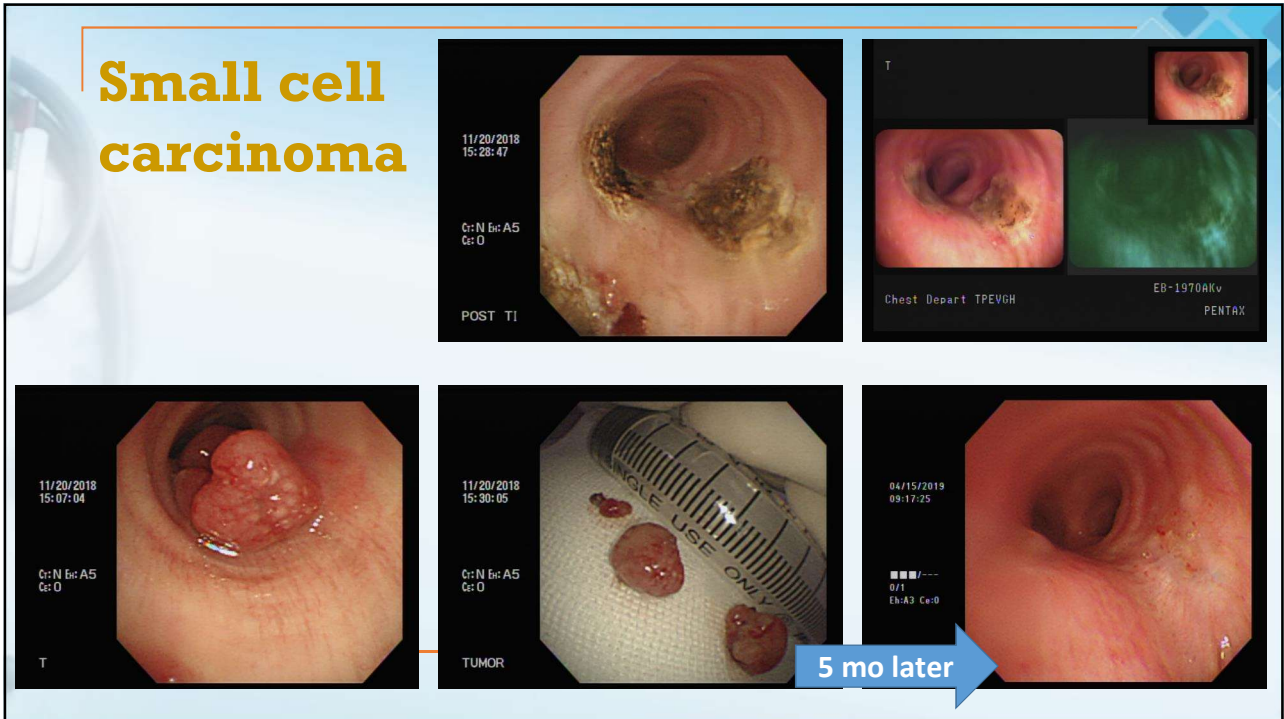
氣道阻塞 介入性支氣管鏡處置



Airway stenosis, burden/distribution in VGHTPE

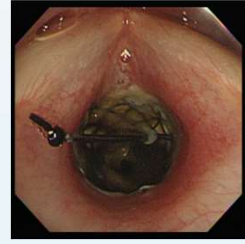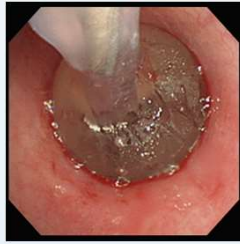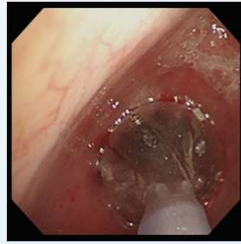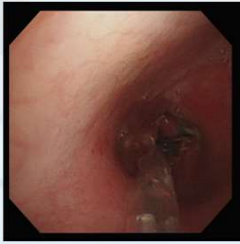
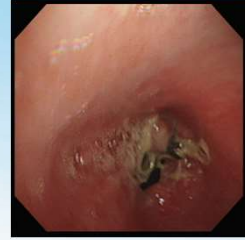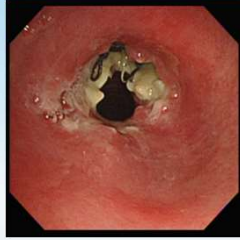- Between 2011-01 to 2023-06
- Average service: 84 case/year
- Total: 110 patients
- Median Tx: 2/patient





Tracheal SqCC tracheal stenosis

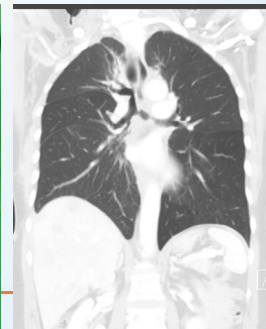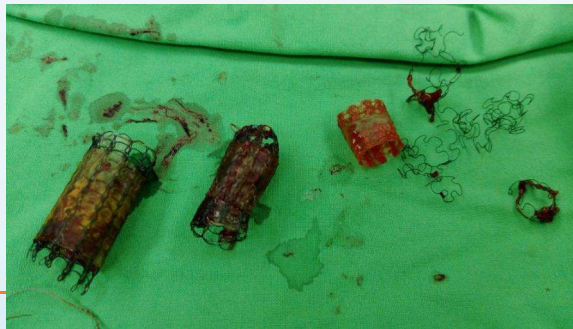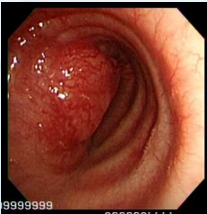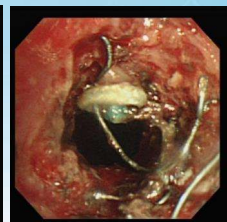
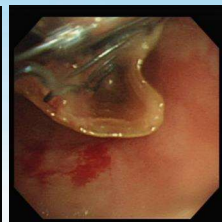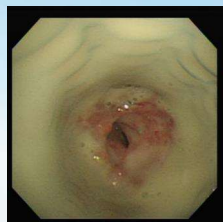
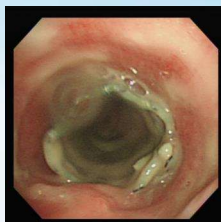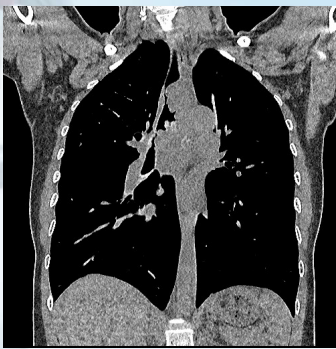
- s/p laser
- s/p Tr segmental resection
- s/p balloon dilatation
- s/p full covered stenting
- s/p laser for foreign body



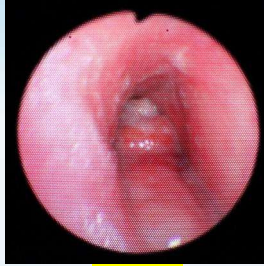
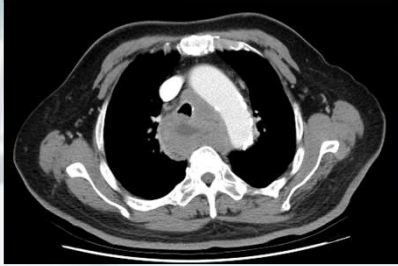氣球擴張

支架

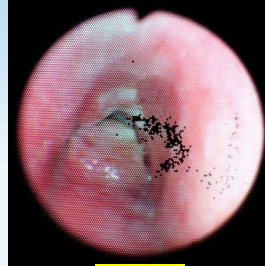
Adenoid Cystic Carcinoma



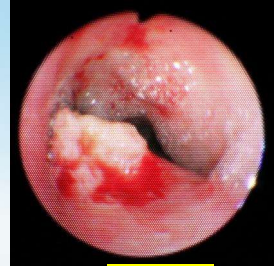
Nd-YAG + Radiotherapy (Esophageal Ca)



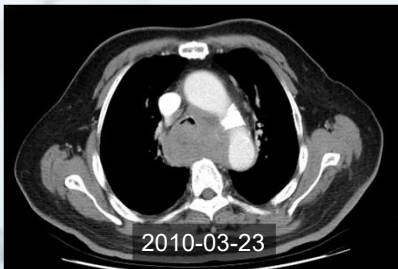Day 0.



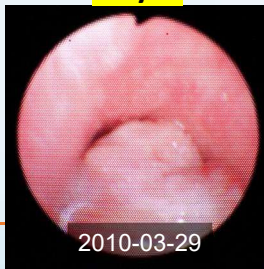Day 4.



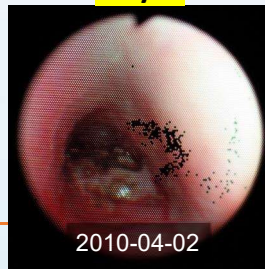Day 17.



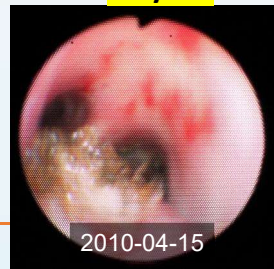2010-03-23



2010-03-29



2010-04-02



2010-04-15

良性氣道阻塞
介入性支氣管鏡處置

Types of postintubation stenosis

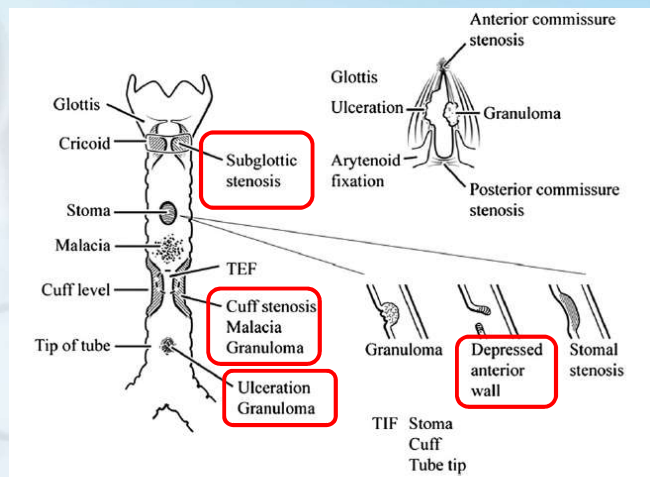


Fig. 4. The various types of tracheal injuries related to intubation. TEF, tracheoesophageal fistula; TIF, tracheoinnominate artery fistula. (From Grillo HC. Surgery of the trachea and bronchi. Hamilton, Ontario: BC Decker; 2004. p. 302; with permission.)

Myer-Cotton staging system

Classification	From	To
Grade I	 No Obstruction	 50% Obstruction
Grade II	 51% Obstruction	 70% Obstruction
Grade III	 71% Obstruction	 99% Obstruction
Grade IV	No Detectable Lumen	

Surg Clin N Am 90 (2010) 1065–1089

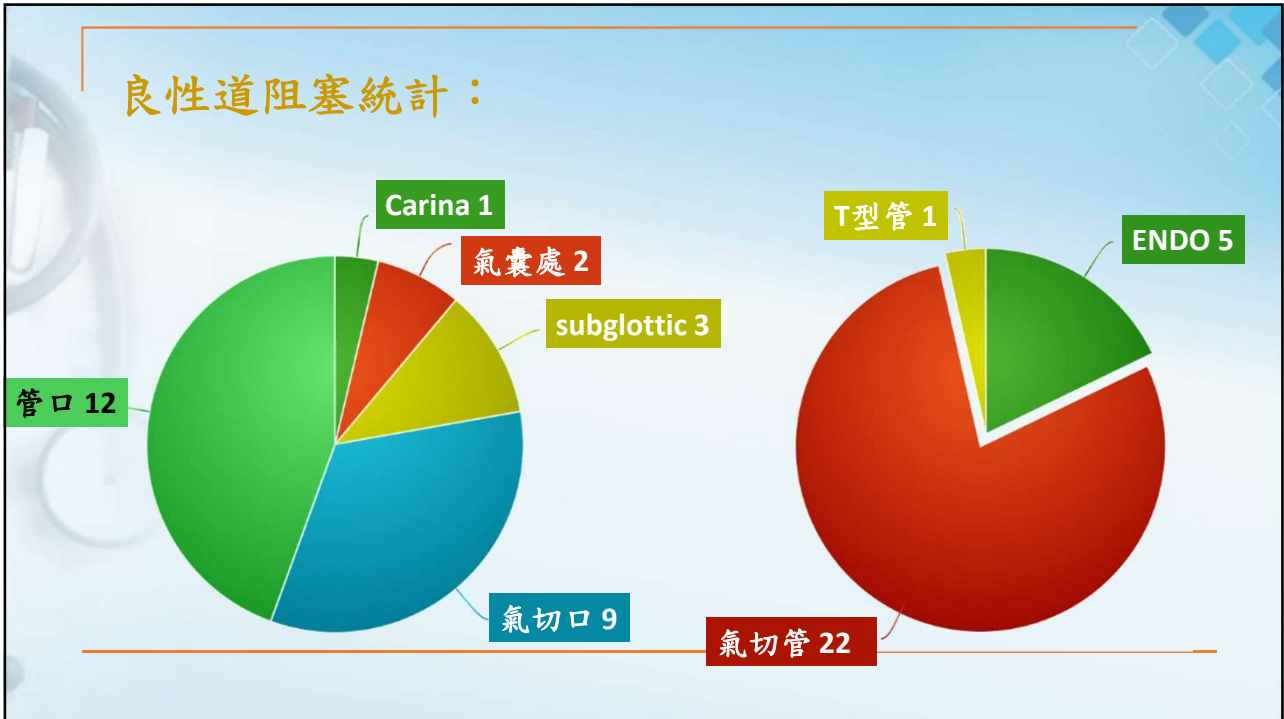
Pathogenesis

- Necrosis induced by **pressure**-related loss of regional blood flow
- Followed by fibrosis and local stricture
- Increased **cuff pressure**, decreased systemic perfusion pressure, or direct pressure on the margin of the airway
- Most common at the endotracheal **tube cuff site**

Other Risk Factors

- **Prolonged** intubation period,
- **Traumatic** intubation,
- **History** of previous intubation or previous tracheostomy,
- Excessive corticosteroid **steroid** usage,
- Advanced age,
- Female and estrogen effect,
- Severe respiratory failure,
- Severe reflux disease,
- Autoimmune diseases
- Obstructive sleep apnea,
- Radiation therapy for oropharyngeal and laryngeal cancer

Surg Clin N Am 90 (2010) 1065–1089



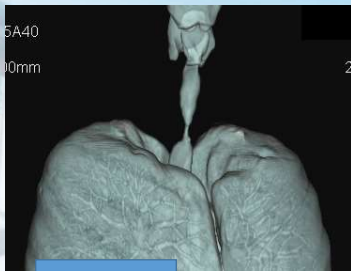
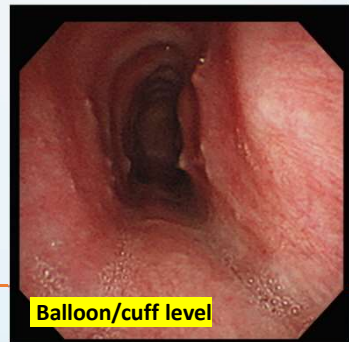
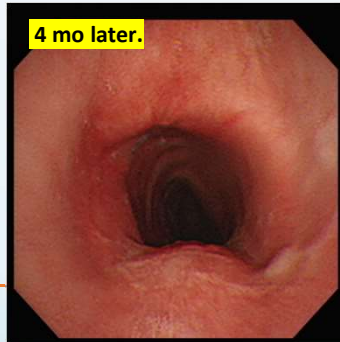
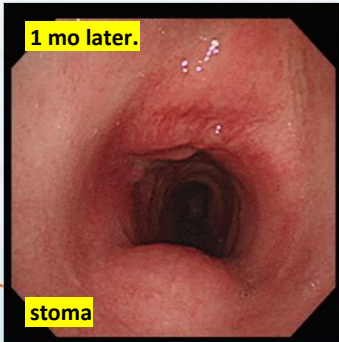
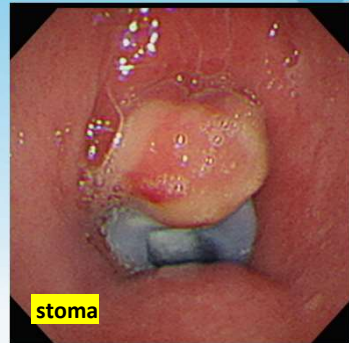
ETT Tip stenosis

Severe mitral stenosis

2022-06-02 : MITRAL VALVE REPLACEMENT
 2022-06-02 : DEBAKEY TYPE I AORTIC DISSECTION
 2022-06-02 : ILIAC ARTERY STENT
 2022-06-02 : SMA stenting
 2022-06-02 : EXTRACORPOREAL CIRCULATION
 *** complicated with diffuse ischemic bowel disease

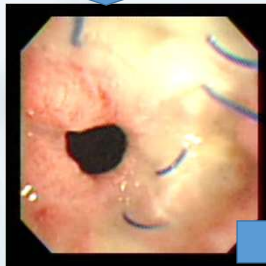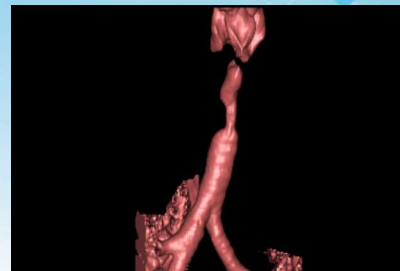
Tracheostomy with granulation like protrusion

- Depressed anterior wall
- Remove tracheostomy tube, **No Tx**

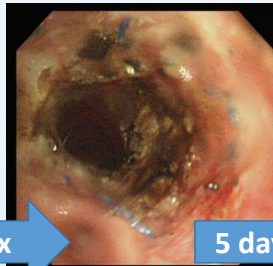


Tr resection

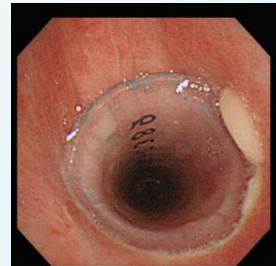
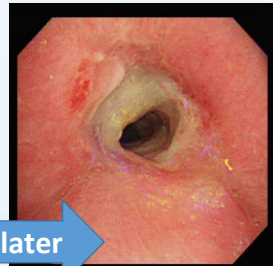
- Thyroid papillary ca
Tracheostomy, r/o granulation tissue over subglottic region.
- Under ECMO stand by
- stricture over upper trachea below glottis, **3 tracheal ring** in length, **2 cm** long
- Segmental resection of Trachea and end-to-end anastomosis



Laser Tx

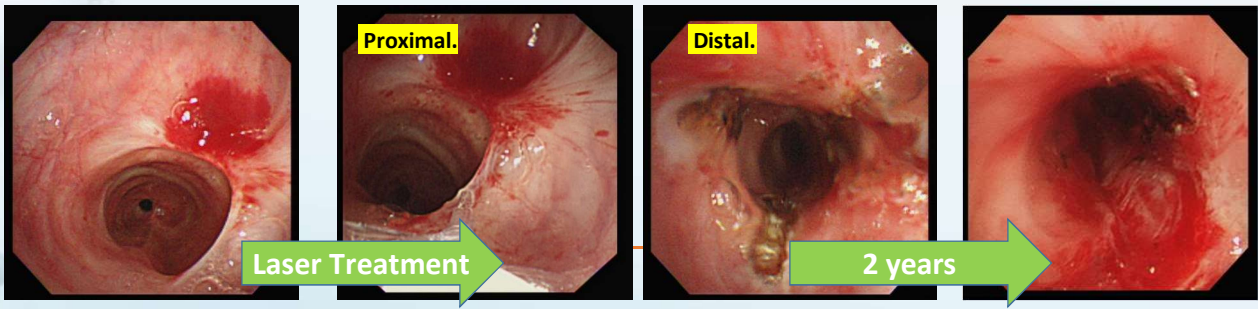
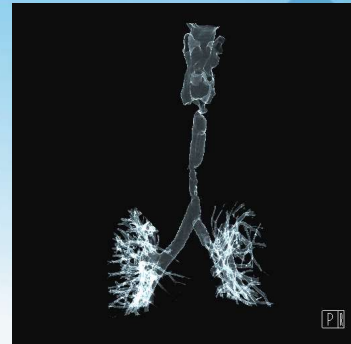


5 day later

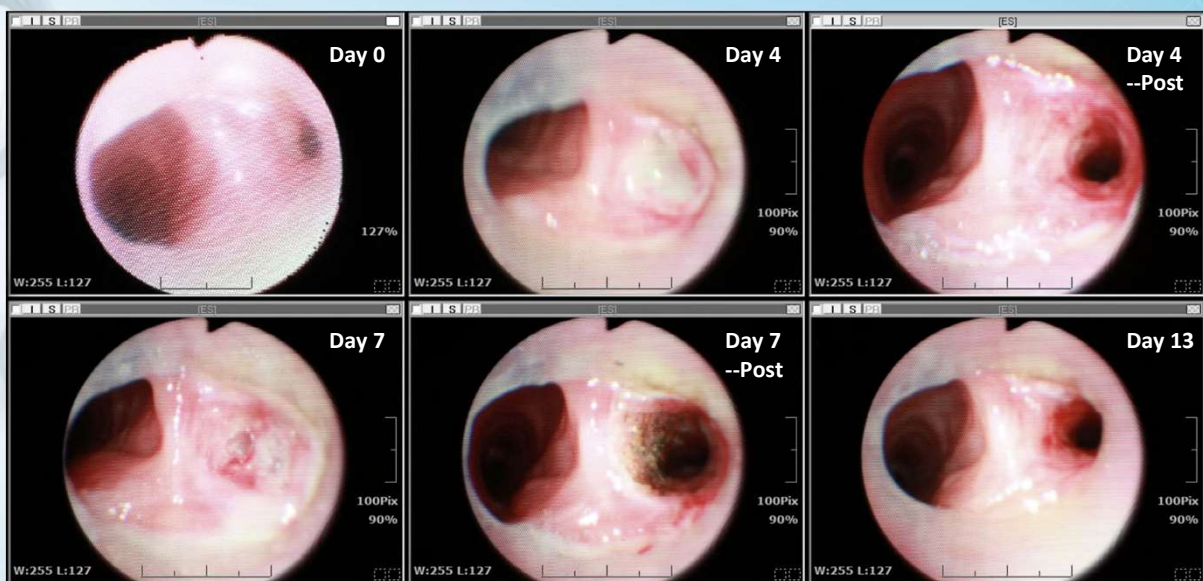


Endobronchial TB with tracheal stenosis

- Long segment
- Tx as little as possible
- T-tube ? Patient refused



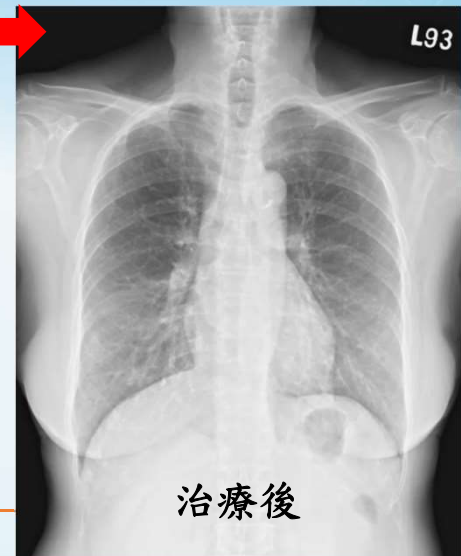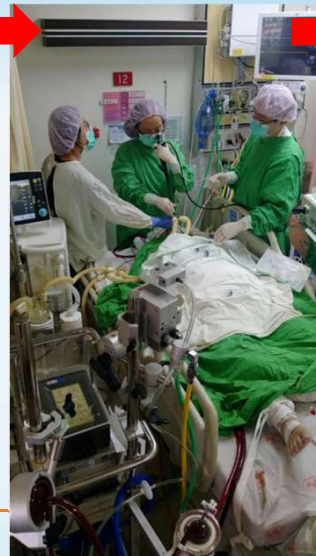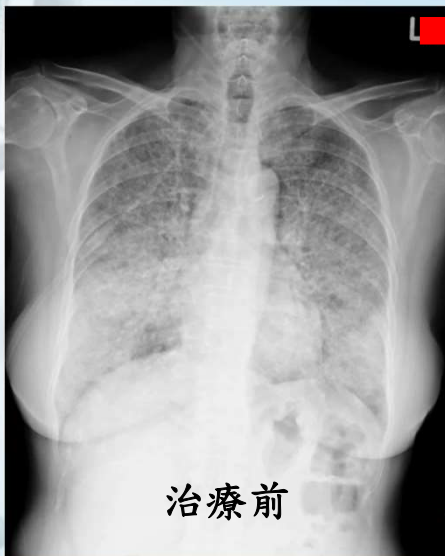s/p cryotherapy and acute stenosis



其他
介入性支氣管鏡處置

Whole lung lavage
Photodynamic therapy
Lung volume reduction
Bronchial thermoplasty
Others

肺蛋白沈著症 iPAP

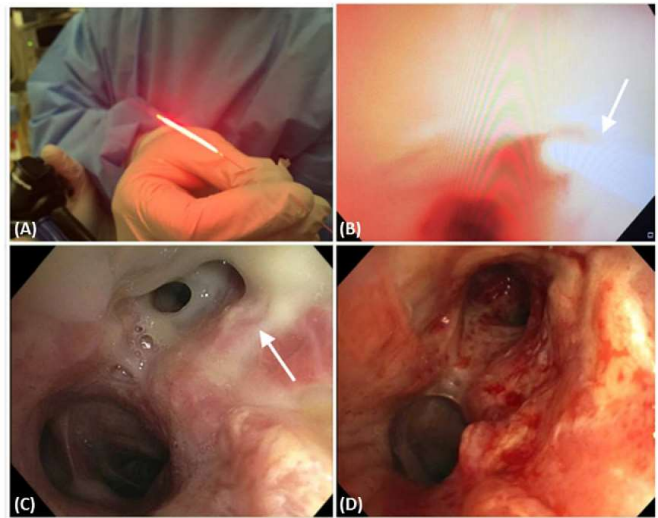
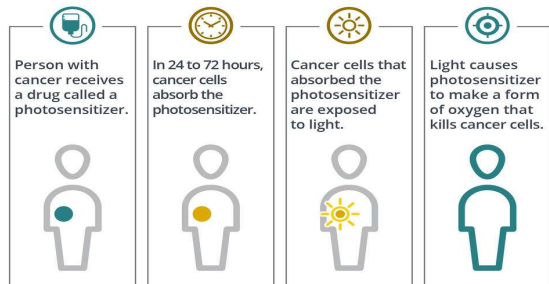


Whole lung lavage fluid



PDT, photodynamic therapy

PHOTODYNAMIC THERAPY

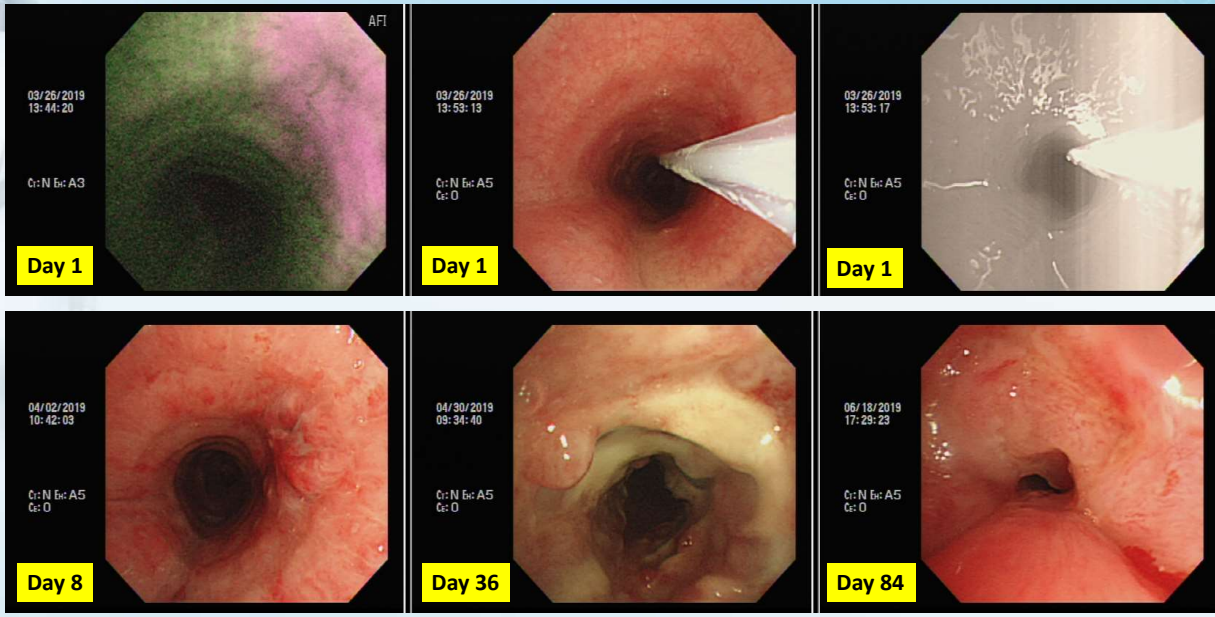


	A	B	C
RLS			
RIB			
Date	Apr 4, 2019	May 30, 2019	Oct 26, 2020

Photodynamic Therapy of Non-Small Cell Lung Cancer. Narrative Review and Future Directions. DOI:10.1513/AnnalsATS.201509-650FR

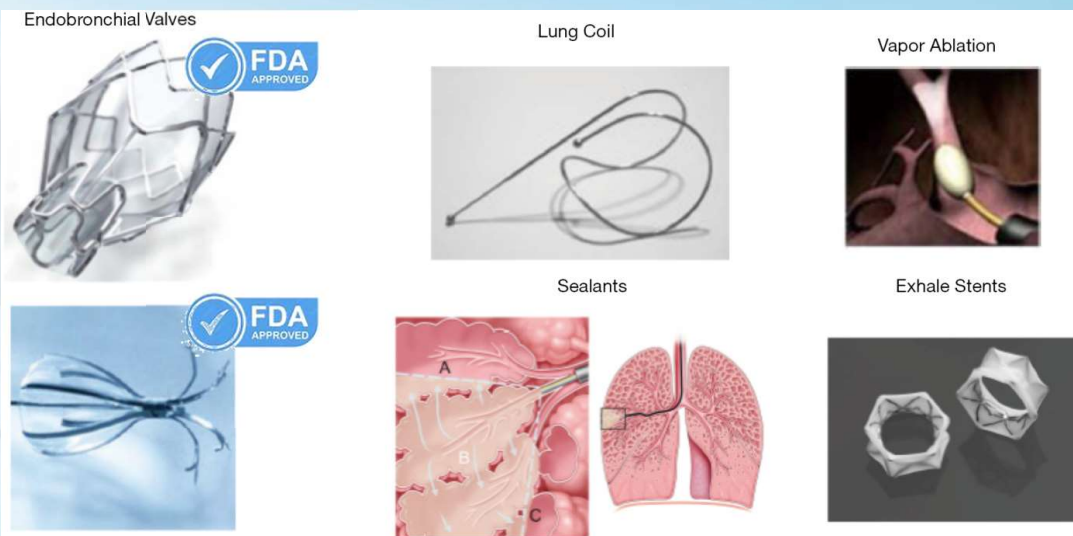
Photodynamic Therapy for Recurrent Early Central Lung Cancer of Great Longitudinal Extent Following Two Surgical Lung Resections: A Case Report. doi.org/10.1016/j.pdpdt.2021.102400

PDT, photodynamic therapy



2020

Lung volume reduction treatment, 肺減積治療



Zantah, M., Gangemi, A. J., & Criner, G. J. (2020). Bronchoscopic lung volume reduction: status quo. *Annals of translational medicine*, 8(21).

2020

Lung volume reduction treatment, 肺減積治療

Table 1 Bronchoscopic lung volume reduction techniques

Mechanism	Device/technique	Reversibility	Dependent on CV	Published RCT	FDA available
Target lobe atelectasis	One-way EBV	Yes	Yes	Yes	Yes
	Self-activating coils	Partial	No	Yes	No
Targeted destruction and remodeling of emphysematous tissue	Biological lung volume reduction	No	No	Yes	No
	Bronchoscopic thermal vapour ablation	No	No	Yes	No
Bypass tract stenting	Endobronchial stents	No	No	Yes	No

CV, collateral ventilation; EBV, endobronchial valves; RCT, randomized controlled trial.

Zantah, M., Gangemi, A. J., & Criner, G. J. (2020). Bronchoscopic lung volume reduction: status quo. *Annals of translational medicine*, 8(21).

Bronchial Thermoplasty

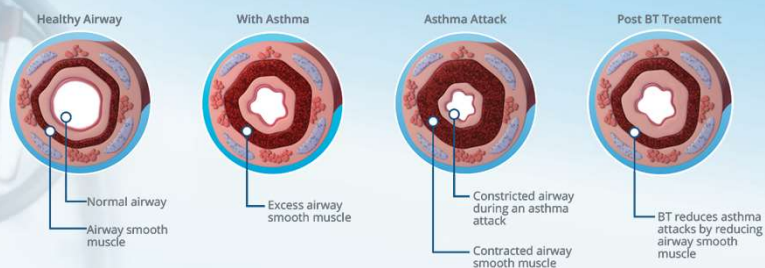
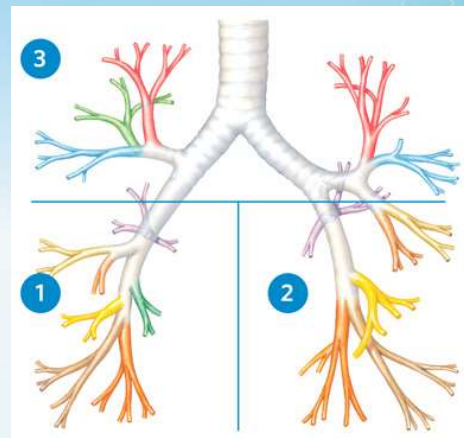
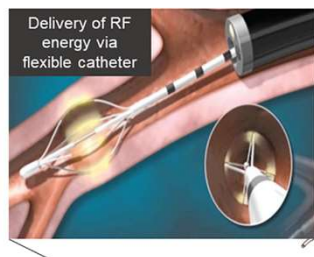


FIGURE 1 Bronchial thermoplasty: currently understood mechanisms of action involving ASM, associated innervation and distal airway volume. Reproduced with permission of the ©ERS 2022. *European Respiratory Review* 23 (134) 510–518; <https://doi.org/10.1183/09059180.00005114> Published 1 December 2014. ASM, airway smooth muscle; RF, radiofrequency



d'Hooghe, et al. (2018). Emerging understanding of the mechanism of action of bronchial thermoplasty in asthma. *Pharmacology & therapeutics*, 181, 101-107.
Hashmi, M. D., et al. (2022). Bronchial thermoplasty: state of the art. *Respirology*, 27(9), 720-729.

Bronchial Thermoplasty

TABLE 1 (Continued)

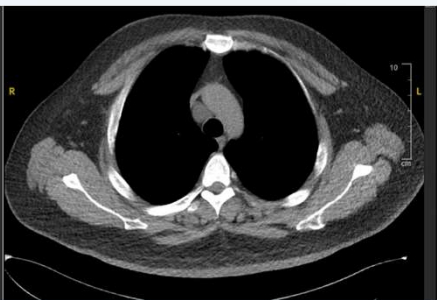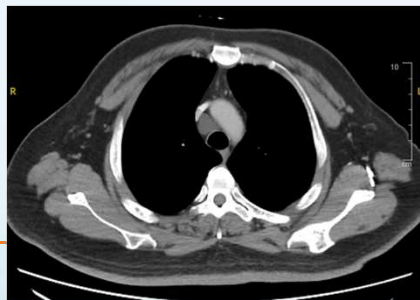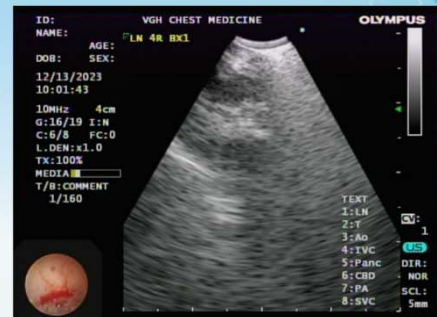
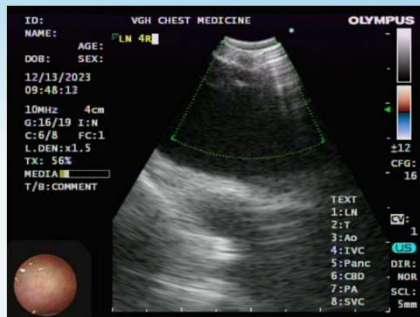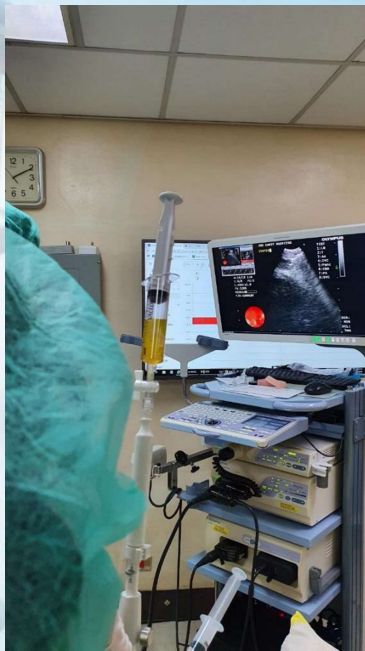
Trial, publication year, subjects included (N)	Design	Subject characteristics	Asthma severity and baseline controller medications	Results
BT10+, 2021 N = 192	International, multicentre follow-up study	Mean age: 54 years. Mean FEV1 73% predicted	18/56 control/sham patients received BT after the initial trials concluded. Maintenance OCS use noted in 3%–5% of patients and 7%–8% received biologic medications	No significant difference in proportion experiencing severe exacerbations 12 months prior to BT10+ visit compared to years 1 and 5 after BT. 7% of AIR2 participants who underwent BT developed bronchiectasis but without clinical symptoms
TASMA, 2021 N = 40	Multicentre, randomized control trial	Age: 18–65 years, FEV1 ≥ 50% predicted	Severe asthma utilizing WHO or IMI definition. OCS < 20 mg/day allowed	Significant decrease in ASM mass in immediate BT group compared to no change in delayed group following 6 months of standard care

TABLE 2 Current challenges and potential next steps in

Current challenge
Limited markers of treatment success ⁵⁶
Lack of blinded long-term follow-up beyond 1 year
Frequent worsening of asthma symptoms in the short term
Limited, although encouraging, cost-effectiveness data
Limited, although increasing, understanding of the role of specific asthma endotypes/phenotypes ⁵⁵
Difficulties with insurance coverage even when patients meet the conventional treatment criteria ⁵⁹
Absence of direct comparison with novel biologic therapies ⁶⁰

Hashmi, M. D., et al. (2022). Bronchial thermoplasty: state of the art. *Respirology*, 27(9), 720-729.

A 4.0x1.8cm cystic nodule, no significant interval change.



2021-09-20 04:59:59

Conclusion

- 1) 介入性支氣管鏡處置是個挑戰度很高的侵入性治療
- 2) 介入性支氣管鏡處置，橫跨許多胸腔科的疾病，伴隨有許多種類的儀器主機和器械
- 3) 介入性支氣管鏡處置需要：
 - 事前規劃、
 - 選擇治療地點和生命支持方式、
 - 選擇治療方式，以及必要時，
 - 選擇氣道維持方式
- 4) 除了工作人員的熱枕以外，我們仍需友善的環境