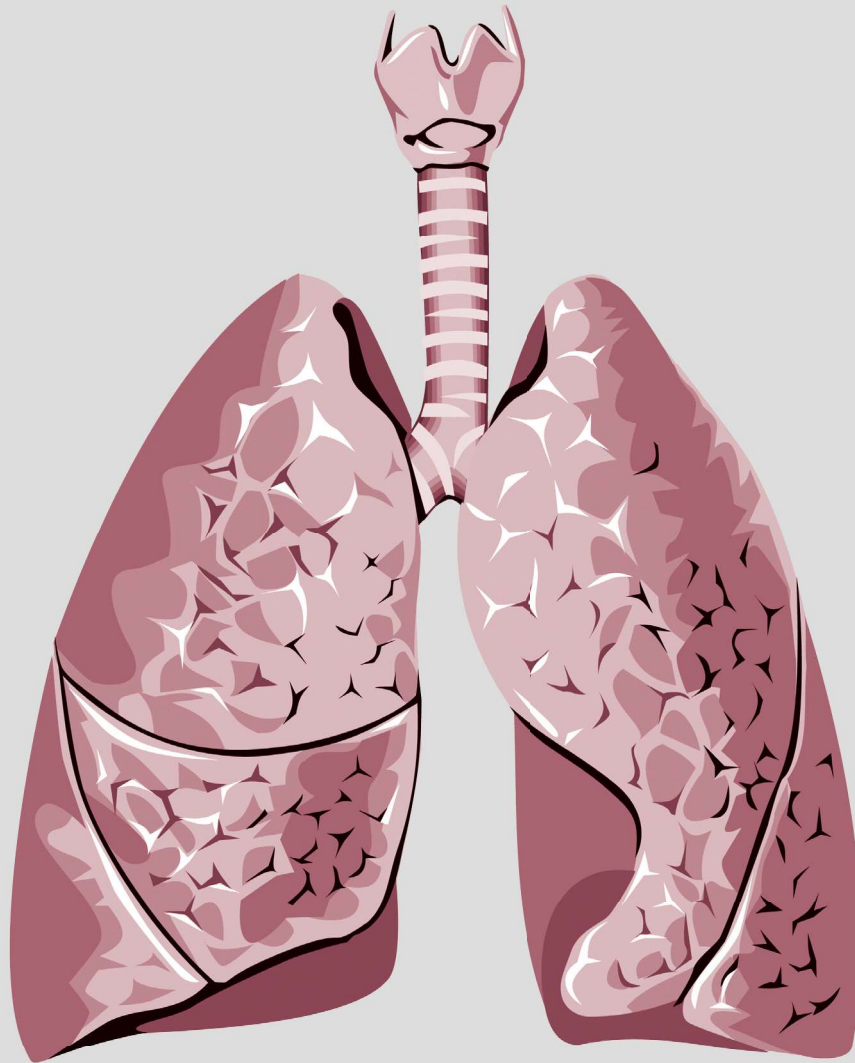


# Thoracic Medicine

Volume 38 • Number 2 • June 2023




The Official Journal of



Taiwan Society of  
Pulmonary and Critical  
Care Medicine



Taiwan Society of Sleep  
Medicine



Taiwan Society for  
Respiratory Therapy



Taiwan Society of  
Tuberculosis and Lung  
Diseases

# Thoracic Medicine

The Official Journal of  
Taiwan Society of Pulmonary and Critical Care Medicine  
Taiwan Society for Respiratory Therapy  
Taiwan Society of Sleep Medicine  
Taiwan Society of Tuberculosis and Lung Diseases

## Publisher

**Hao-Chien Wang, M.D., Ph.D., President**

*Taiwan Society of Pulmonary and Critical Care Medicine*

**Chia-Chen Chu, Ph.D., RRT, FAARC President**

*Taiwan Society for Respiratory Therapy*

**Yi-Wen Huang, M.D., President**

*Taiwan Society of Tuberculosis and Lung Diseases*

**Hsueh-Yu Li, M.D., President**

*Taiwan Society of Sleep Medicine*

## Editor-in-Chief

**Kang-Yun Lee, M.D., Ph.D., Professor**

*Taipei Medical University-Shuang Ho Hospital, Taiwan*

## Deputy Editors-in-Chief

**Shang-Gin Wu, M.D., Ph.D.**

*National Taiwan University Hospital, Taiwan*

## Editorial Board

### Section of Pulmonary and Critical Care Medicine

**Jin-Yuan Shih, M.D., Professor**  
*National Taiwan University Hospital, Taiwan*

**Gee-Chen Chang, M.D., Professor**  
*Chung Shan Medical University Hospital, Taiwan*

**Chung-Chi Huang, M.D., Professor**

*Linkou Chang Gung Memorial Hospital, Taiwan*

**Kuang-Yao Yang, M.D., Ph.D., Professor**

*Taipei Veterans General Hospital, Taiwan*

**Chi-Li Chung, M.D., Ph.D., Associate Professor**

*Taipei Medical University Hospital, Taiwan*

### Section of Respiratory Therapy

**Hue-Ling Lin, Ph.D. RRT, RN, FAARC, Professor**

*Chang Gung University, Taiwan*

**I-Chun Chuang, Ph.D., Assistant Professor**

*Kaohsiung Medical University College of Medicine, Taiwan*

**Jia-Jhen Lu, Ph.D., Professor**

*Fu Jen Catholic University, Taiwan*

**Shih-Hsing Yang, Ph.D., Associate Professor**

*Fu Jen Catholic University, Taiwan*

**Chin-Jung Liu, Ph.D., Associate Professor**

*China Medical University, Taiwan*

### Section of Tuberculosis and Lung Diseases

**Jann-Yuan Wang, M.D., Professor**

*National Taiwan University Hospital, Taiwan*

**Chen-Yuan Chiang, M.D.,**

**Associate Professor**  
*Taipei Municipal Wanfang Hospital, Taiwan*

**Ming-Chi Yu, M.D., Professor**

*Taipei Municipal Wanfang Hospital, Taiwan*

**Yi-Wen Huang, M.D., Professor**

*Changhua Hospital, Ministry of Health & Welfare, Taiwan*

**Wei-Juin Su, M.D., Professor**

*Taipei Veterans General Hospital, Taiwan*

### Section of Sleep Medicine

**Li-Ang Lee, M.D., Associate Professor**

*Linkou Chang Gung Memorial Hospital, Taiwan*

**Pei-Lin Lee, M.D., Assistant Professor**

*National Taiwan University Hospital, Taiwan*

**Hsin-Chien Lee, M.D., Associate Professor**

*Taipei Medical University-Shuang-Ho Hospital, Taiwan*

**Kun-Ta Chou, M.D., Associate Professor**

*Taipei Veterans General Hospital, Taiwan*

**Li-Pang Chuang, M.D., Assistant Professor**

*Linkou Chang Gung Memorial Hospital, Taiwan*

## International Editorial Board

**Charles L. Daley, M.D., Professor**

*National Jewish Health Center, Colorado, USA*

**Chi-Chiu Leung, MBBS, FFPH, FCCP, Professor**

*Stanley Ho Centre for Emerging Infectious Diseases, Hong Kong, China*

**Daniel D. Rowley, MSc,**

**RRT-ACCS, RRT-NPS, RPFT, FAARC**

*University of Virginia Medical Center, Charlottesville, Virginia, U.S.A.*

**Fang Han, M.D., Professor**

*Peking University People's Hospital Beijing, China*

**Huiqing Ge, Ph.D.**

*Sir Run Run Shaw Hospital, School of Medicine, Zhejiang University Hangzhou, China*

**J. Brady Scott, Ph.D., RRT-ACCS, AE-C, FAARC, FCCP, Associate Professor**

*Rush University, Chicago, Illinois, USA*

**Kazuhiro Ito, Ph.D., DVM, Honorary Professor**

*Imperial College London, UK*

**Kazuo Chin (HWA BOO JIN), M.D., Professor**

*Graduate School of Medicine, Kyoto University*

**Masaki Nakane, M.D., Ph.D., Professor**

*Yamagata University Hospital, Japan*

**Naricha Chirakalwasan, M.D., FAASM, FAPSR, Associate Professor**

*Faculty of Medicine, Chulalongkorn University, Thailand*

**Petros C. Karakousis, M.D., Professor**

*The Johns Hopkins University School of Medicine, USA*

# Thoracic Medicine

The Official Journal of  
Taiwan Society of Pulmonary and Critical Care Medicine  
Taiwan Society for Respiratory Therapy  
Taiwan Society of Sleep Medicine  
Taiwan Society of Tuberculosis and Lung Diseases

Volume **38**  
Number **2**  
June 2023

## CONTENTS

### Original Articles

- The role of Treatment or Incidental Pulmonary Tuberculosis Findings Post – Surgery in a Tuberculosis-Endemic Country** ..... 96~101  
Chien-Te Pan, Yu-Ting Tseng, Chung-Yu Chen, Pei-Ming Huang
- Pleura-contact Sign of Lung Nodules and Association with Benign Etiology in Asymptomatic Patients Without Cancer History** ..... 102~108  
Chun-Fu Chung, Yu-Cheng Tung, Sheng-Wei Tu, Kuo-Tung Huang, Hung-Chen Chen, Chien-Hao Lai, Meng Chih Lin, Yu-Ping Chang

### Case Reports

- Late-Onset Chylopericardium and Chylothorax after Thoracic Surgery** ..... 109~115  
Huei-Yang Hung, Yen-Lung Lee, Chih-Jen Yang
- Central Diabetes Insipidus as the First Manifestation of Pulmonary Langerhans Cell Histiocytosis – Report of 2 Cases** ..... 116~121  
Chung-Fu Lin, Sy-Harn Lian, Ye-Fong Du, Han-Yu Chang, Cheng-Lin Wu, Tang-Hsiu Huang
- Rare Cause of Pleural Effusion, Intestinal-type Mucinous Borderline Ovarian Tumor with Pseudo-Meigs' Syndrome: A Case Report** ..... 122~125  
Chuan-Chuan Wang, Jia-Hao Zhang
- Good's Syndrome With Opportunistic Infection – A Case Report and literature Review** ..... 126~131  
Chung Lee, Wen-Lin Su, Yao-Kuang Wu, Mei-Chen Yang, Lun-Yu Jao, Chou-Chin Lan, Yi-Chih Huang
- An Excavated Pulmonary Lesion in an Immunocompetent Young Man** ..... 132~135  
Chun-Yen Chen, Kuang-Tai Kuo, Wei-Hwa Lee, Wei-Ciao Wu
- Peribronchiolar Metaplasia - Interstitial Lung Disease: Case Report and Review of the Literature** ..... 136~141  
Chen-Chieh Lin, Mong-Wei Lin, Kuei-Pin Chung, Yih-Leong Chang
- A Rare Case of Lung Cancer With Initial Presentation of Symptomatic Choroidal Metastasis** ..... 142~148  
Chin-Shui Yeh, Jian-Sheng Wu
- Cavernous Sinus Metastasis of Lung Adenocarcinoma: A Case Report With A Literature Review** ..... 149~153  
Chien-Yeh Chi, Cheng-Chia Lee, Heng-sheng Chao
- Anti-Melanoma Differentiation-Associated gene 5 Antibody-Positive Dermatomyositis with Rapidly Progressive Interstitial Lung Disease Following SARS-CoV-2 Infection: – A Case Report** ..... 154~160  
Bing-Chen Wu, Shu-Min Lin
- A Case of Pseudoachalasia Secondary to Adenocarcinoma of the Lung** ..... 161~165  
Cheng-Hsi Yang, Yuan-Ming Tsai, Kuan-Hsun Lin, Tsai-Wang Huang, Hsu-Kai Huan
- Linezolid-Induced Discoloration of the Teeth and Tongue in Patients With Drug – Resistant Tuberculosis: A Report of Two Cases** ..... 166~172  
Pei-Ya Liao, Ko-Yun Chang, Ming-Feng Wu, Hui-Chen Chen, Wei-Chang Huang, Cha-Wen Lee, Shin-Shin Liu
- Pulmonary Vein Puncture During Port Implantation: A Rare and Abnormal Route** ..... 173~176  
Chun-Hao Wang, Pei-Hsing Chen

# The role of Treatment or Incidental Pulmonary Tuberculosis Findings Post-Surgery in a Tuberculosis-Endemic Country

Chien-Te Pan<sup>1</sup>, Yu-Ting Tseng<sup>1</sup>, Chung-Yu Chen<sup>2</sup>, Pei-Ming Huang<sup>1</sup>

**Introduction:** The indications for surgery are limited to the management of complicated forms of tuberculosis (TB), and mostly to cases in which medical treatment is failing. There is, however, limited good quality data on the effectiveness of using surgery alongside drug treatment for TB. This study investigated the prognosis of patients with an incidental pulmonary TB finding after surgical resection.

**Methods:** The study enrolled patients who received video-assisted thoracic surgery (VATS) wedge resection or lobectomy for lung lesions from 2013 to 2017. The Pulmonary TB diagnosis was based on pathological examination with acid-fast stain or the mycobacterial culture result of surgical specimens. Medical records were reviewed and clinical data, including age, gender, surgical type, pathological reports, microbiological cultures, treatment and follow-up duration were analyzed.

**Results:** A total of 443 patients from National Taiwan University Hospital Yunlin Branch, Yunlin County, Taiwan, were included. Of those, 200 patients (45.1%) had primary lung cancer, 31 (7.0%) had metastatic cancer, 20 (4.5%) were diagnosed as having mycobacterial infection, and 11 patients (2.5%) had cryptococcosis. Thirteen of the 20 patients (65.0%) with mycobacterial infection received anti-TB treatment, and the remaining 7 patients (35.0%) were followed at the clinic without a therapeutic medication prescription. All of these patients were stable after lung lesions resection without evidence of pulmonary TB recurrence.

**Conclusion:** Anti-TB treatment may not be essential after surgical resection with an incidental finding of pulmonary TB. There is a need for well-designed trials to provide more information about the effectiveness of surgery. (*Thorac Med* 2023; 38: 96-101)

Key words: surgery, lung tumor, pulmonary tuberculosis

---

<sup>1</sup>Department of Surgery, National Taiwan University Hospital Yunlin Branch, <sup>2</sup>Department of Internal Medicine, National Taiwan University Hospital Yunlin Branch  
Address reprint requests to: Dr. Yu-Ting Tseng, No.579, Sec.2, Yunlin Rd., Douliou City, Yunlin County, Taiwan

## Pleura-contact Sign of Lung Nodules and Association with Benign Etiology in Asymptomatic Patients Without Cancer History

Chun-Fu Chung<sup>1</sup>, Yu-Cheng Tung<sup>2</sup>, Sheng-Wei Tu<sup>1</sup>, Kuo-Tung Huang<sup>1</sup>, Hung-Chen Chen<sup>1</sup>, Chien-Hao Lai<sup>1</sup>, Meng Chih Lin<sup>1,3</sup>, Yu-Ping Chang<sup>1</sup>

**Introduction:** Pulmonary nodules are commonly observed in clinical practice. We aimed to analyze various features of pulmonary nodules and their association with the risk of malignancy.

**Methods:** We retrospectively reviewed patients with lung nodules equal to or less than 3cm in size, detected on chest computed tomography, and those who had received pulmonary nodules resection from January 2001 to December 2015. Ultimately, 302 resected pulmonary nodules from 258 patients were included in the study. Their characteristics and correlations with malignancy were analyzed.

**Results:** Pulmonary nodules with larger diameters were associated with higher risks of malignancy, were more irregular in shape, and had a higher percentage of solid nodules and pleural tag signs. Lung nodules measuring 1-2 cm had the highest percentage of pleura-contact signs (PCSs). Patients with larger pulmonary nodules had more symptoms and higher white blood cell counts. Among asymptomatic patients without known cancer histories, malignant pulmonary nodules tended to be large in diameter, irregular in shape, have a high percentage of pleura tag signs, have a low percentage of PCSs, and appear frequently in elderly patients. Multivariate analysis of factors associated with the malignancy risk of a pulmonary nodule in asymptomatic patients without a cancer history revealed that the patient's age and nodule diameter were significant positive predictors of cancer risk, while PCS was a negative predictor of malignancy.

**Conclusion:** For asymptomatic patients without a cancer history, PCSs may predict a benign nature in pulmonary nodules  $\leq 3$  cm in diameter. (*Thorac Med* 2023; 38: 102-108)

Key words: Pulmonary nodule, pleural-contact sign, malignancy risk, lung cancer

---

<sup>1</sup>Division of Pulmonary and Critical Care Medicine, Department of Internal Medicine, Kaohsiung Chang Gung Memorial Hospital and Chang Gung University College of Medicine, Kaohsiung, Taiwan, <sup>2</sup>Department of Diagnostic Radiology, Kaohsiung Chang Gung Memorial Hospital, Chang Gung University College of Medicine, Kaohsiung 83301, Taiwan, <sup>3</sup>Department of Respiratory Therapy, Kaohsiung Chang Gung Memorial Hospital and Chang Gung University College of Medicine, Kaohsiung, Taiwan

Address reprint requests to: Dr. Yu-Ping Chang, Division of Pulmonary and Critical Care Medicine, Department of Internal Medicine, Kaohsiung Chang Gung Memorial Hospital, Chang Gung University College of Medicine, Kaohsiung, Taiwan

## Late-Onset Chylopericardium and Chylothorax after Thoracic Surgery

Huei-Yang Hung<sup>1</sup>, Yen-Lung Lee<sup>2</sup>, Chih-Jen Yang<sup>1,3</sup>

Chylopericardium is defined as the accumulation of chylous fluid in the pericardial cavity that may progress to cardiac tamponade or constrictive pericarditis. Chylopericardium is very rare, but may occur after thoracic surgery. It can be caused by either direct injury to the branches of the thoracic duct, or indirect injury by occult obstruction of lymphatic drainage. Late-onset chylous fluid leakage can occur when thoracic surgery is combined with lymph node dissection. We reported the case of a patient with a late onset of coincident chylopericardium and chylothorax 1 month after undergoing video-assisted thoracic surgery for segmentectomy with mediastinal lymph node dissection to treat a pulmonary nodule. Both the chylopericardium and the chylothorax were completely resolved after the immediate surgical creation of a pericardial window and chest tube drainage, and the patient was recommended to follow a low-fat diet. This case reminds us of the rare but crucial complications associated with thoracic surgery. (*Thorac Med* 2023; 38: 109-115)

Key words: chylopericardium, chylothorax, thoracic surgery

---

<sup>1</sup>Division of Pulmonary and Critical Care Medicine, Department of Internal Medicine, Kaohsiung Medical University Hospital, Kaohsiung Medical University, Kaohsiung, Taiwan, <sup>2</sup>Department of Surgery, Kaohsiung Municipal Ta-Tung Hospital, Kaohsiung Medical University, Kaohsiung, Taiwan, <sup>3</sup>School of Post-Baccalaureate Medicine, College of Medicine, Kaohsiung Medical University, Kaohsiung, Taiwan

Address reprint requests to: Dr. Chih-Jen Yang, Department of Internal Medicine, Kaohsiung Medical University Hospital, Kaohsiung Medical University, No. 100, Tzyou First Road, Kaohsiung City, Taiwan

## Central Diabetes Insipidus as the First Manifestation of Pulmonary Langerhans Cell Histiocytosis – Report of 2 Cases

Chung-Fu Lin<sup>1</sup>, Sy-Harn Lian<sup>1</sup>, Ye-Fong Du<sup>1</sup>, Han-Yu Chang<sup>1</sup>, Cheng-Lin Wu<sup>2</sup>  
Tang-Hsiu Huang<sup>1</sup>

Langerhans cell histiocytosis (LCH) is a rare disease that is characterized by the recruitment and accumulation of abnormal histiocytes, and can involve multiple organs. LCH is more common in children than in adults, and adult-onset LCH is strongly associated with cigarette smoking. Pituitary involvement can cause central diabetes insipidus (CDI). In this report, we describe 2 patients with LCH who had a positive smoking history and presented initially with CDI-related polyuria and nocturia; their pulmonary disease was revealed only later by the typical radiographic features during the subsequent systematic workup. A concise and updated review of the relevant literature is also included. Through the report of these 2 cases, we aim to highlight the potentially systemic and progressively destructive nature of LCH, and the importance of monitoring for possible extra-pulmonary involvement, even in patients with prominent pulmonary LCH. (*Thorac Med* 2023; 38: 116-121)

Key words: central diabetes insipidus, pulmonary Langerhans cell histiocytosis

---

<sup>1</sup>Department of Internal Medicine, <sup>2</sup>Department of Pathology, National Cheng Kung University Hospital, College of Medicine, National Cheng Kung University, Tainan, Taiwan  
Address reprint requests to: Dr. Tang-Hsiu Huang, Division of Chest Medicine, Department of Internal Medicine, National Cheng Kung University Hospital, College of Medicine, National Cheng Kung University, No 138, Sheng-Li Road, Tainan 704, Taiwan

# Rare Cause of Pleural Effusion, Intestinal-type Mucinous Borderline Ovarian Tumor with Pseudo-Meigs' Syndrome: A Case Report

Chuan-Chuan Wang<sup>1</sup>, Jia-Hao Zhang<sup>1</sup>

Meigs' syndrome is characterized by pleural effusion and ascites associated with benign ovarian solid tumors such as fibroma, Brenner tumor, or granulosa cell tumor. However, pseudo-Meigs' syndrome is composed of ascites, pleural effusion, and ovarian tumors other than that described by Meigs. The incidence of pseudo-Meigs' syndrome is lower than that of Meigs' syndrome. We reported a 54-year-old woman who had progressive dyspnea and abdominal distension for 6 months. Image study revealed ascites, massive right side pleural effusion, and a huge multicystic ovarian mass (26 x 25 x 14cm in size). The patient had elevated carbohydrate antigen (CA)-125 (189.6 U/mL). The final pathologic report revealed an intestinal-type mucinous borderline ovarian tumor. Removal of the ovarian mass led to resolution of the pleural effusion and ascites. Mucinous borderline ovarian tumor rarely lead to pleural effusion, and pseudo-Meigs' syndrome is a rare differential diagnosis in an exudative pleural effusion. (*Thorac Med* 2023; 38: 122-125)

Key words: pseudo-Meigs' syndrome, intestinal-type mucinous borderline ovarian tumor

---

<sup>1</sup>Division of Pulmonary Medicine, Department of Internal Medicine, Far Eastern Memorial Hospital  
Address reprint requests to: Dr. Chuan-Chuan Wang, Division of Pulmonary Medicine, Department of Internal Medicine, Far Eastern Memorial Hospital, No.21, Sec. 2, Nanya S. Rd., Banciao Dist., New Taipei City 220, Taiwan (R.O.C.)



## An Excavated Pulmonary Lesion in an Immunocompetent Young Man

Chun-Yen Chen<sup>1</sup>, Kuang-Tai Kuo<sup>1,2</sup>, Wei-Hwa Lee<sup>3</sup>, Wei-Ciao Wu<sup>1</sup>

We reported the case of a 32-year-old male non-smoking white-collar worker who visited our hospital due to an abnormal chest radiograph found during a health check-up. He had no known disease and also denied a recent history of travel. Chest radiograph revealed an excavated lesion in the right upper lung field. Chest high-resolution computed tomography without contrast further confirmed the excavated lesion located at the superior segment of the right lower lobe, and also disclosed some small nodules, which were all less than 1 cm and scattered around the excavated lesion. Wedge resection of right lower lobe was done, and the pathological picture revealed cryptococcosis. Furthermore, tissue culture for fungus documented the presence of *Cryptococcus neoformans*. The patient was treated successfully with oral fluconazole. (*Thorac Med* 2023; 38: 132-135)

Key words: Cryptococcus neoformans, Immunocompetent, Excavate

---

<sup>1</sup>Division of Thoracic Surgery, Department of Surgery, Shuang Ho Hospital, Taipei Medical University, Taipei, Taiwan, <sup>2</sup>Division of Thoracic Surgery, Department of Surgery, School of Medicine, College of Medicine, Taipei Medical University, Taipei, Taiwan, <sup>3</sup>Department of Pathology, Shuang Ho Hospital, Taipei Medical University, Taipei, Taiwan.

Address reprint requests to: Dr. Wei-Ciao Wu, Division of Thoracic Surgery, Department of Surgery, Shuang Ho Hospital, Taipei Medical University, No.291, Zhongzheng Rd., Zhonghe District, New Taipei City 23561, Taiwan

## Good's Syndrome With Opportunistic Infection – A Case Report and Literature Review

Chung Lee<sup>1</sup>, Wen-Lin Su<sup>1,2</sup>, Yao-Kuang Wu<sup>1,2</sup>, Mei-Chen Yang<sup>1,2</sup>, Lun-Yu Jao<sup>1</sup>  
Chou-Chin Lan<sup>1,2\*</sup>, Yi-Chih Huang<sup>1,2\*</sup>

Good's syndrome (GS) is a rare condition in which thymoma is associated with hypogammaglobulinemia. It is characterized by autoimmunity and increased susceptibility to bacterial, viral, and fungal infections. Here, we presented the case of a patient with thymoma after thymectomy and hypogammaglobulinemia, diagnosed as GS. A 56-year-old Taiwanese woman had undergone thymectomy approximately 17 years previous to this admission. She also underwent retinal detachment surgery due to retinal cytomegalovirus (CMV) infection 7 years before this admission. In the years after her thymectomy, she developed *Pneumocystis jirovecii* pneumonia and CMV pneumonitis. The serum immunoglobulin levels were significantly low (IgG, 154 mg/dL; IgA, 24 mg/dL; IgM, < 20 mg/dL), suggesting that these infectious diseases were associated with GS. The patient received regular human immunoglobulin treatment without fatal infection. Increased awareness regarding the clinical and immunological profile of this syndrome may lead to early recognition and prevent mortality. (*Thorac Med* 2023; 38: 126-131)

Key words: Good's syndrome, thymoma, cytomegalovirus infection

---

<sup>1</sup>Division of Pulmonary Medicine, Taipei Tzu Chi Hospital, Buddhist Tzu Chi Medical Foundation, New Taipei City, Taiwan, <sup>2</sup>School of Medicine, Tzu-Chi University, Hualien, Taiwan, \*These authors contributed equally to this work. Address reprint requests to: Dr. Yi-Chih Huang, Division of Pulmonary Medicine, Taipei Tzu Chi Hospital, Buddhist Tzu Chi Medical Foundation, 289, Jianguo Road, Xindian City, New Taipei City 23142, Taiwan, Republic of China

## Peribronchiolar Metaplasia - Interstitial Lung Disease: Case Report and Review of the Literature

Chen-Chieh Lin<sup>1</sup>, Mong-Wei Lin<sup>2</sup>, Kuei-Pin Chung<sup>3,4</sup>, Yih-Leong Chang<sup>5,6</sup>

Peribronchiolar metaplasia (PBM) is a histological change that features the extension of bronchiolar-type epithelial cells along the alveolar walls adjacent to the bronchioles. The exact mechanisms leading to PBM are not well understood, and may be related to non-specific reactions to tissue injury. Peribronchiolar metaplasia – interstitial lung disease (PBM-ILD) is rarely reported in the literature, and is considered as a subtype of ILD with bronchiolocentric patterns. While focal PBM commonly appears in various chronic ILDs, diffuse PBM in the lungs is the principal pathological hallmark of PBM-ILD. Here, we reported a case of PBM-ILD that may have been caused by long-term incense smoke exposure. Our report indicates that surgical biopsy is crucial for diagnosis of ILD with unusual clinical and radiological presentation. (*Thorac Med* 2023; 38: 136-141)

Key words: interstitial lung disease, peribronchiolar metaplasia, bronchiolocentric pattern, incense smoke exposure

---

<sup>1</sup>Department of Internal Medicine, National Taiwan University Hospital, Taipei, Taiwan, <sup>2</sup>Department of Surgery, National Taiwan University Hospital, Taipei, Taiwan, <sup>3</sup>Department of Laboratory Medicine, National Taiwan University Hospital, Taipei, Taiwan, <sup>4</sup>Department of Laboratory Medicine, National Taiwan University College of Medicine, Taipei, Taiwan, <sup>5</sup>Department of Pathology, National Taiwan University Hospital and National Taiwan University Cancer Center, Taipei, Taiwan, <sup>6</sup>Department and Graduate Institute of Pathology, College of Medicine, National Taiwan University, Taipei, Taiwan.

Address reprint requests to: Dr. Kuei-Pin Chung, Department of Laboratory Medicine, National Taiwan University Hospital and National Taiwan University College of Medicine, No. 7, Chung Shan S. Rd., Zhongzheng Dist., Taipei 100, Taiwan

## A Rare Case of Lung Cancer With Initial Presentation of Symptomatic Choroidal Metastasis

Chin-Shui Yeh<sup>1,3</sup>, Jian-Sheng Wu<sup>2,3</sup>

Symptomatic choroidal metastasis is a rare presenting manifestation of lung cancer. We reported the case of a 57-year-old woman who was a non-smoker throughout her life, and who had initially presented with blurred vision in her left eye. The ophthalmologist referred her to the chest medicine department for testing for occult primary lung malignancy. Pathologic diagnosis of the computed tomography-guided fine needle aspiration from the left lower lobe lung mass was adenocarcinoma. The final diagnosis was adenocarcinoma of the lung, with metastases to the choroid, liver, left adrenal gland, and multiple bones. Clinical staging was T2bN3M1c, stage IVB. She received radiation therapy to the posterior pole of the left eye. However, her visual acuity decreased to 20/200, and progression of retinal detachment at the macula was noted. A subtenon triamcinolone acetonide injection was administered monthly, and the retinal detachment subsided with visual acuity improving to 20/25 3 months later. Genetic analysis of the tumor cells revealed a mutation in epidermal growth factor receptor exon 19. She received an oral tyrosine kinase inhibitor, dacomtinib, as first-line therapy with a good response, and tumor regression was observed. Choroidal metastasis is relatively uncommon but should be suspected in lung cancer patients with deteriorated visual acuity. (*Thorac Med* 2023; 38: 142-148)

Key words: lung cancer, adenocarcinoma, choroidal metastasis

---

<sup>1</sup>Division of Chest Medicine, Department of Internal Medicine, Changhua Christian Hospital Changhua, Taiwan, <sup>2</sup>Department of Ophthalmology, Changhua Christian Hospital, <sup>3</sup>Department of Post-Baccalaureate Medicine, National Chung Hsing University.

Address reprint requests to: Dr. Chin-Shui Yeh, Division of Chest Medicine, Changhua Christian Hospital, 135 Nanxiao St, Changhua, Taiwan

## Cavernous Sinus Metastasis of Lung Adenocarcinoma: A Case Report With A Literature Review

Chien-Yeh Chi<sup>1</sup>, Cheng-Chia Lee<sup>2</sup>, Heng-sheng Chao<sup>1</sup>

Cavernous sinus metastasis is rare. Its symptoms vary widely, and it is commonly confused with pituitary gland adenoma due to the lack of clear radiological criteria differentiating the 2 conditions. We present the case of a 54-year-old woman who had been diagnosed with non-small cell carcinoma of the right upper lung, with brain, bone, and lung-to-lung metastases. She presented intermittent dizziness, headache, vertigo, right eye ptosis, blurred vision, and diplopia during regular follow-up. Contrast brain magnetic resonance imaging revealed a mixed-intensity nodular lesion measuring 1.4 x 1 cm in the pituitary gland with a deviation of the pituitary stalk from right to left. Due to suspicion of a new metastatic lesion on the right side of the pituitary gland, the patient underwent an endoscopic trans-sphenoidal excision for removal of the pituitary tumor. Repeated brain computed tomography showed postoperative change and no residual pituitary tumor. This case report is a reminder that physicians should be aware of pituitary and cavernous sinus metastasis with its diverse clinical manifestations. And we should keep in mind that it is important to trace along the cranial nerve path if symptoms and signs of manifestations of the cranial nerve develop. (*Thorac Med* 2023; 38: 149-153)

Key words: Cavernous sinus metastasis, lung adenocarcinoma

---

<sup>1</sup>Department of Chest Medicine, Taipei Veterans General Hospital, Taipei, Taiwan, <sup>2</sup>Department of Neurosurgery, Neurological Institute, Taipei Veterans General Hospital, Taipei, Taiwan.

Address reprint requests to: Dr. Heng-sheng Chao, Division of General Chest Medicine, Department of Chest Medicine, Taipei Veterans General Hospital, Taipei, Taiwan, No. 201, Sec. 2, Shih-Pai Rd., Beitou District, Taipei 11217, Taiwan, ROC

## Anti-Melanoma Differentiation-Associated gene 5 Antibody-Positive Dermatomyositis With Rapidly Progressive Interstitial Lung Disease Following SARS-CoV-2 Infection: a Case Report

Bing-Chen Wu<sup>1,2</sup>, Shu-Min Lin<sup>1,2</sup>

Anti-melanoma differentiation-associated gene 5 (MDA5) antibody-positive dermatomyositis (DM) is an uncommon autoimmune disorder, particularly clinically amyopathic dermatomyositis, and has a high risk of causing severe rapidly progressive interstitial lung disease (RP-ILD), with poor survival rates. It is hypothesized that SARS-CoV-2 infections may trigger autoimmune diseases, such as DM. We described a patient who was newly diagnosed with anti-MDA5 DM after SARS-CoV-2 infection. (*Thorac Med* 2023; 38: 154-160)

Key words: Anti-MDA5 antibody-positive dermatomyositis, SARS-CoV-2 infection, rapidly progressive interstitial lung disease

---

<sup>1</sup>Department of Thoracic Medicine, Chang Gung Memorial Hospital, No.5, Fuxing St., Guishan Dist., Taoyuan County 333, Taiwan (R.O.C.), <sup>2</sup>School of Medicine, Chang Gung University, No.259, Wen-Hwa 1st Road, Guishan Dist., Taoyuan County 333, Taiwan (R.O.C.).

Address reprint requests to: Dr. Shu-Min Lin, 1Department of Thoracic Medicine, Chang Gung Memorial Hospital, No.5, Fuxing St., Guishan Dist., Taoyuan County 333, Taiwan (R.O.C.)

## A Case of Pseudoachalasia Secondary to Adenocarcinoma of the Lung

Cheng-Hsi Yang<sup>1</sup>, Yuan-Ming Tsai<sup>1</sup>, Kuan-Hsun Lin<sup>1</sup>, Tsai-Wang Huang<sup>1</sup>  
Hsu-Kai Huang<sup>1,2</sup>

Achalasia is a rare disease, with an annual incidence of approximately 1.6 cases per 100,000 individuals and a prevalence of 10 cases per 100,000 individuals. Achalasia is usually diagnosed in patients between the ages of 25 and 60 years. The onset of symptoms, including dysphagia and body weight loss, is usually progressive. Differential diagnosis between idiopathic achalasia and pseudoachalasia is important. Due to the rarity and clinical similarity of these 2 conditions, these patients may be misdiagnosed and receive relatively ineffective treatment. Here we present the case of a patient who was diagnosed initially as having achalasia by esophageal manometric examination, but was eventually found to have adenocarcinoma of the lung. Relevant literature is also reviewed. (*Thorac Med* 2023; 38: 161-165)

Key words: Pseudoachalasia; lung cancer

---

<sup>1</sup>Division of Thoracic Surgery, Department of Surgery, Tri-service General Hospital, National Defense Medical Center, Taipei, Taiwan, ROC, <sup>2</sup>Penghu Branch, Tri-service General Hospital, National Defense Medical Center, Taipei, Taiwan, ROC.

Address reprint requests to: Dr. Hsu-Kai Huang, Penghu Branch, Tri-service General Hospital, National Defense Medical Center, Taipei, Taiwan, ROC

## Linezolid-Induced Discoloration of the Teeth and Tongue in Patients With Drug-Resistant Tuberculosis: A Report of Two Cases

Pei-Ya Liao<sup>1</sup>, Ko-Yun Chang<sup>1</sup>, Ming-Feng Wu<sup>1,2</sup>, Hui-Chen Chen<sup>1</sup>  
Wei-Chang Huang<sup>1,3</sup>, Cha-Wen Lee<sup>4\*</sup>, Shin-Shin Liu<sup>5\*</sup>

The purpose of this report was to describe the cases and different pathophysiology of two patients with drug-resistant tuberculosis (TB) who experienced the embarrassing side effects of oral discoloration after using linezolid. One patient had pre-extensively drug-resistant TB (pre-XDR TB), and the other had multidrug-resistant TB (MDR-TB). The former received a bedaquiline-pretomanid-linezolid (BPaL) regimen, and the latter was treated with moxifloxacin, bedaquiline, linezolid and cycloserine. The first patient developed discoloration of her tongue around one and a half months after treatment with the BPaL regimen, while the other patient developed discoloration of her teeth following one month of treatment with the linezolid-containing regimen, with linezolid being considered the culprit causing these anomalies. We referred the patients to a dentist, who excluded other possible etiologies (such as poor oral hygiene), and cleaned their oral cavities. This substantially improved the black hairy tongue and tooth pigmentation despite the continued use of linezolid-containing regimens. To determine whether linezolid is the offending agent, other predisposing conditions should be excluded and the culprit drugs discontinued. However, considering that linezolid plays an important role in the treatment of drug-resistant TB in international guidelines, continued use of linezolid and early referral to a dentist for multidisciplinary combined care are warranted. (*Thorac Med* 2023; 38: 166-172)

Key words: Black hairy tongue; tooth discoloration; drug-resistant tuberculosis; linezolid

---

<sup>1</sup>Division of Chest Medicine, Department of Internal Medicine, Taichung Veterans General Hospital, Taichung, Taiwan, <sup>2</sup>Department of Medical Laboratory Science and Biotechnology, Central Taiwan University of Science and Technology, Taichung, Taiwan, <sup>3</sup>Department of Post-Baccalaureate Medicine, College of Medicine, National Chung Hsing University, Taichung, Taiwan, <sup>4</sup>Department of Internal Medicine, Taichung Veterans General Hospital, Taichung, Taiwan, <sup>5</sup>Nursing Department, Taichung Veterans General Hospital, Taichung, Taiwan, \*These authors contributed equally to this work.

Address reprint requests to: Dr. Pei-Ya Liao, Division of Chest Medicine, Department of Internal Medicine, Taichung Veterans General Hospital, 1650 Taiwan Boulevard Sect. 4, Taichung, Taiwan 40705



## Pulmonary Vein Puncture During Port Implantation: A Rare and Abnormal Route

Chun-Hao Wang<sup>1</sup>, Pei-Hsing Chen<sup>2</sup>

This study presents the case of a 56-year-old woman with breast cancer who underwent implanted catheter surgery via the left subclavian vein, under general anesthesia. However, chest radiography revealed the implantation had taken an abnormal route -- the catheter had punctured the pulmonary vein. The implanted catheter was removed and no irreversible complication developed. Most complications related to venepuncture and catheterization have involved the subclavian artery, great artery, or pulmonary artery. Seldom has a case occurred at the left heart level, especially the pulmonary vein. During treatment, physicians should be aware of the risk of a complication, which may lead to a life-threatening event such as pulmonary embolism, stroke, or air-related myocardial infarction. In conclusion, puncture of the pulmonary vein during port implantation is a rare condition with limited treatment suggestions. The successful conservative treatment provided in this case was without long-term impairment, and can be applied in future cases. In all cases, however, the patient needs close observation and monitoring, and the surgical intervention team should always be prepared to provide hemostasis. (*Thorac Med* 2023; 38: 173-176)

Key words: pulmonary vein puncture, iatrogenic-related injury

---

<sup>1</sup>National Taiwan University College of Medicine, <sup>2</sup>Division of Thoracic Surgery, Department of Surgery, National Taiwan University Hospital Yun-Lin Branch

Address reprint requests to: Dr. Pei-Hsing Chen, Division of Thoracic Surgery, Department of Surgery, National Taiwan University Hospital Yun-Lin Branch, No. 579, Sec. 2, Yunlin Rd., Douliu City, Yunlin County 640, Taiwan