

2022 胸部影像判讀繼續教育課程



胸壁、肋膜、縱膈腔病變

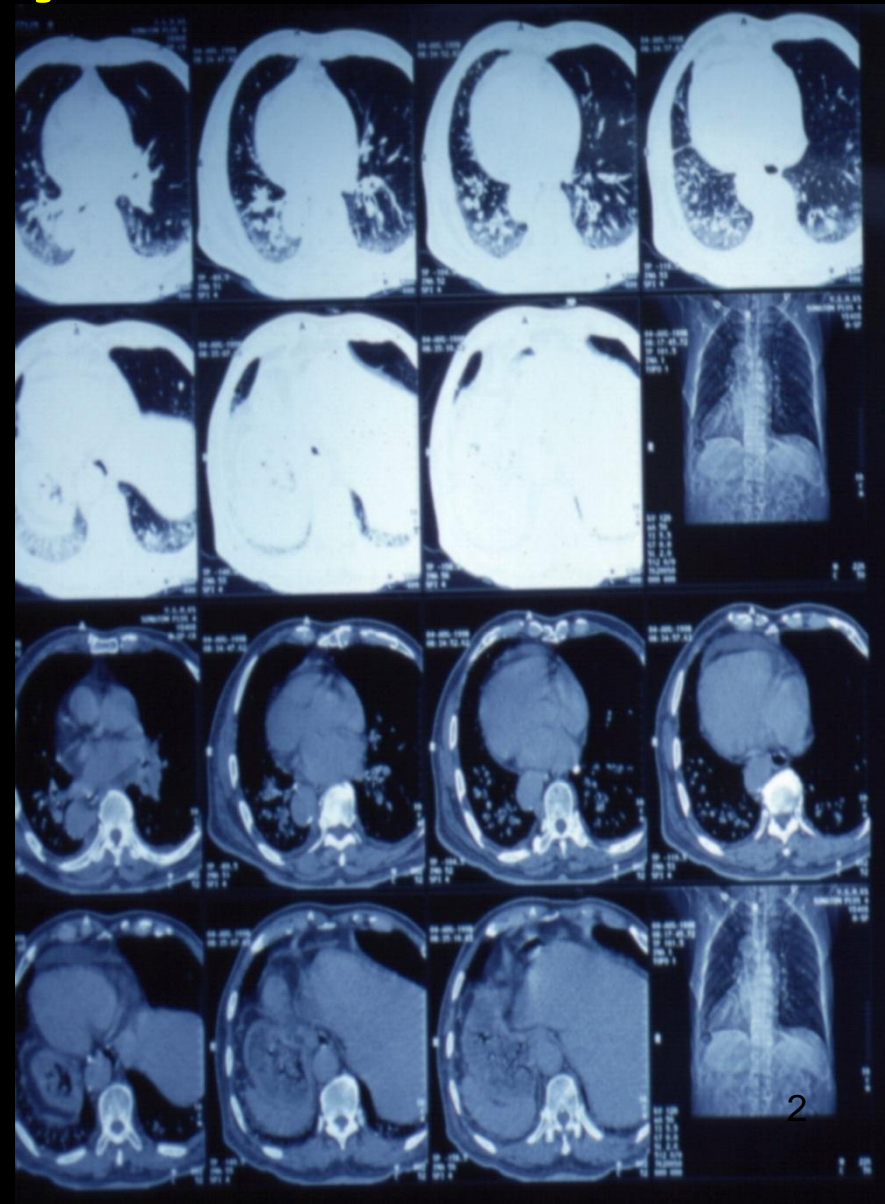
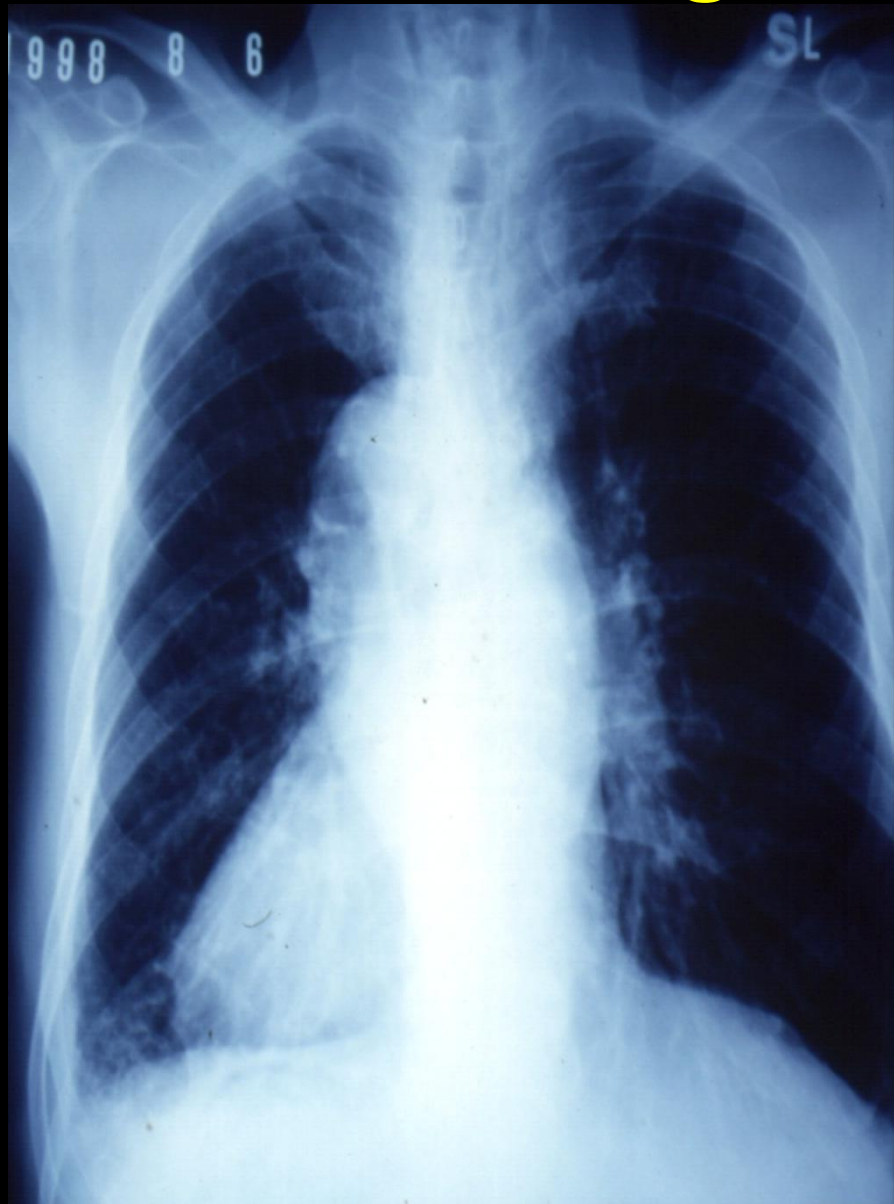
高雄榮總 胸腔內科

許淳翔醫師

August 7, 2022

高雄榮民總醫院

看片以前：位子正确否？ Katagener syndrome

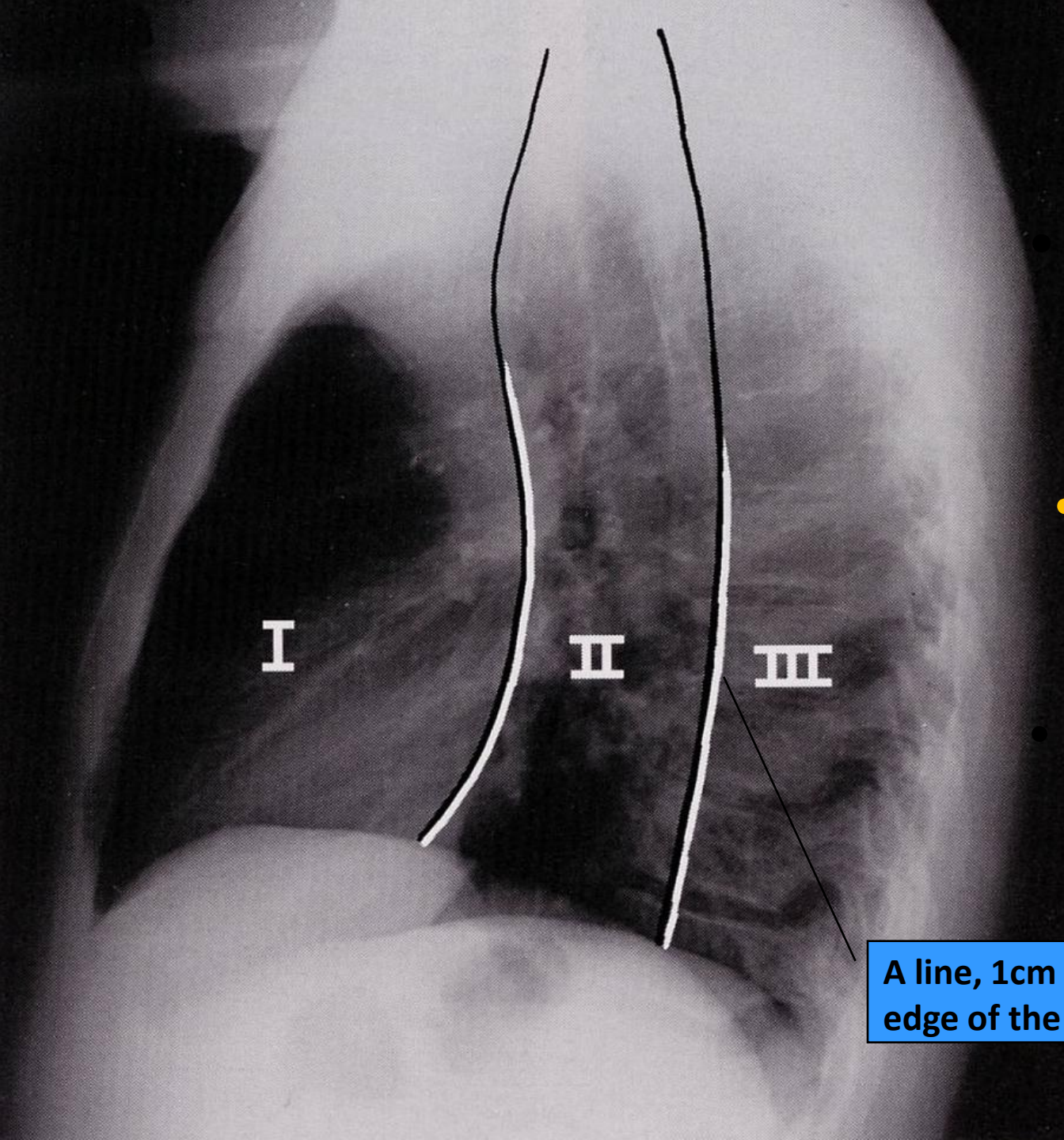


Mediastinal Lesions

位置（前、中、後）

類型（位移、變寬、腫塊、氣體）

緊急與否

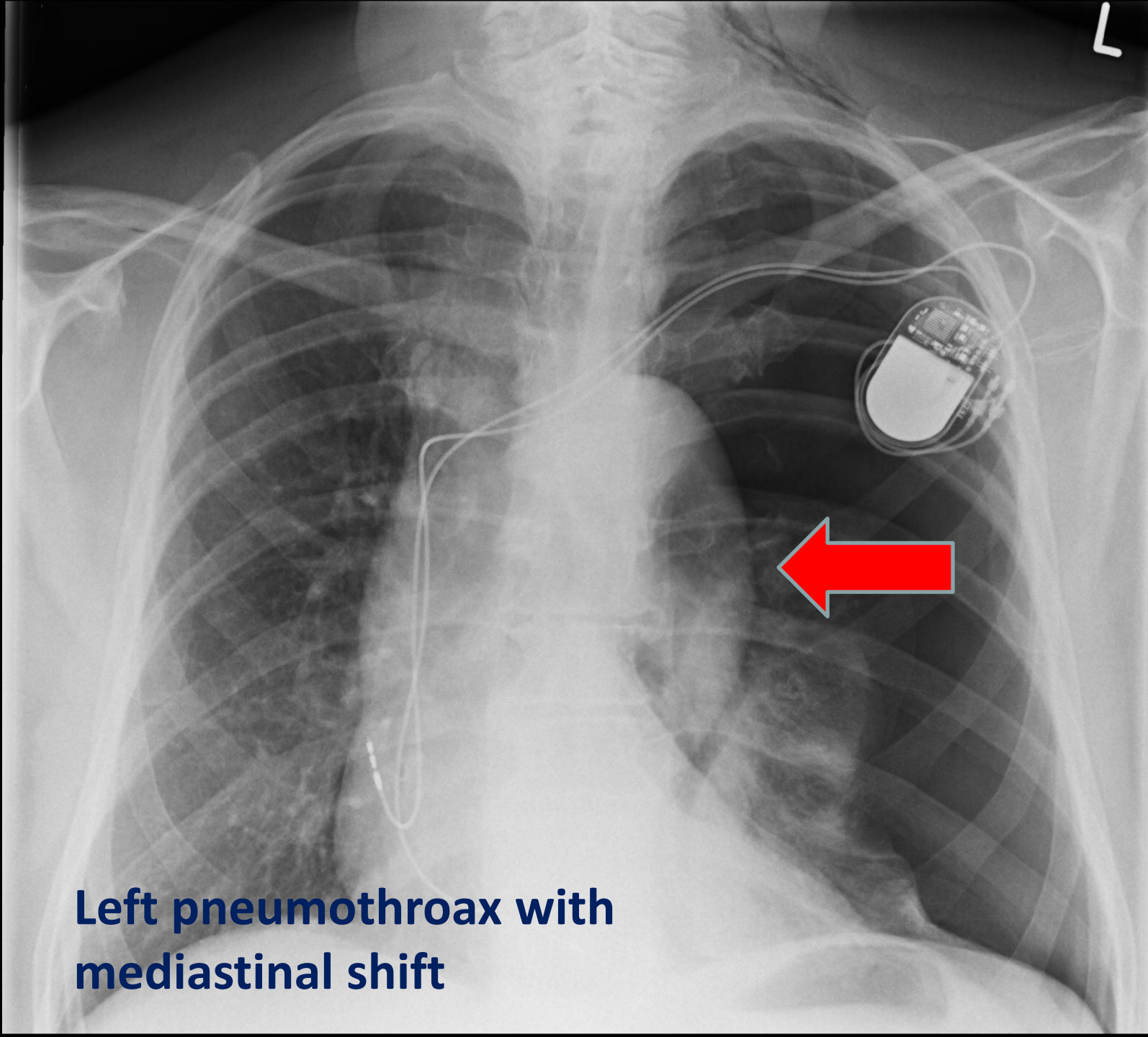


• 位置（前、中、後）

A line, 1cm back from the anterior edge of the vertebral bodies

List of Mediastinum Lesions (類型)

- Shift (位移): 推、拉; 水、腫塊
- Widening (變寬)
 - Aortic aneurysm / dissection
 - Mediastinitis (\pm air-fluid level)
 - Lipomatosis
- Soft tissue density (腫塊)
 - Mass, Neoplasm
- Air or air-fluid level (氣體)
 - Pneumomediastinum
 - 食道:
 - Esophagus reconstruction
 - Achalasia
 - Hiatal hernia

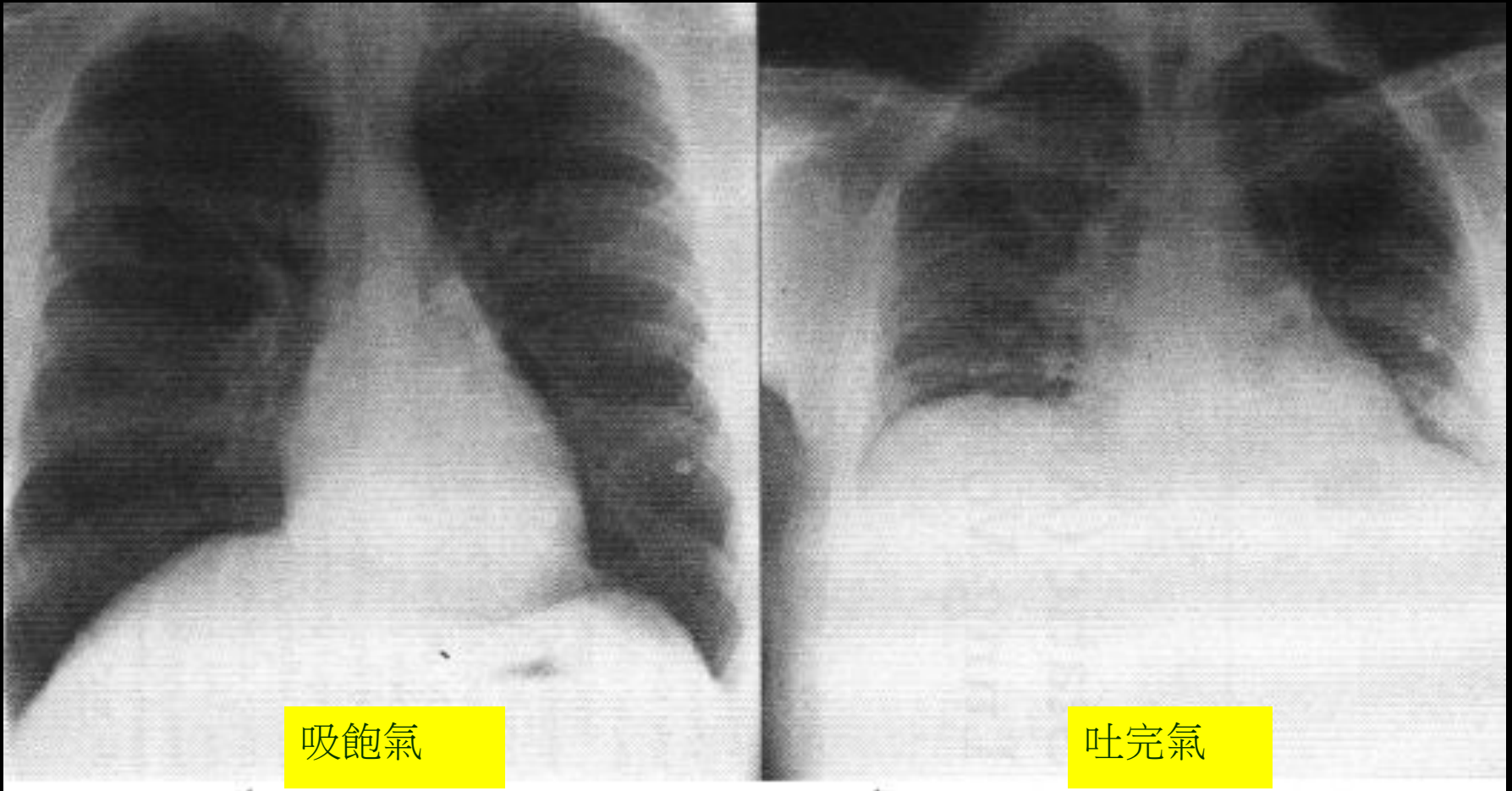


**Left pneumothorax with
mediastinal shift**

Mediastinal Widening

- First, exclude below conditions (排除)
 - Supine AP film
 - Lordotic film
 - Inadequate inspiration

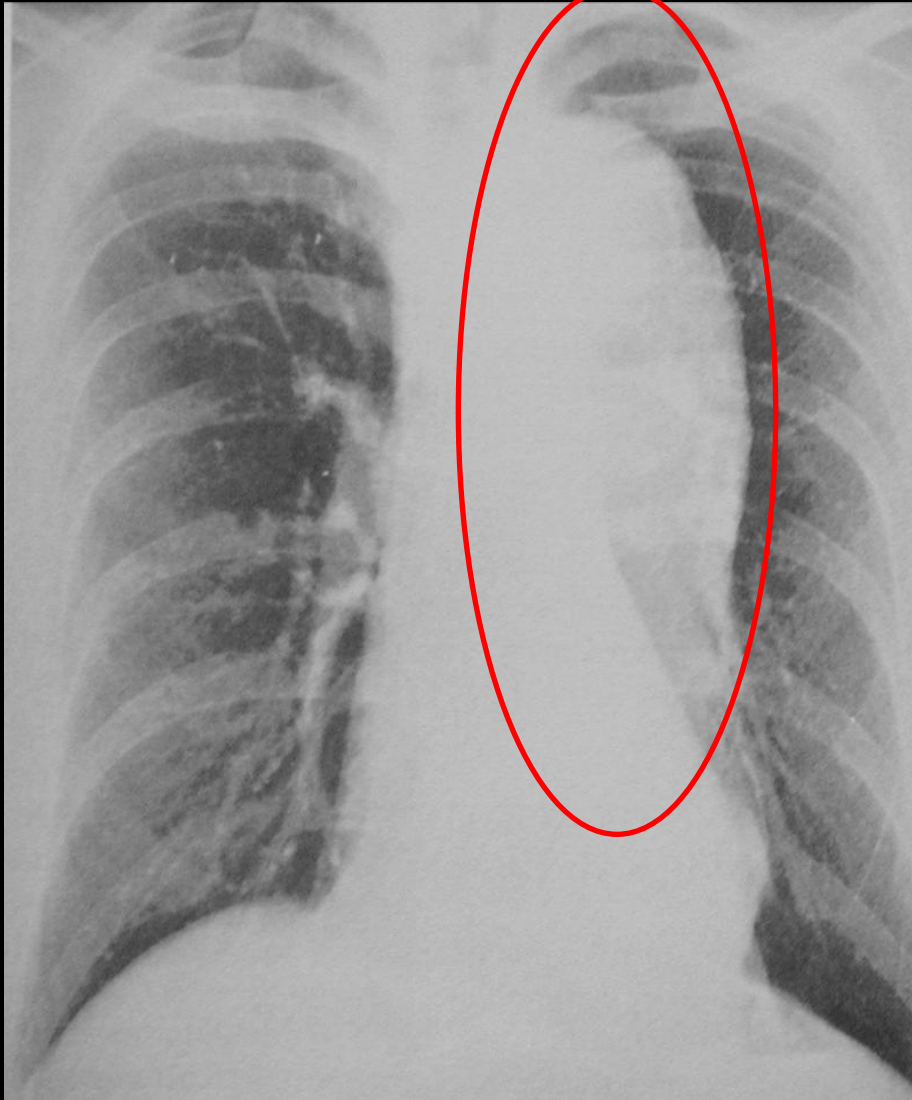
CXR – Full inspiration, Expiration



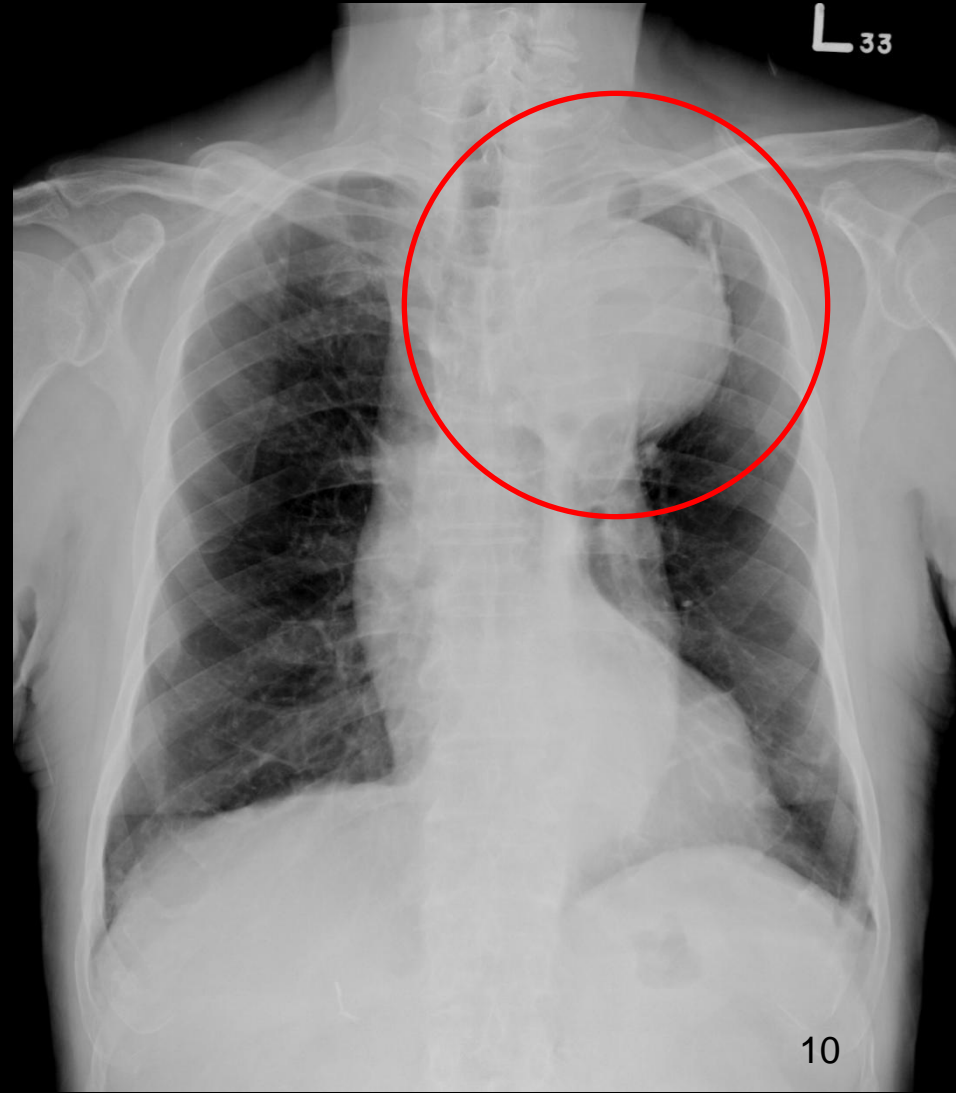
(*危險) Mediastinal Widening

- Hemodynamic (Vascular): 血管
 - Tortuous aorta, aortic aneurysm, aortic dissection
 - Hematoma: trauma, post-operation, catheters
- Mediastinitis : 發炎
 - Acute mediastinitis
 - Fibrosing mediastinitis
- Neoplasm / Mass : 腫塊
 - Lymphoma, Lung Ca, LAP
- Lipomatosis (脂肪)
 - Steroid use, Cushing' s syndrome, obesity

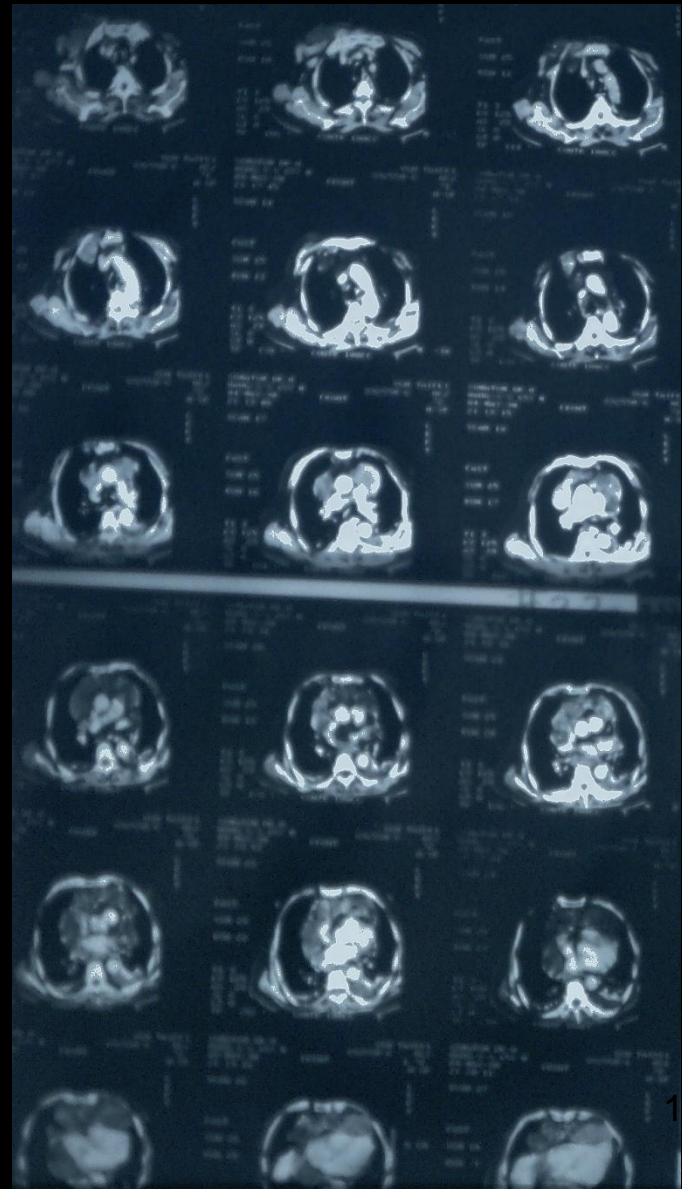
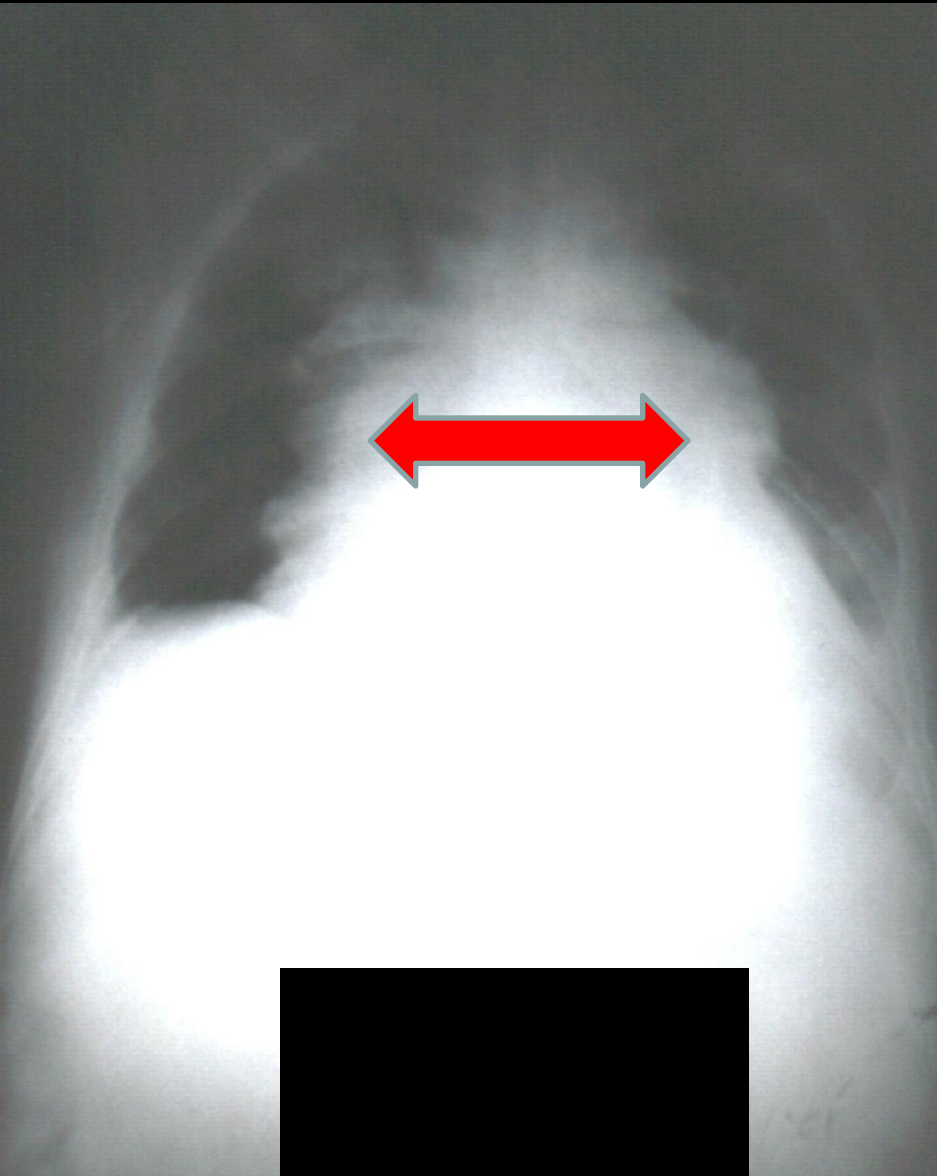
Aortic Dissection



Aortic Aneurysm



Acute Mediastinitis (fever, chest pain)



Acute Mediastinitis

■ Causes

- Esophageal perforation: the most common cause (*Boerhaave's syndrome, TE fistula*)
- Esophageal/cardiac surgery
- Direct extension of infection from adjacent structures (e.g. retropharyngeal abscess)
- Hematogenous spread of infection

■ CXR

- **Widening** of mediastinum, typically with blurred ill-defined mediastinal margin
- **Pneumomediastinum** may be evident

■ Diagnosis

- By extravasation of ingested contrast into the mediastinum or pleural space

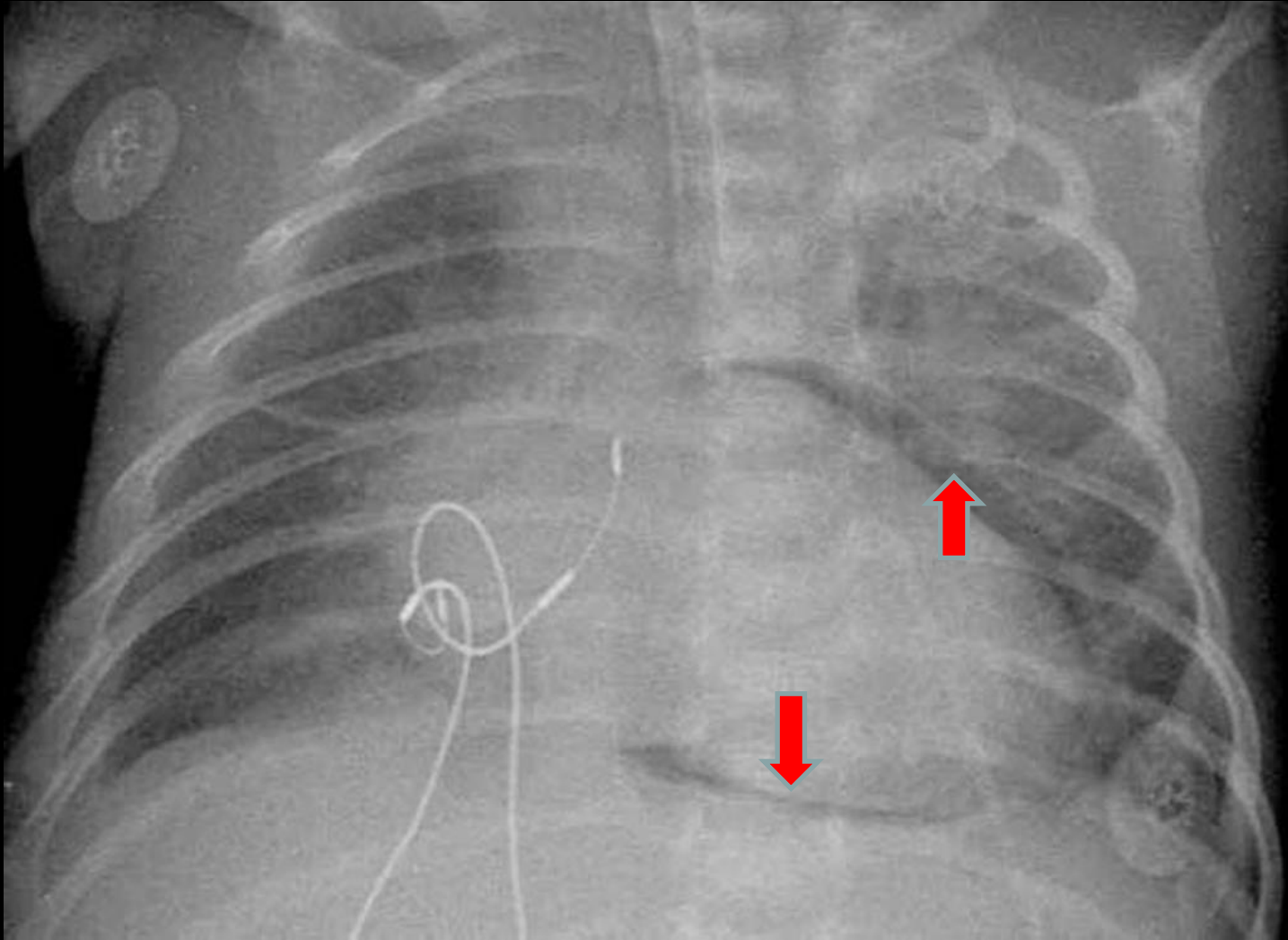
Mediastinal Mass

- Tapered border
- Center within mediastinum: 圓心落在縱膈腔內
- Sharp margin
- Bilaterality: 病灶跨在左右兩側的胸腔

Pneumomediastinum

- Gas within the mediastinum can result from 5 sites:
 - Lung (most common), mediastinal airway, neck, esophagus, and abdominal cavity.
- CXR:
 - **Subcutaneous emphysema.**
 - Lucent streaks of gas outlining mediastinum
 - **Continuous diaphragm sign:** permits identify central portion of diaphragm.

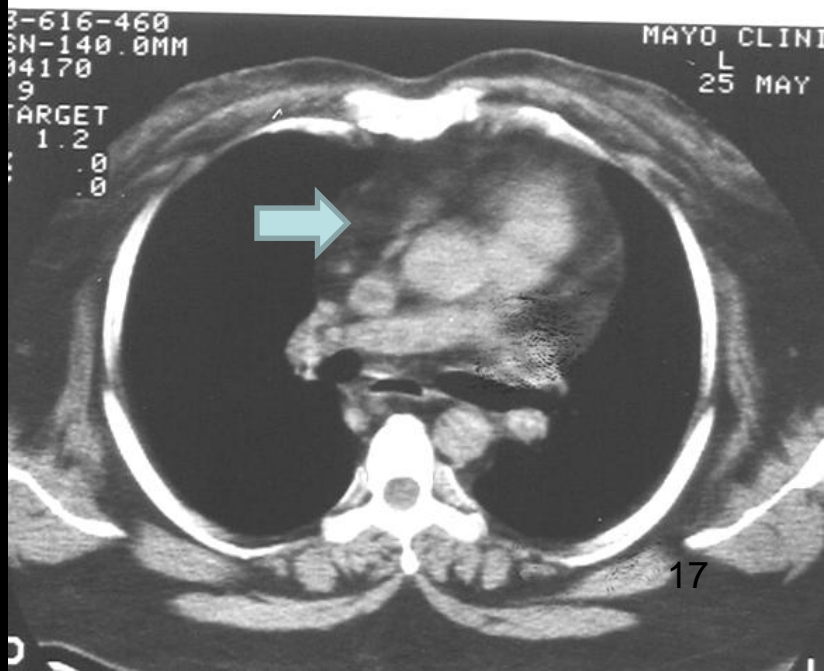
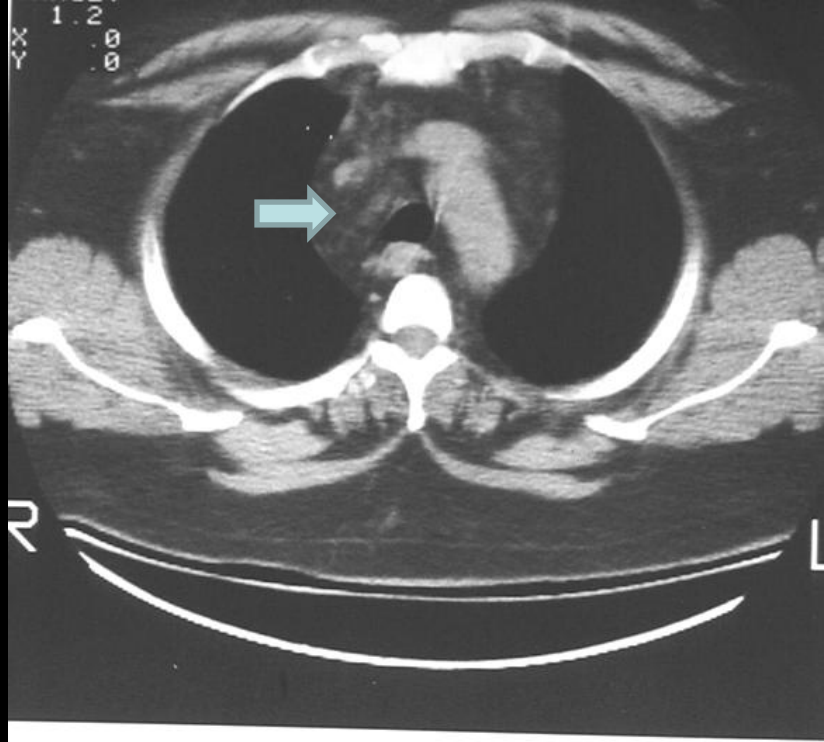
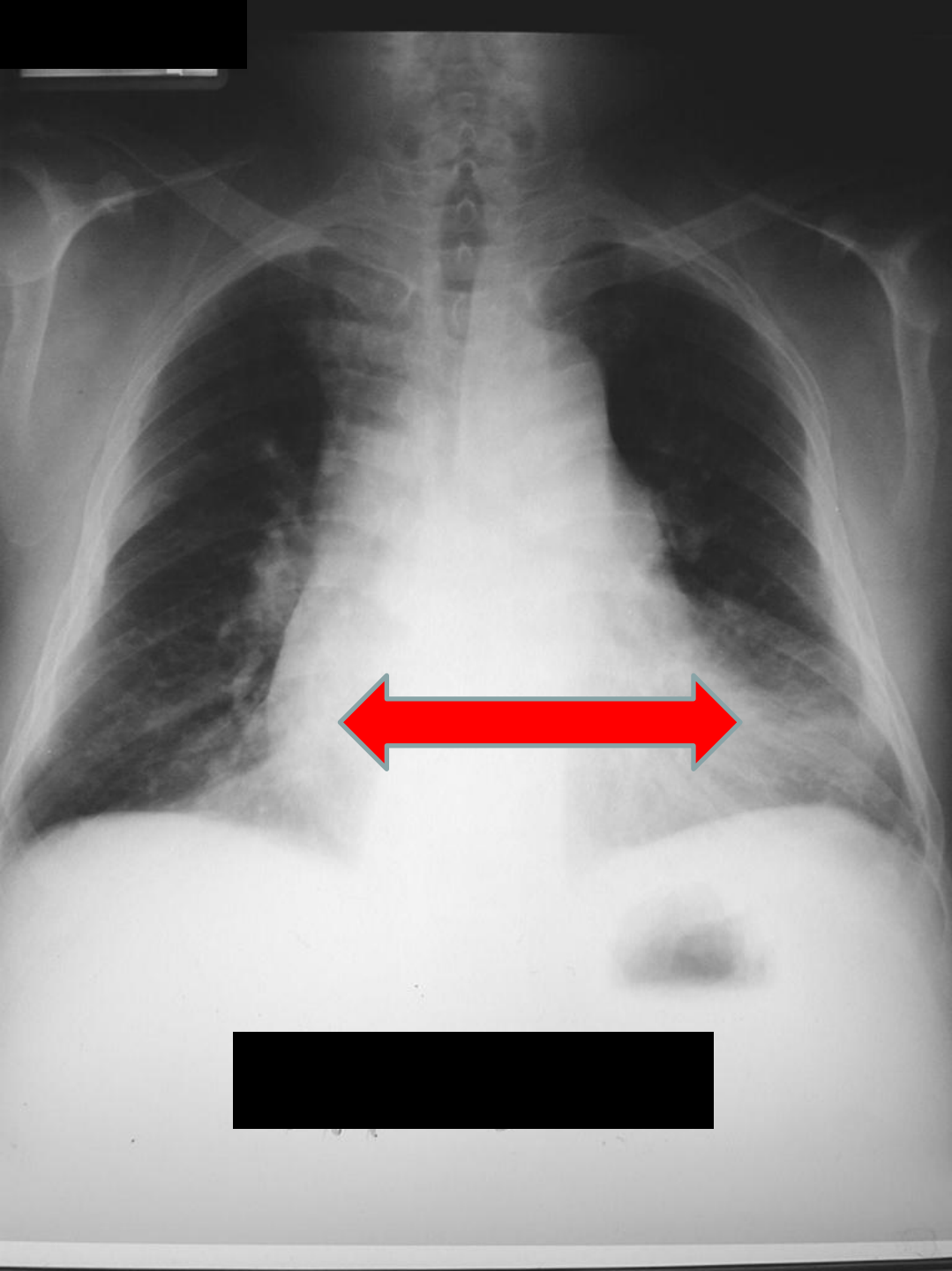
Pneumopericardium



Lipomatosis (CT scan)

■ CXR

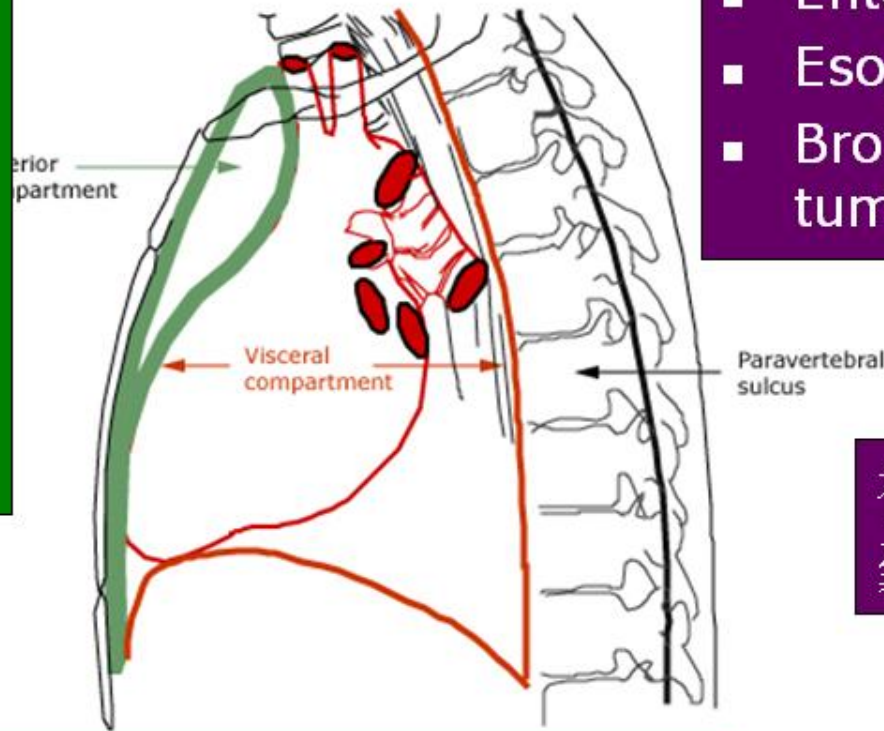
- Smooth and symmetric mediastinal widening
- Margins can be lobulated if large, but no indentation on the trachea
- Location:
 - Superior mediastinum is most frequent location:
 - From the thoracic inlet to the hila bilaterally
 - Lateral displacement of anterior pleural reflection
 - Prominent epicardial +/- pericardial fat pad



前縱膈腔

- Intrathoracic Goiter
- Parathyroid tumor
- Esophageal tumor
- Angiomatous tumor
- Teratoma
- Thymoma
- Pericardial cyst
- Terrible Lymphoma
- Morgagni hernia
- Lipoma

← 4 T



後縱膈腔

- Neurogenic tumor
- Aneurysm
- Enteric cyst
- Esophageal tumor
- Bronchogenic tumor



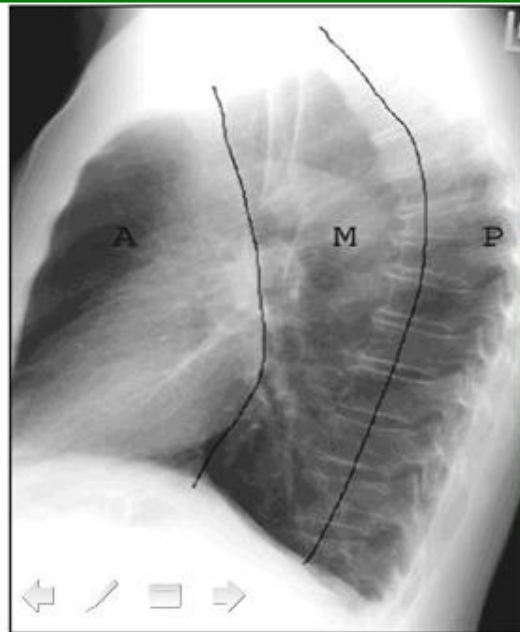
神經性腫瘤
囊腫, 動脈瘤

中縱膈腔

- Lymphoma
- Lymph node hyperplasia
- Bronchogenic tumor
- Bronchogenic cyst



淋巴疾病及
縱膈囊腫

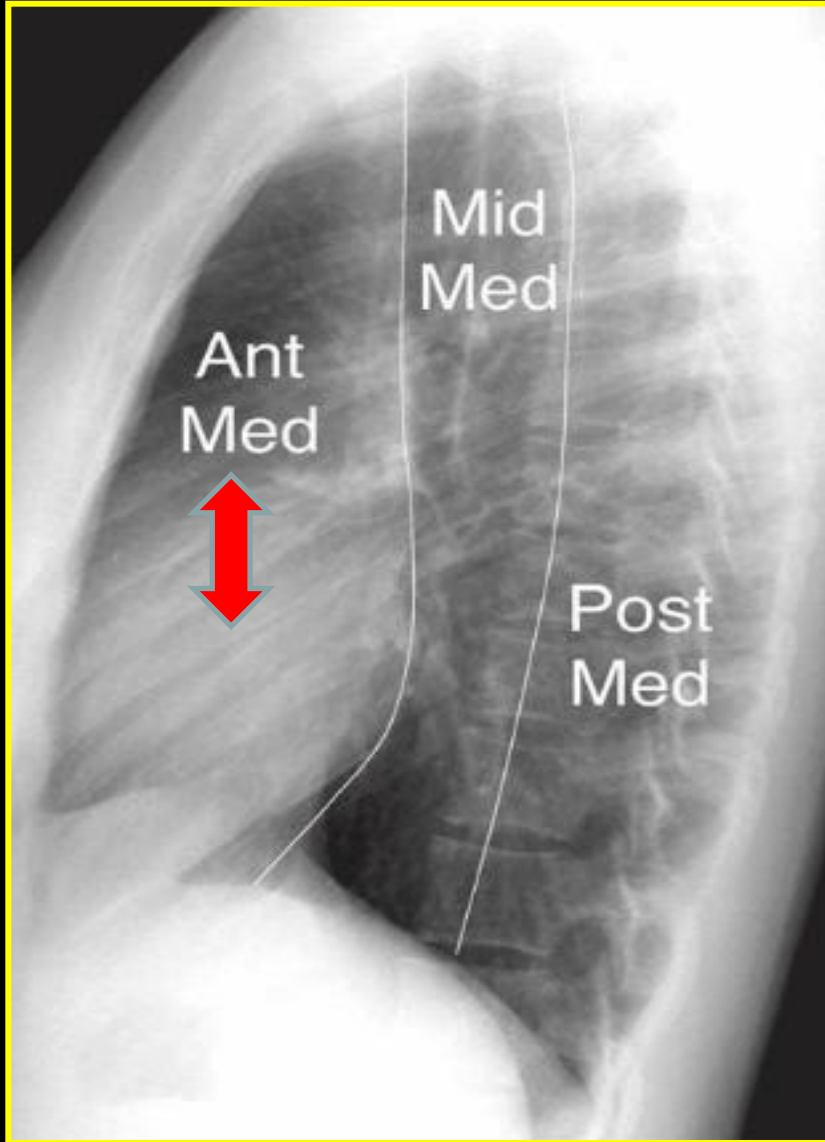


Mediastinum Mass (腫塊)

Distribution of lesions(n=400)

	Anterior	Middle	Posterior
Thymic lesions	30%	0%	0%
Lymphomas	20%	21%	20%
Germ cell tumors	18%	0%	0%
Carcinoma	13%	7%	0%
Cysts	7%	60%	34%
Mesenchymal tumors	5%	9%	9%
Endocrine tumors	5%	0%	0%
Neurogenic tumors	0%	0%	53%
Miscellaneous	2%	3%	2%

Anterior mediastinum



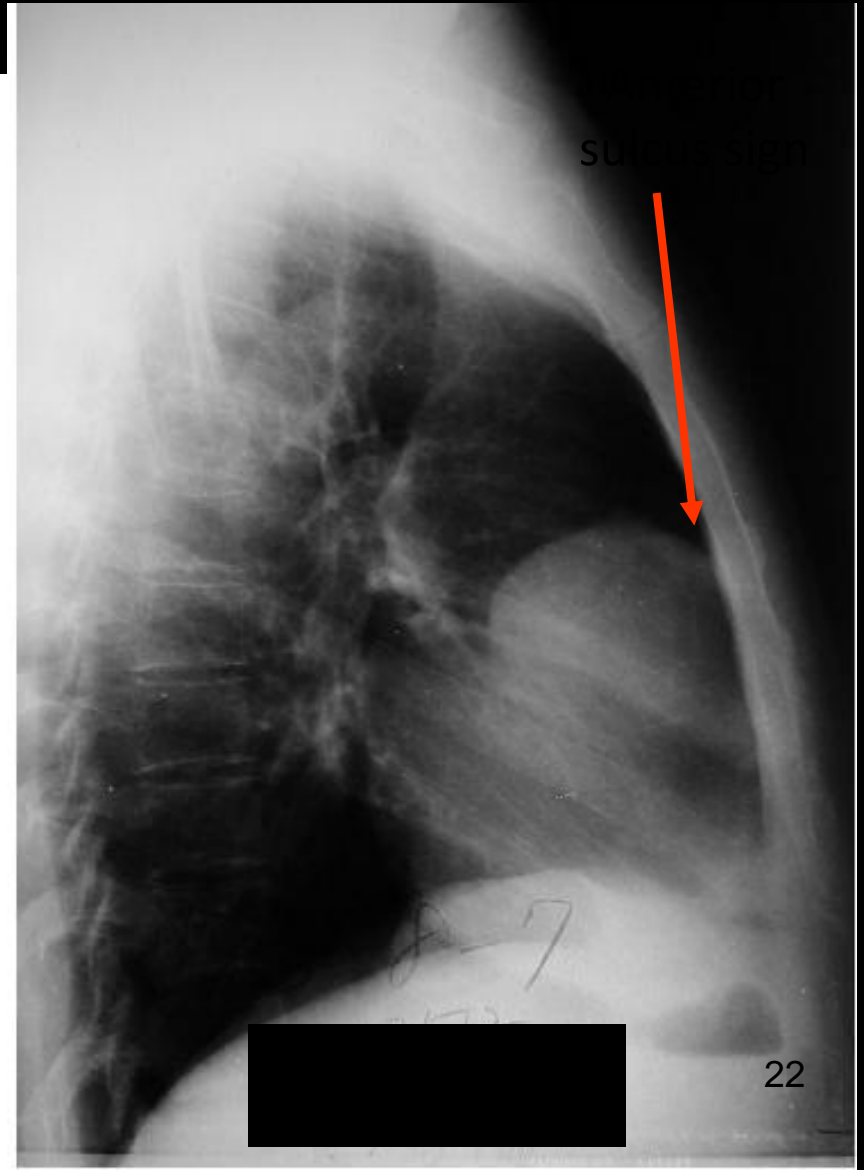
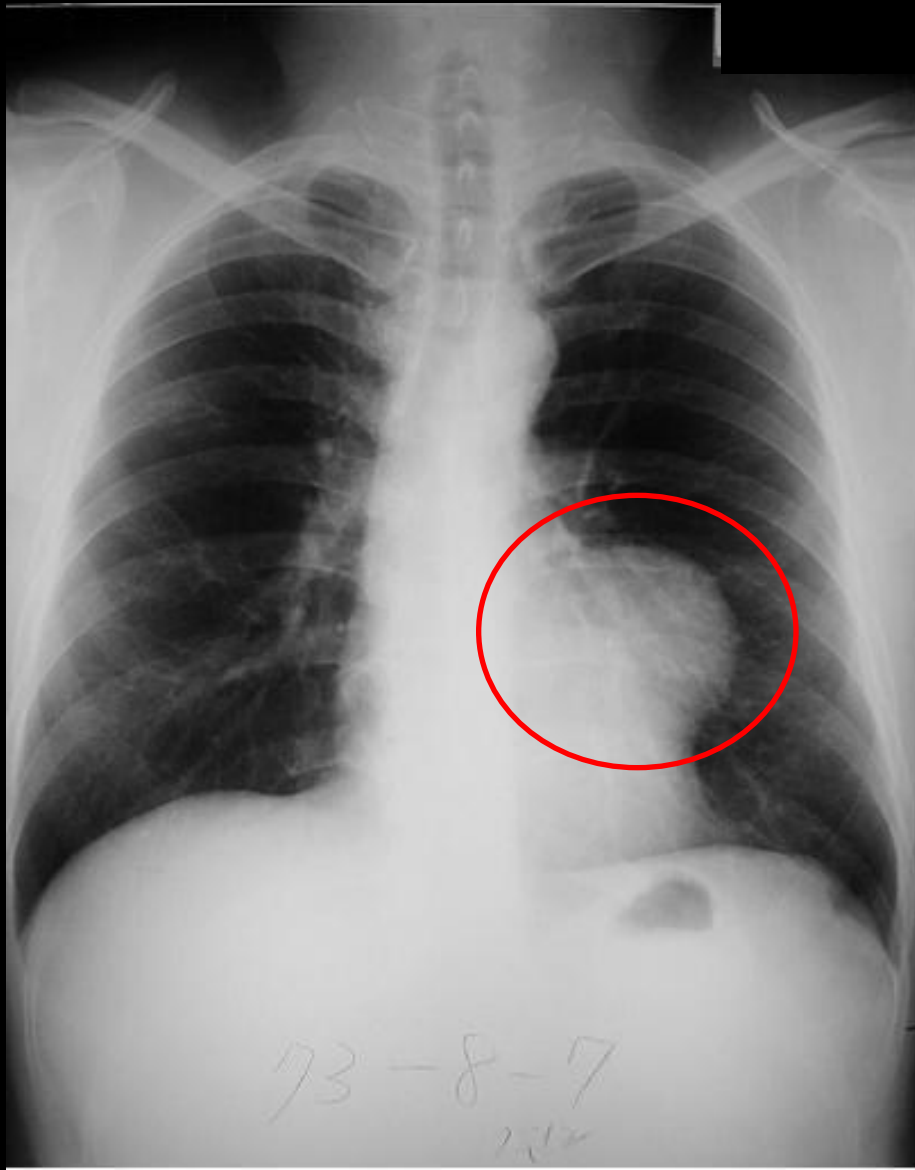
- 前邊界 : sternum
- 後邊界 : ant. tracheal wall – post. heart border
- 上邊界 : thoracic inlet
- 下邊界 : diaphragm
- 內容物: (記3T1L)
thymus, thyroid (intrathoracic),
heart, great
vessels, lymph nodes, fat

Anterior mediastinum mass

- **Prevascular area (3T1L)**
 - Thymus: thymoma, thymic carcinoma
 - Thyroid: multinodular goiter, thyroid carcinoma, thyroiditis
 - Teratoma: germ cell tumor (seminoma, non-seminoma)
 - Lymphoma: Hodgkin's lymphoma, NHL, metastatic lymph nodes

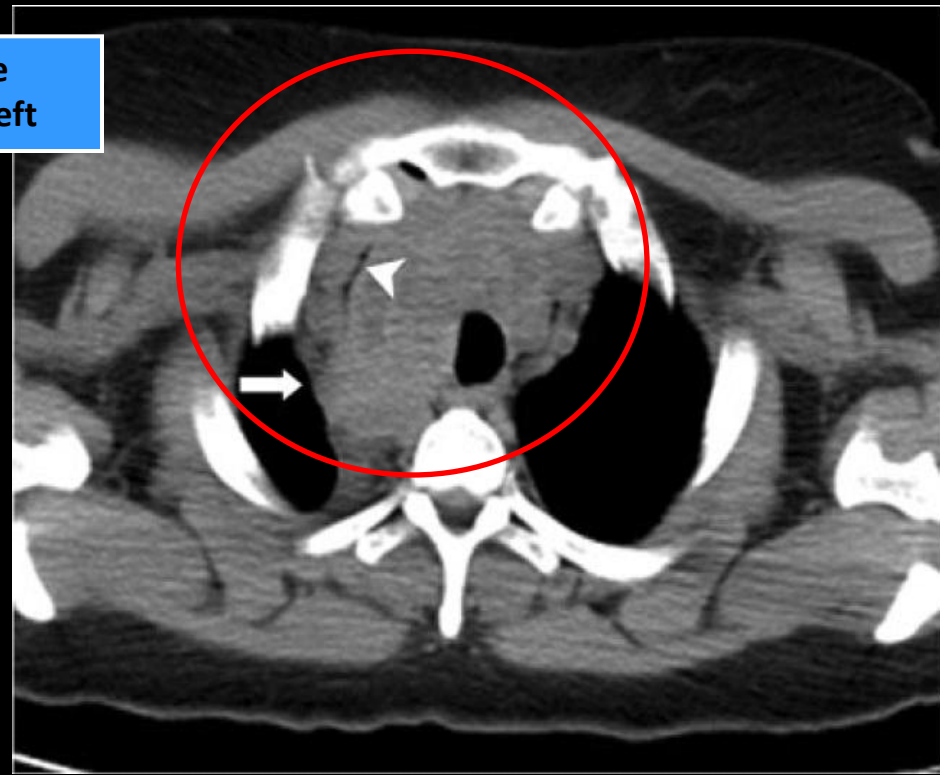
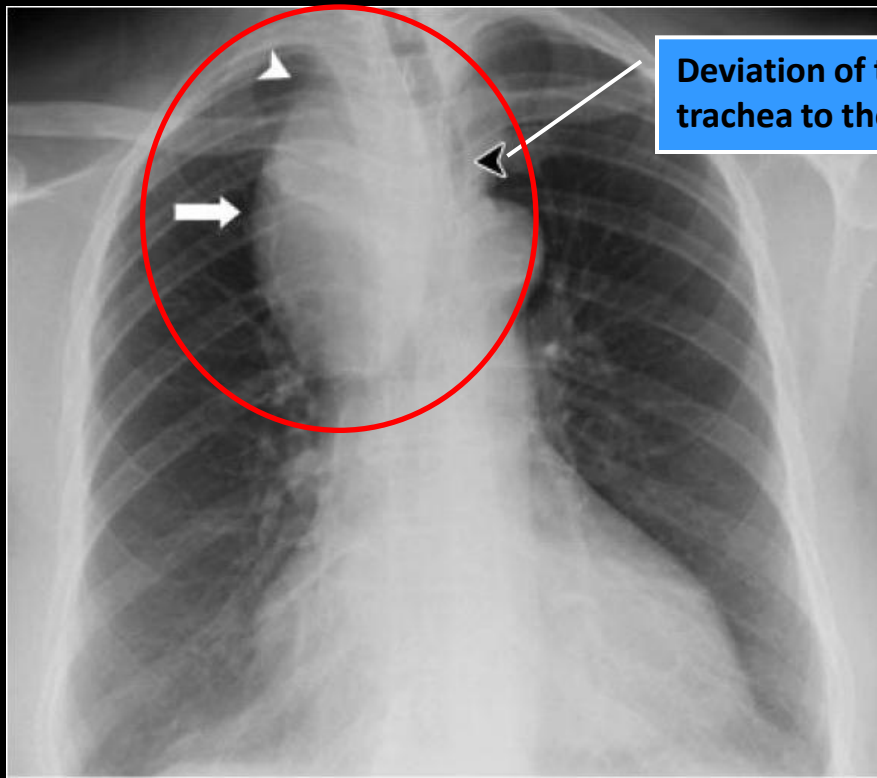
- **Cardiophrenic area**
 - Morgagni's hernia
 - Thymus disease
 - Germ cell tumor
 - Lymph node metastasis
 - Pericardial cyst

Thymoma (前、圓、慢、免疫)

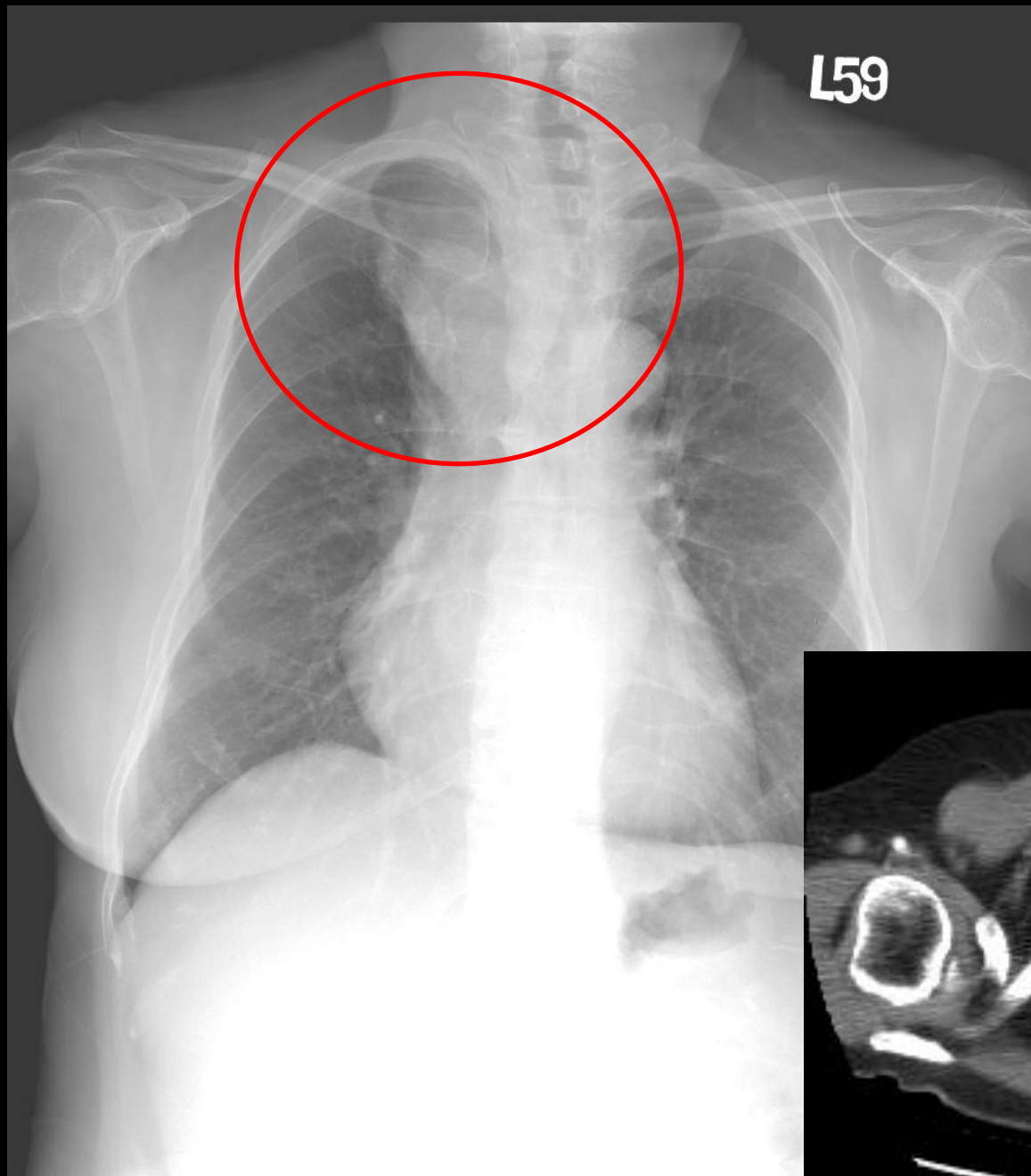


Thyroid (Goiter) (前上、圓、位移、可鈣化)

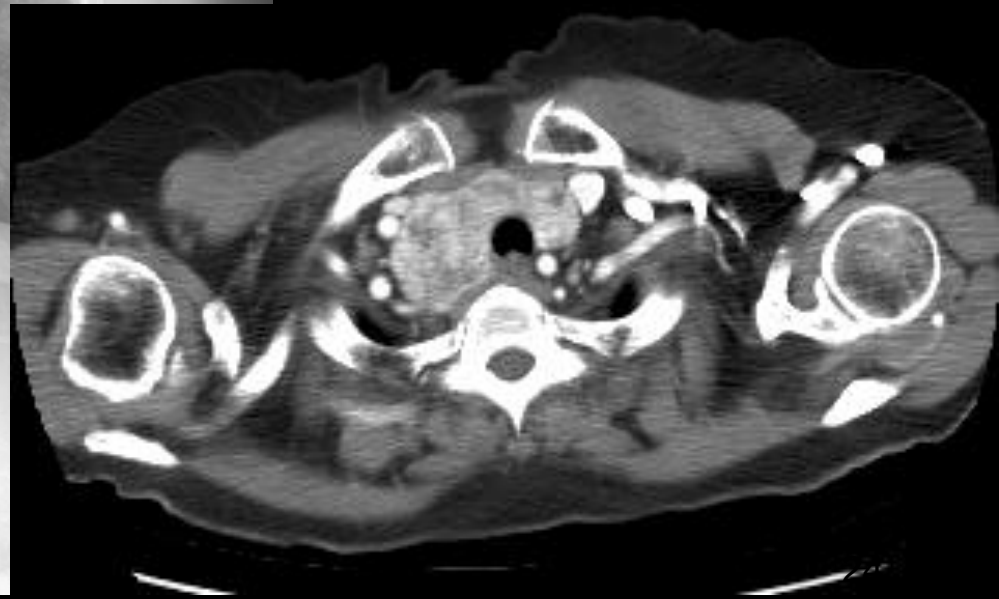
Right- retrosternal goiter



The margins of the mass above clavicle are not sharp, indicating that the mass has an anterior mediastinal component.

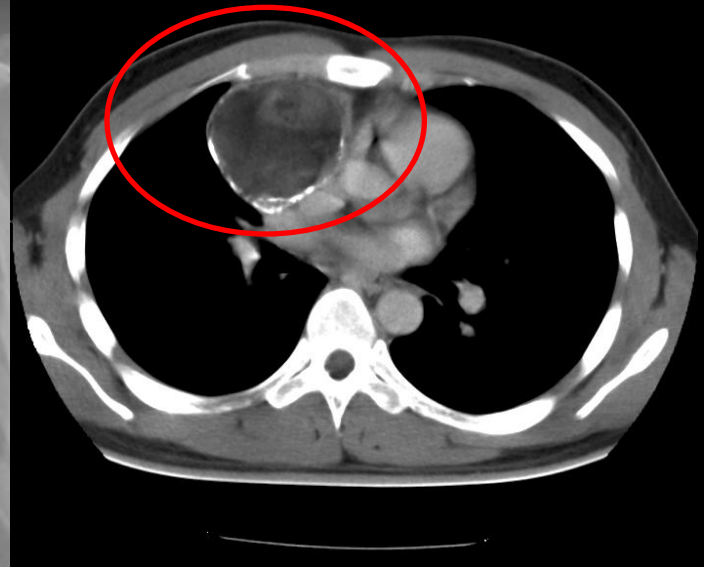
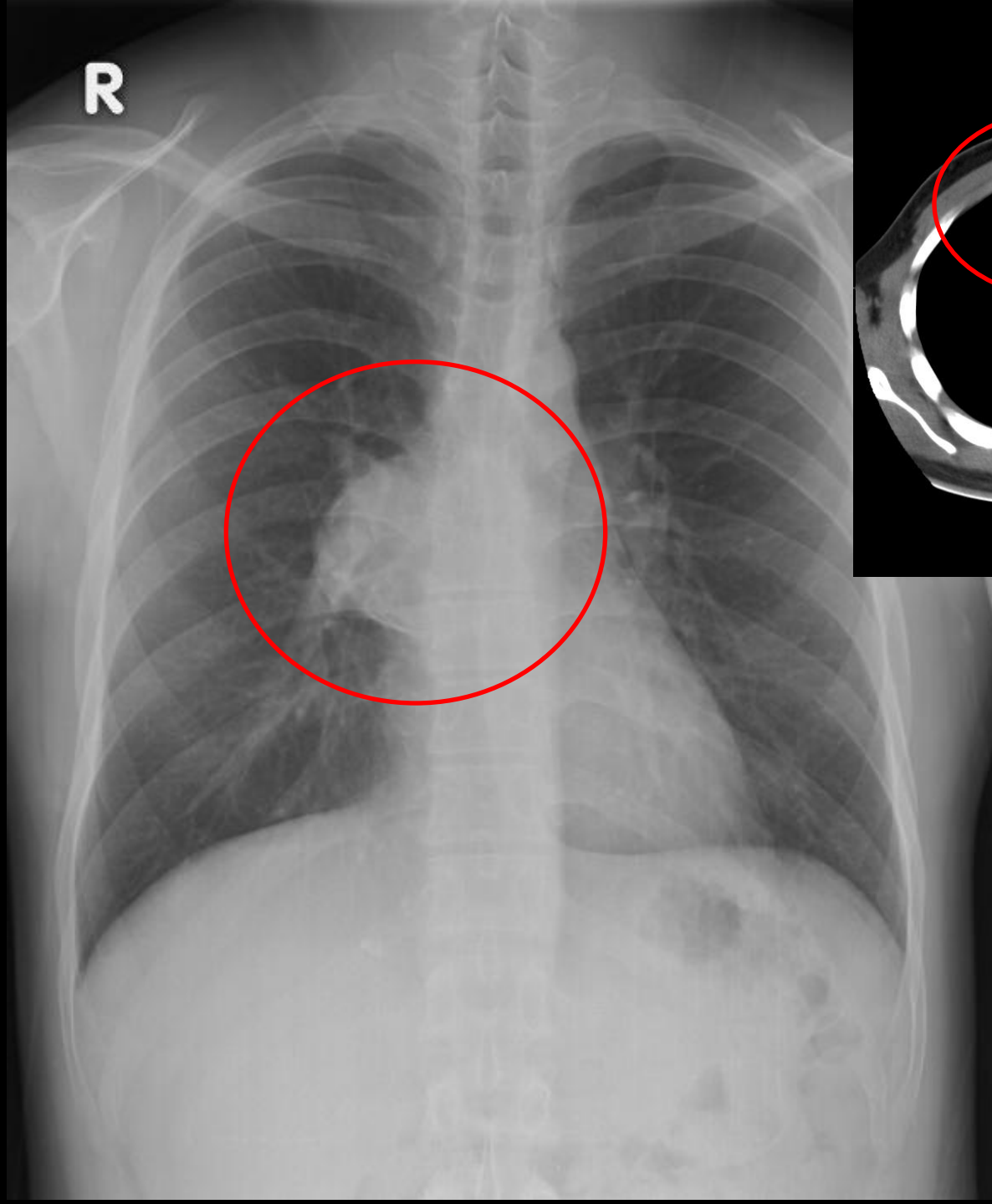


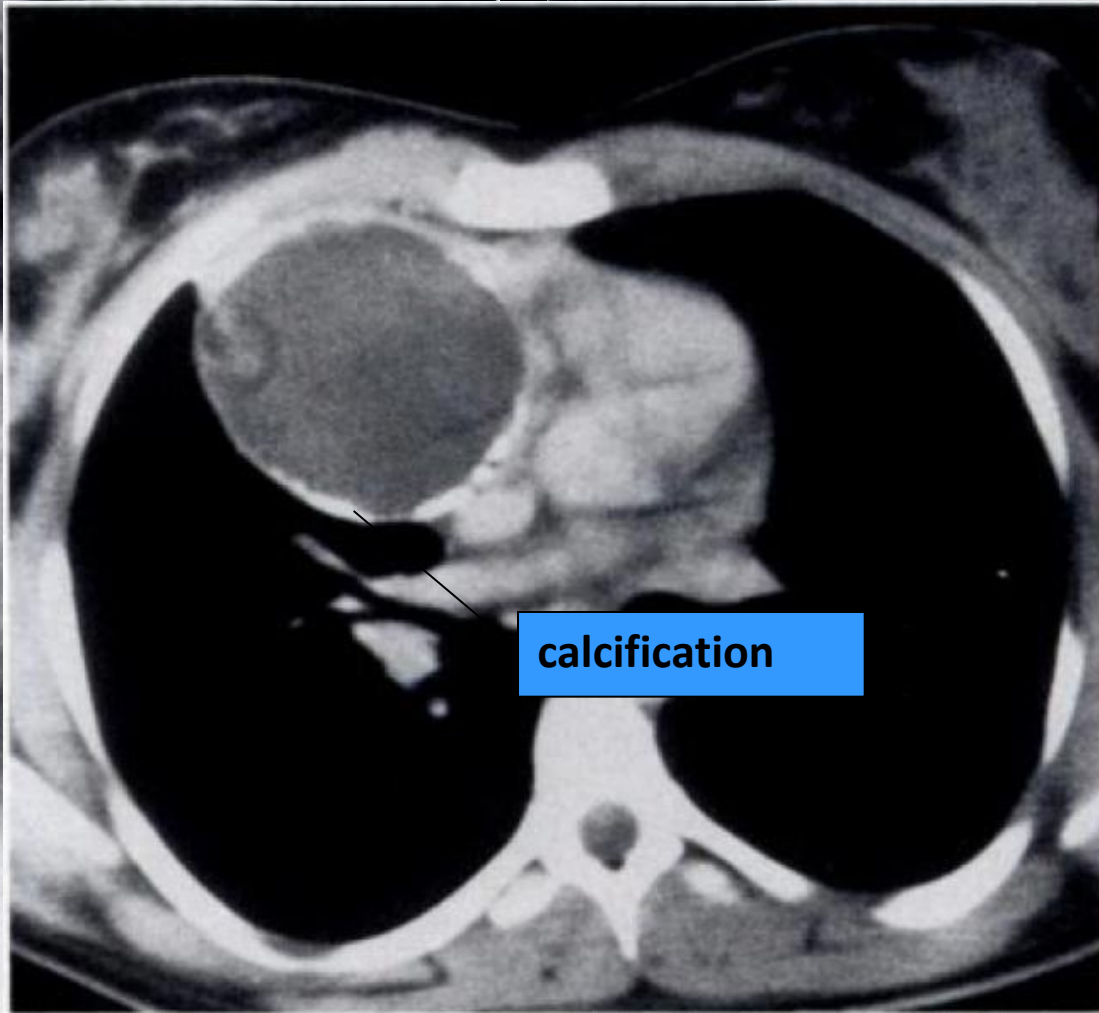
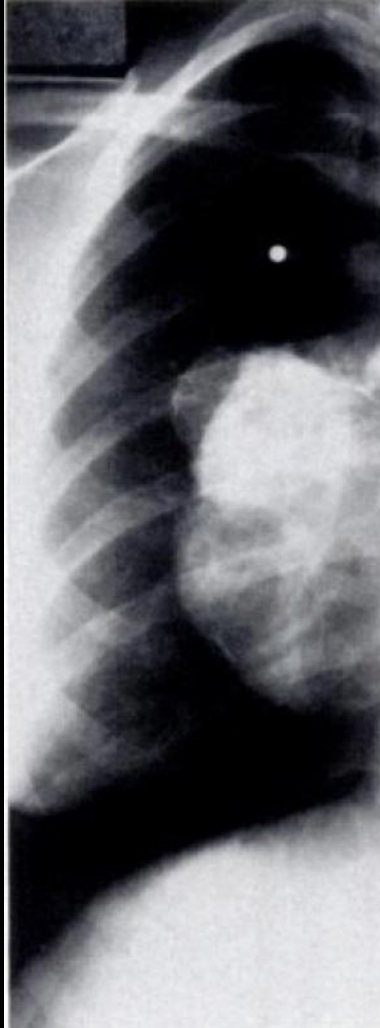Contrast, Iodine



Teratoma (前、軟、年輕、多元、鈣化)

- Most common mediastinal GCT; 70%
- often in children, young adult(20-30y/o); 男=女
- 3 histologic types:
 - Mature teratoma: benign
 - Immature teratoma: low potential malignancy
 - Teratoma with malignant transformation: aggressive
- CXR:
 - Lopsided(偏向一邊), lobulated, well-marginated mass; most common in anterior mediastinum(85%)
 - 25% calcification
 - Soft, tend to flatten to mediastinum: 與thymoma不同
- CT:
 - Multiloculated cystic mass with variable thickness wall(80%), may contain fat, fluid, soft tissue and calcification densities





calcification

<比較> 位置相近，同為well-defined anterior mediastinal mass

	年齡	與sternum 接觸時
Thymoma	中年人 (>40y/o)	Not flattened (Ant. Sulcus sign)
Teratoma	兒童或年輕人	Flattened

Germ Cell Tumors (GCT)

- Introduction of germ cell tumor

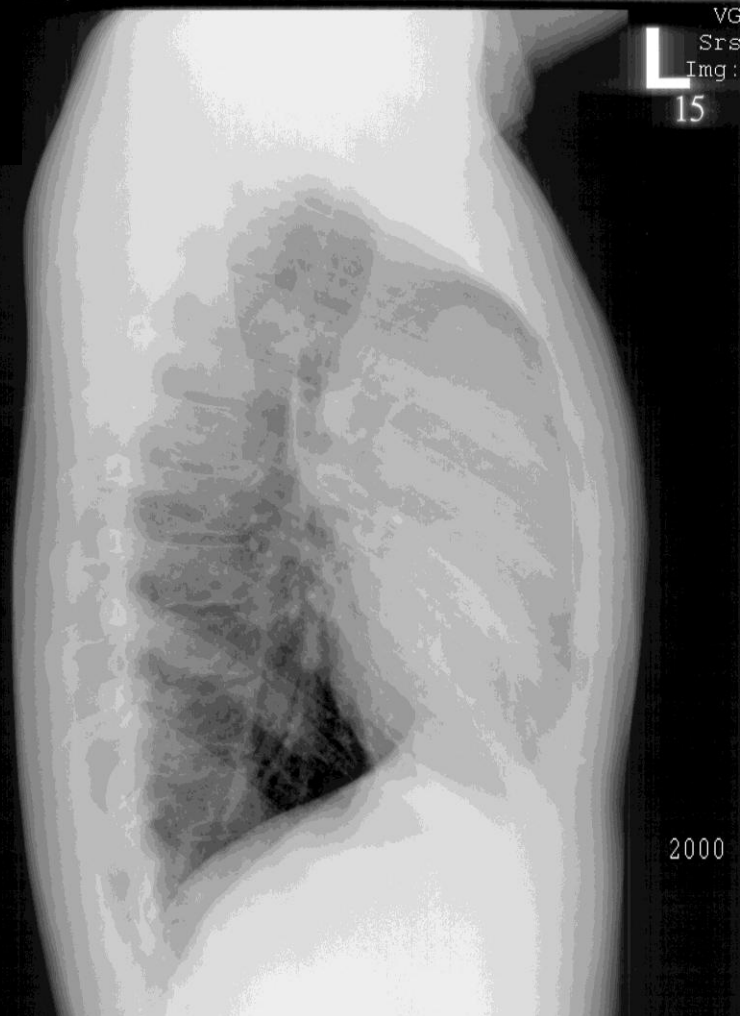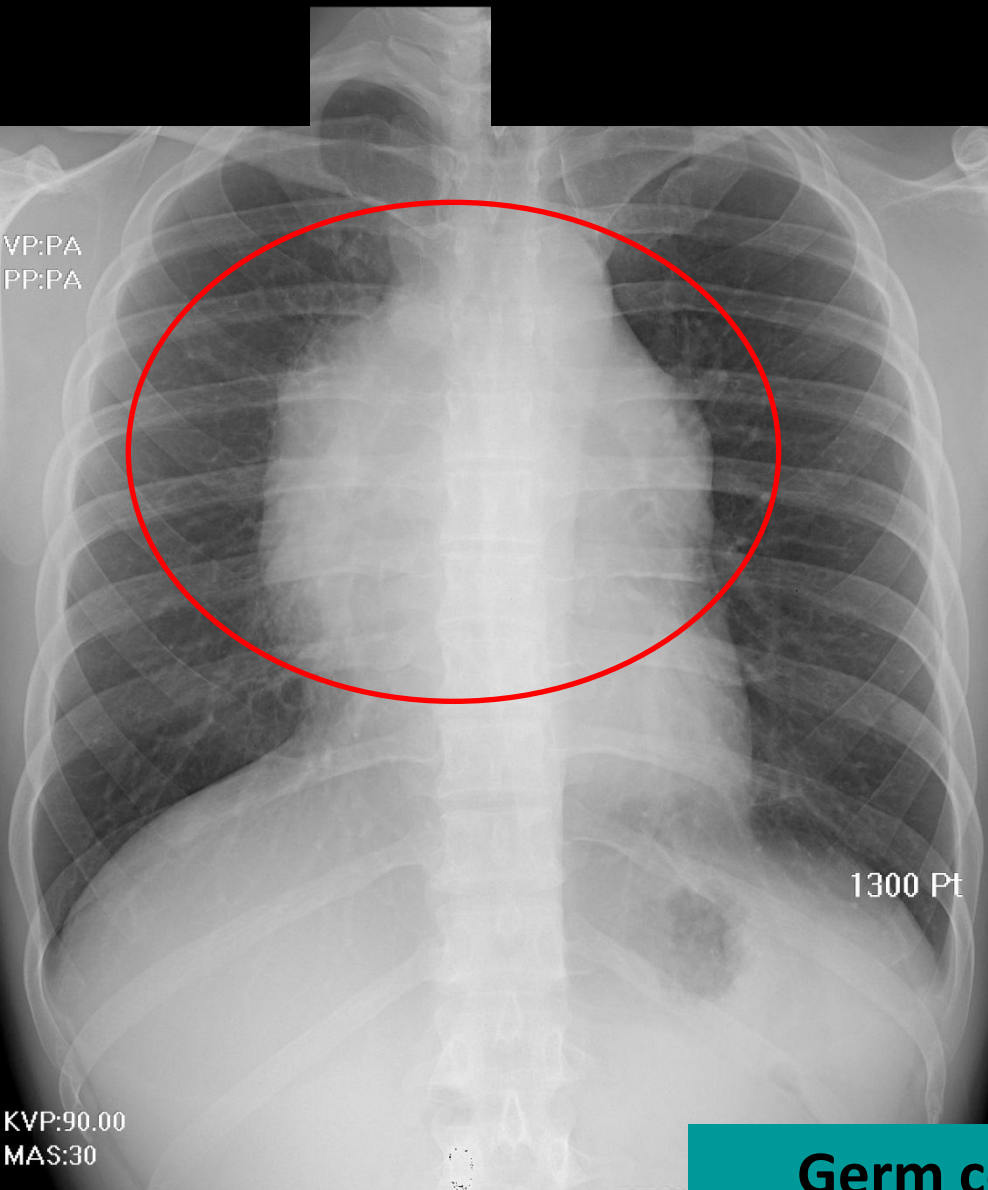
- 10% primary mediastinal masses, 20~40 year-old
- teratoma, seminoma, embryonal carcinoma, yolk sac tumor...etc
- Benign (mature teratoma) vs malignant (seminoma, malignant teratoma)

- Classifications

- Teratoma
- Seminoma
- Non-seminomatous germ cell tumor (NSGCT)

- Plain Film Characters

- Soft-tissue, fat, calcification, cystic fluid collection
- Flatten against sternum
- Relative large size at diagnosis (8cm~10cm)



Germ cell tumor
AFP: 9839.52 ng/ml

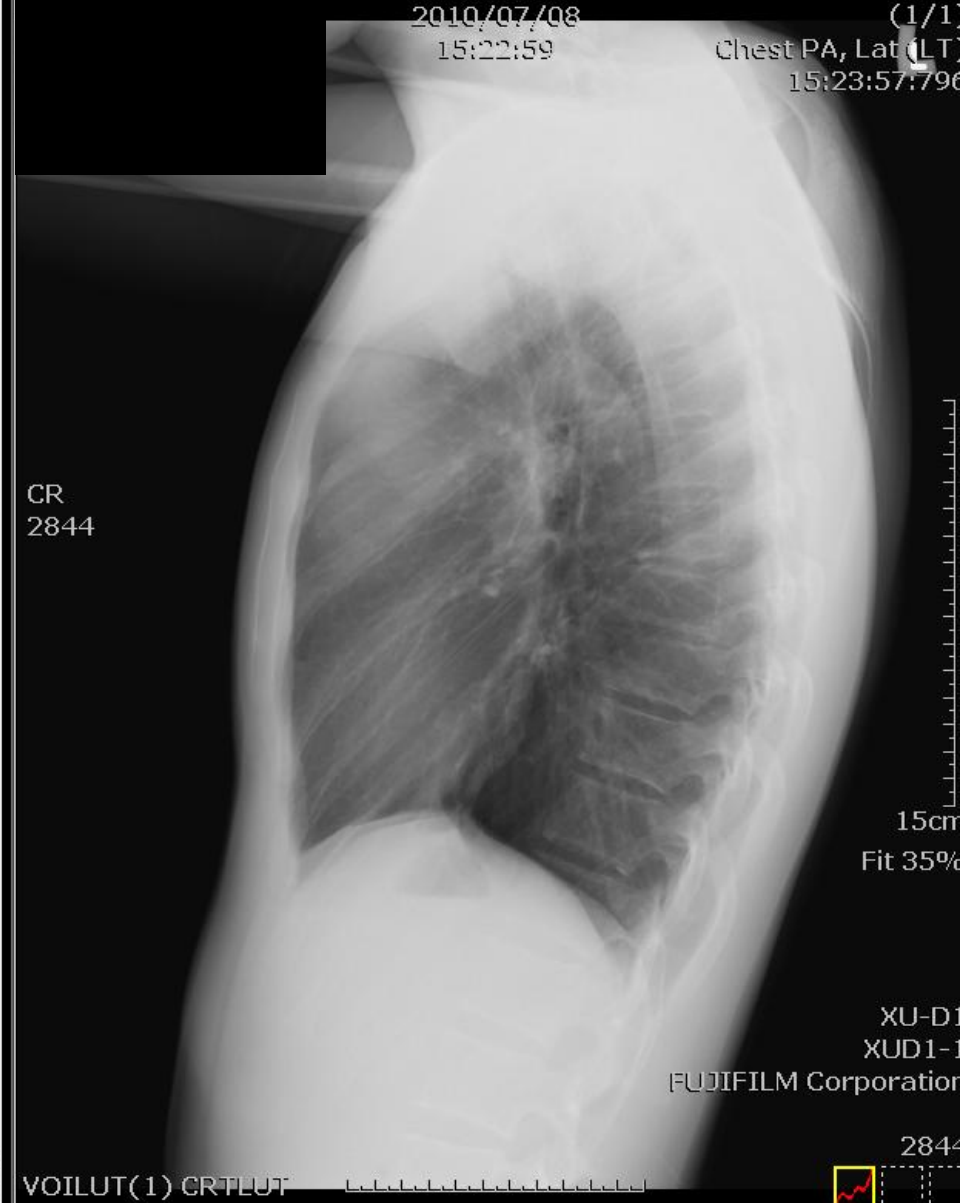
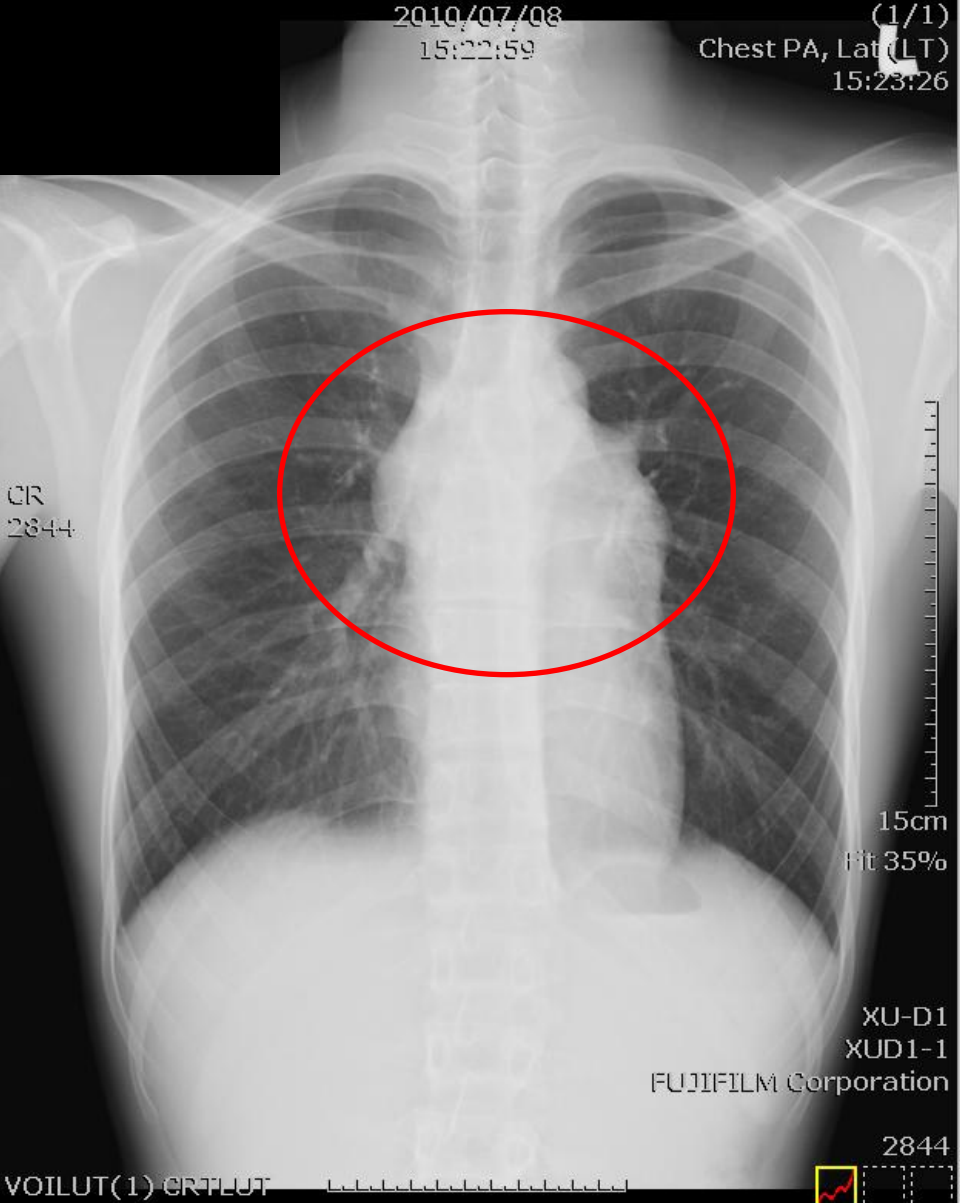
Lymadenopathy_lymphoma

- Introduction

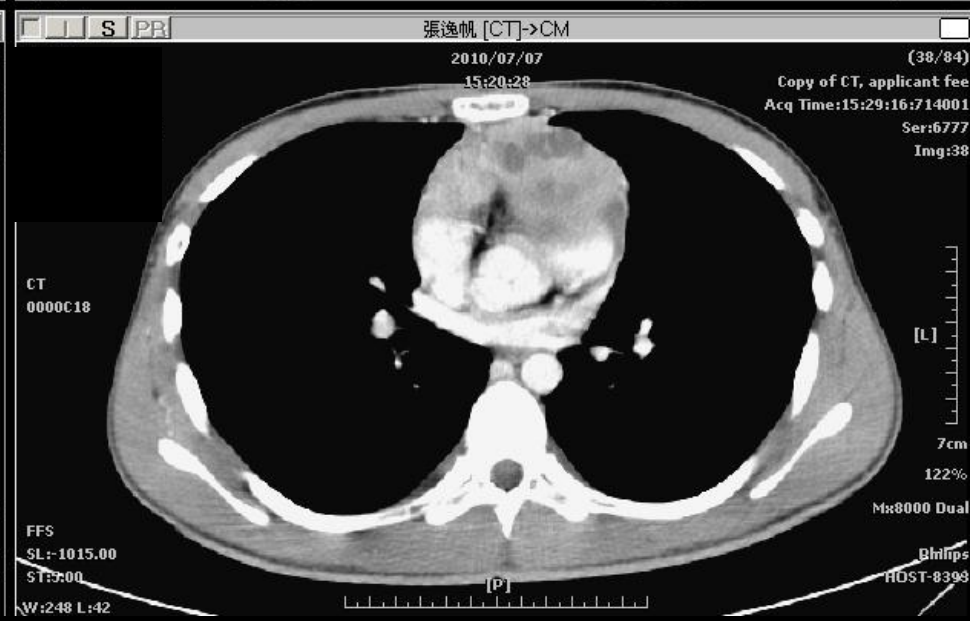
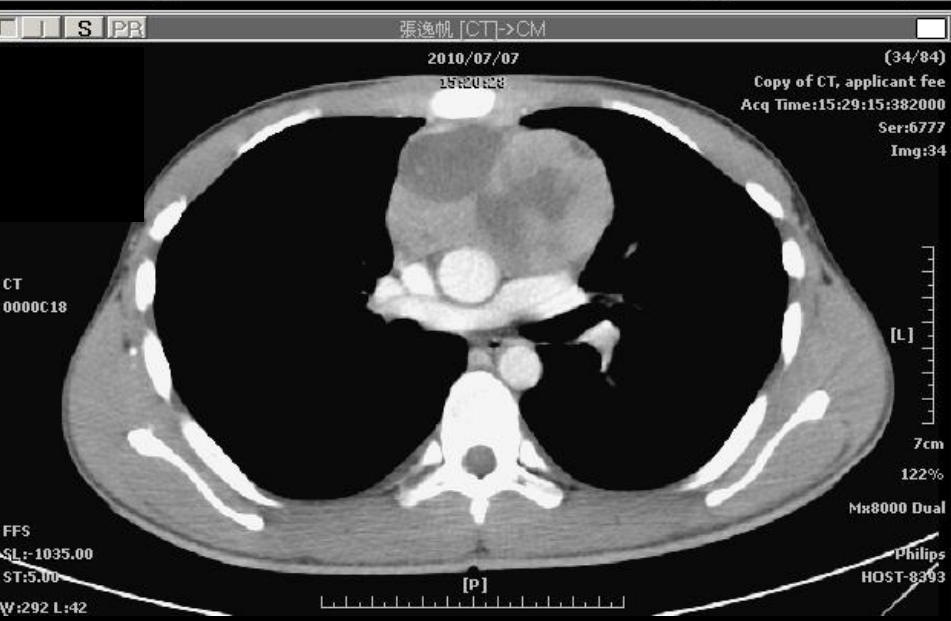
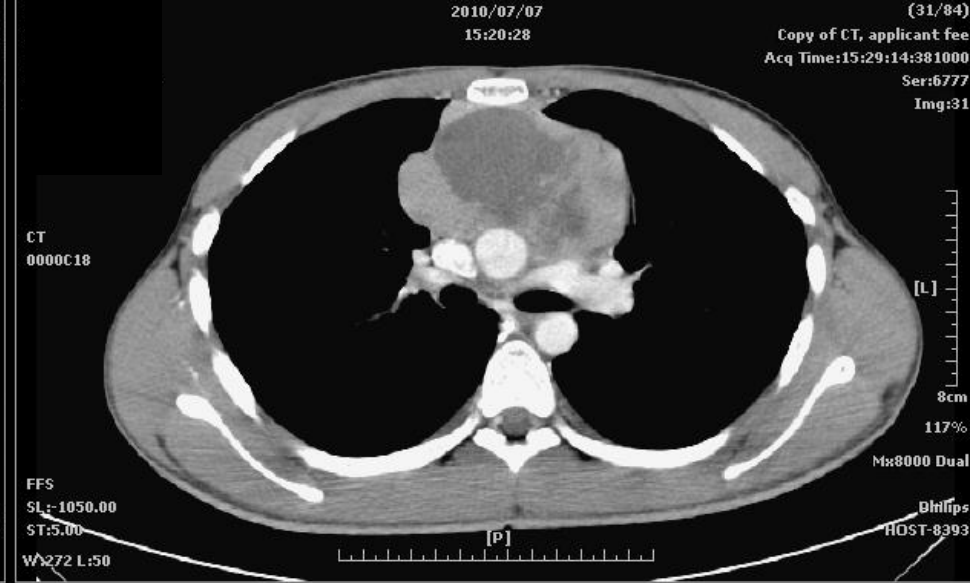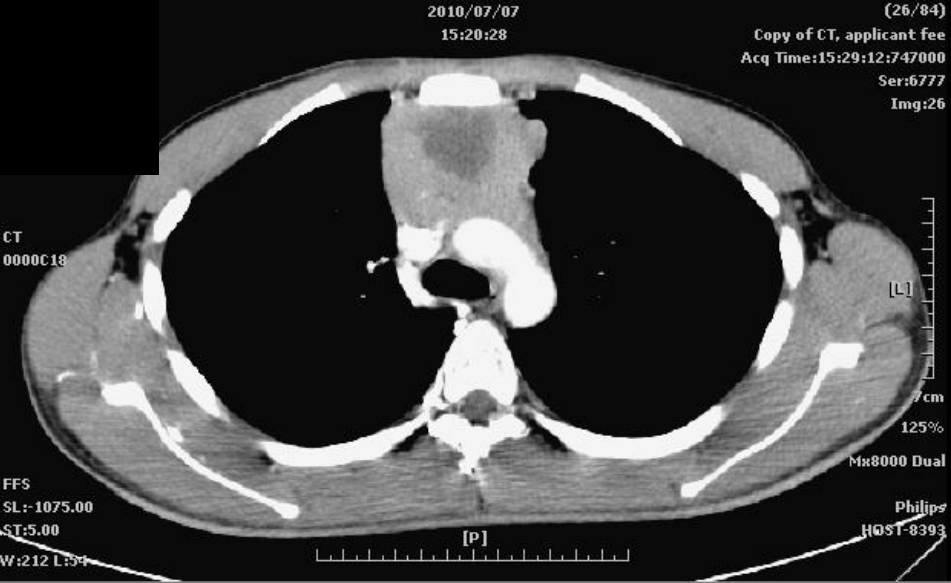
- 85% Hodgkin's lymphoma presented multiple mediastinal adenopathy (superior mediastinal nodes: prevascular, paratracheal, aortopulmonary)

- Plain Film Characters

- well-circumscribed mass on PA view, but ill-defined on lateral view
- complete obliteration of retrosternal space
- silhouetting of normal structure (ex: ascending aorta)
- Poor marginated mass, involving multiple nodes and thymus

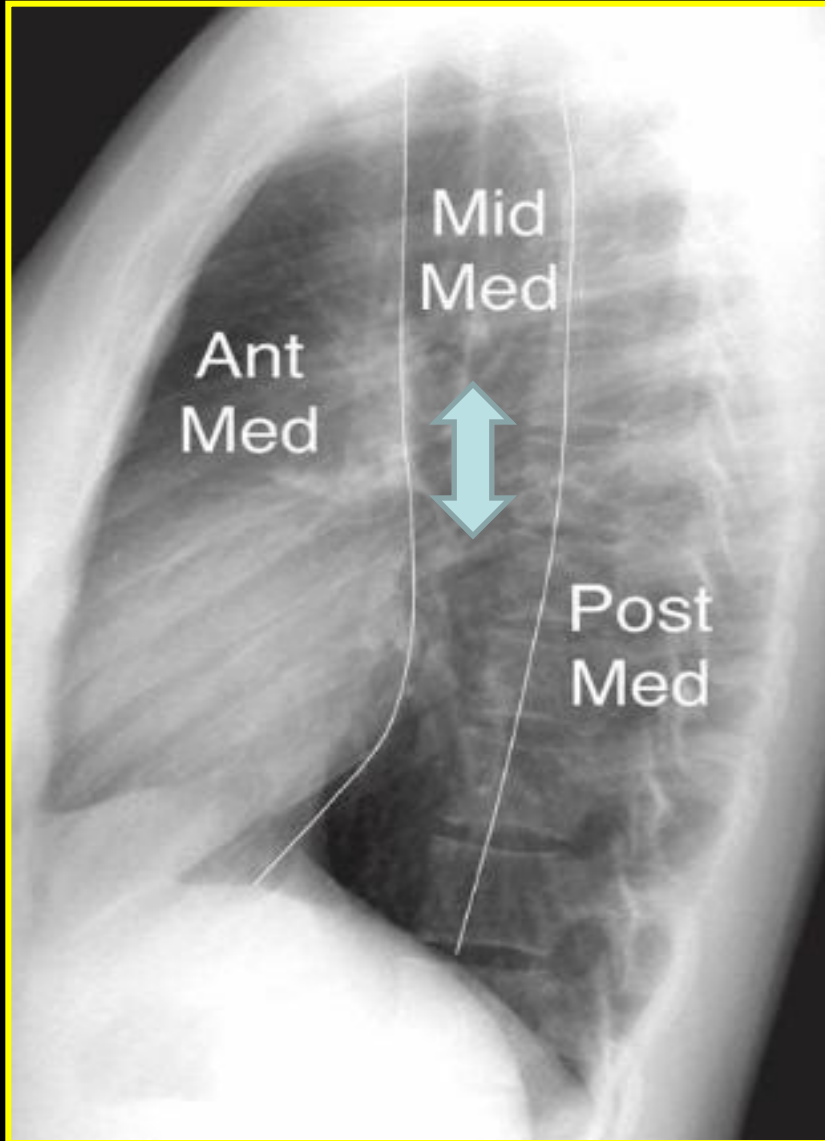


anterior mediastinum mass, lymphoma (ALL)



anterior mediastinum mass, lymphoma (ALL)

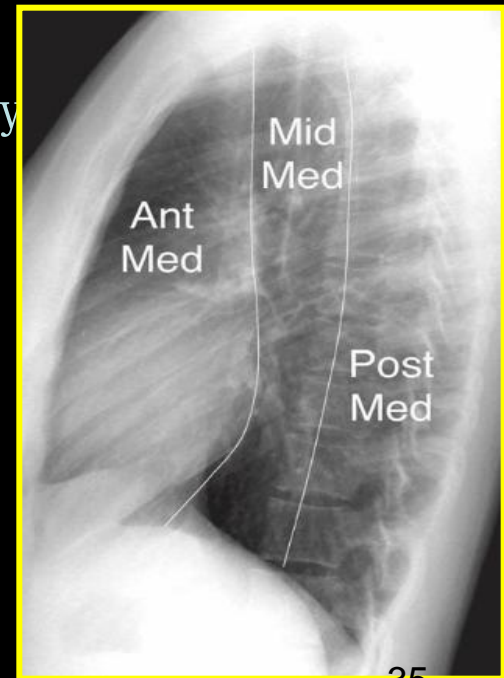
Middle mediastinum

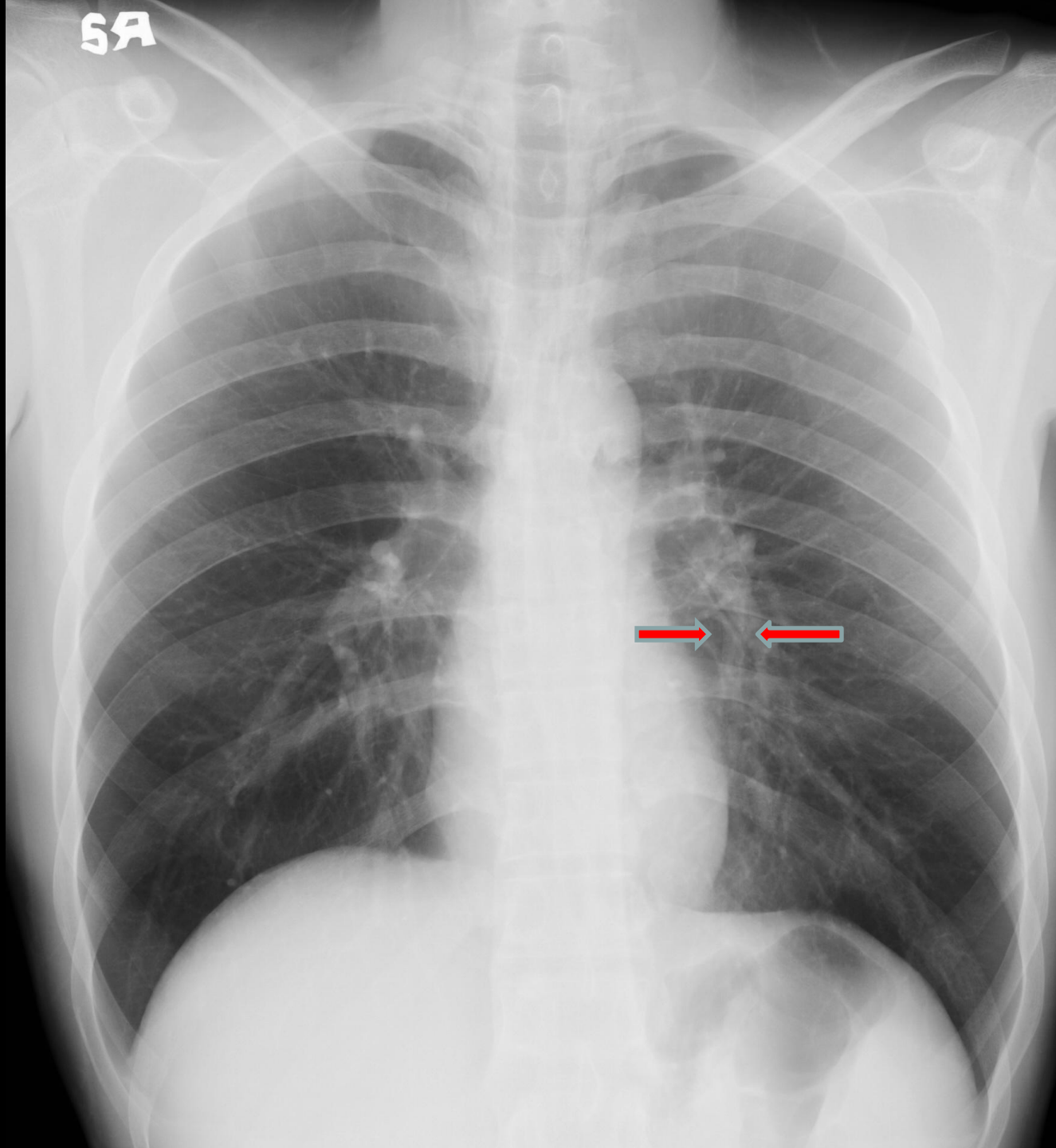


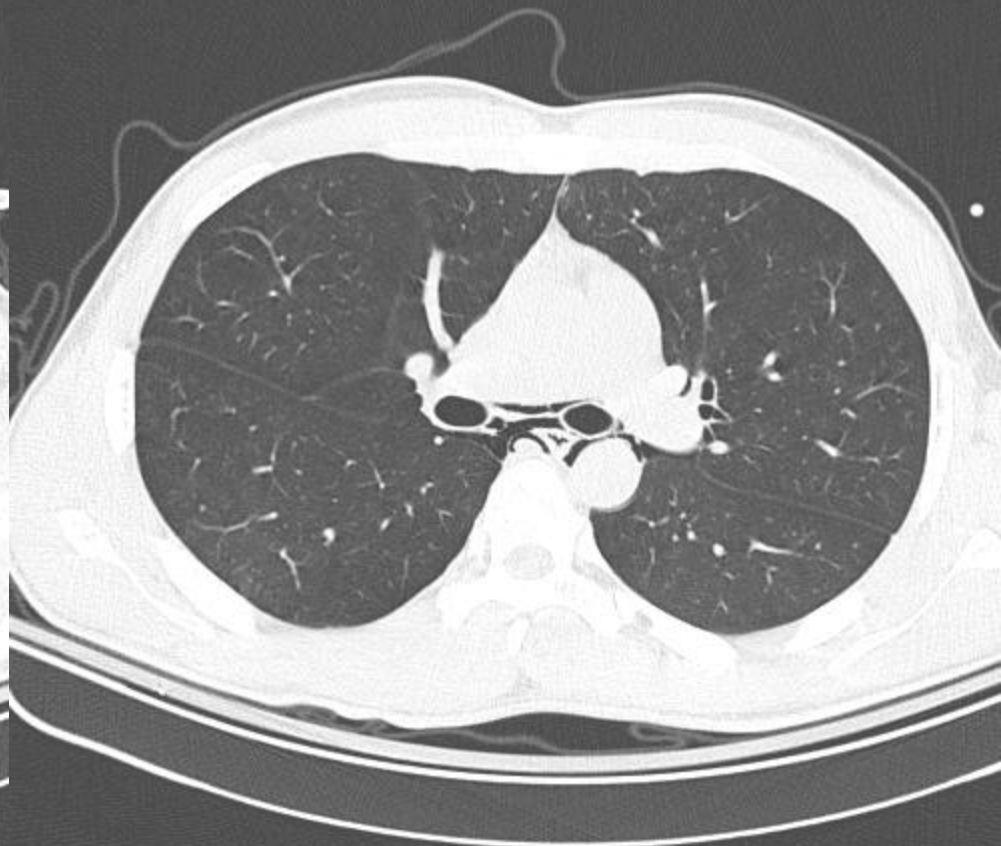
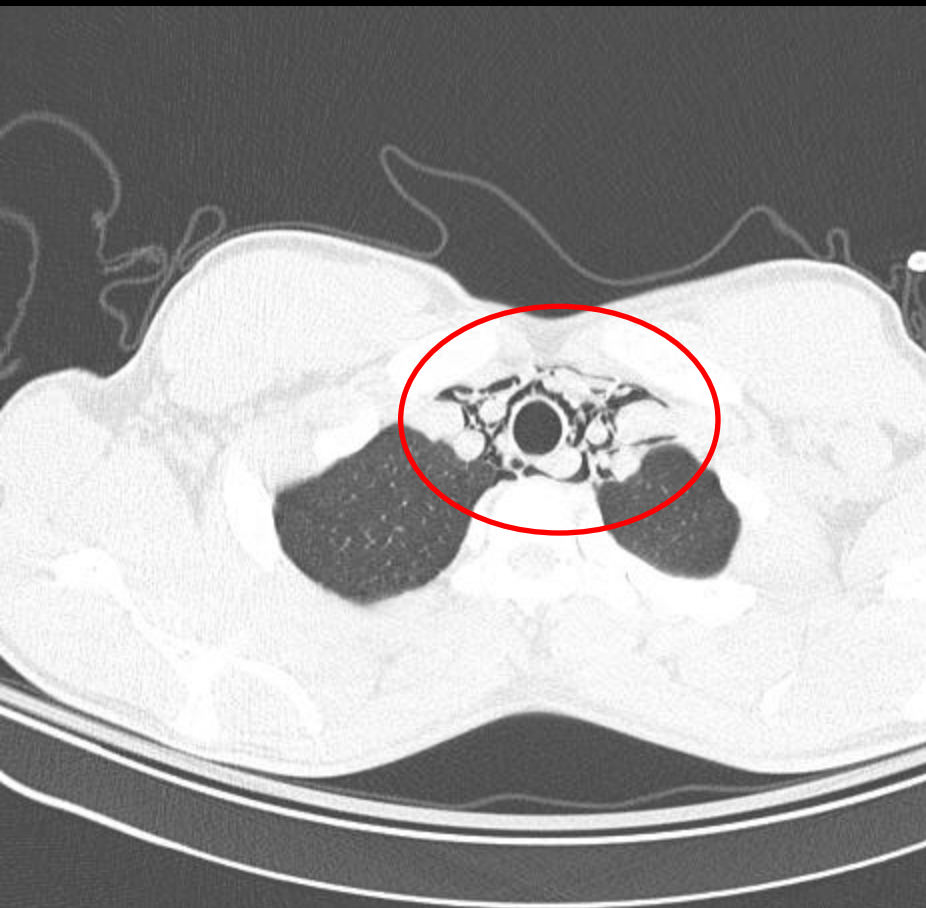
- **前邊界** : ant. tracheal wall – post. heart border
- **後邊界** : 1cm behind ant. vertebral body
- **上邊界** : thoracic inlet
- **下邊界** : diaphragm
- **內容物** :
trachea, main bronchus, aortic arch, SVC/IVC, esophagus, lymph nodes

Middle mediastinum mass

- Lymph node mass
 - sarcoidosis, lymphoma, lung carcinoma, tuberculosis, metastasis
- Vascular abnormalities
 - acute aortic syndrome: aortic aneurysm, dissection, PAU
- Foregut Cyst
 - bronchogenic cyst, esophageal duplication cy
- Esophageal mass
 - Carcinoma, achalasia
- Hernia
- Varices

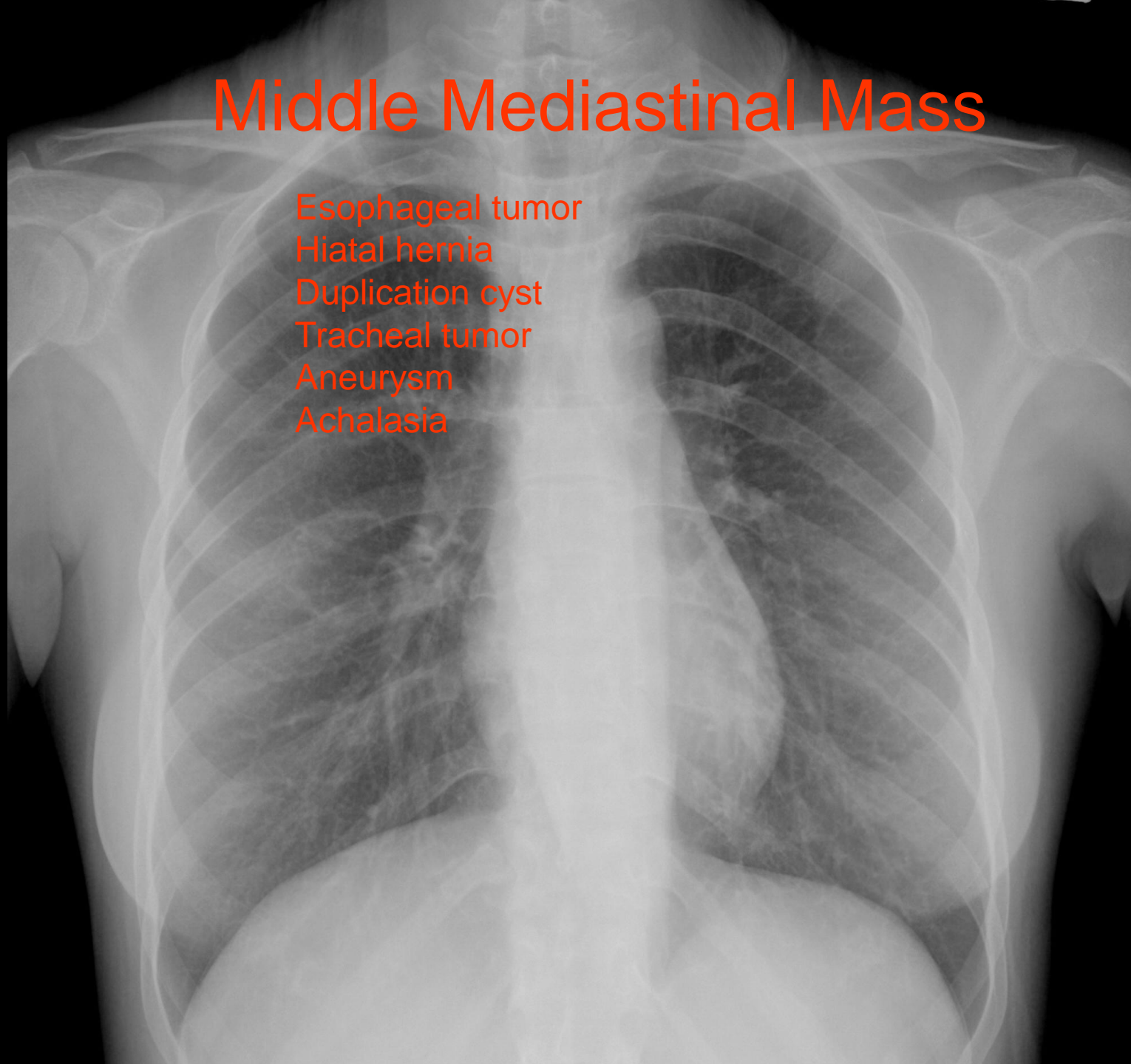


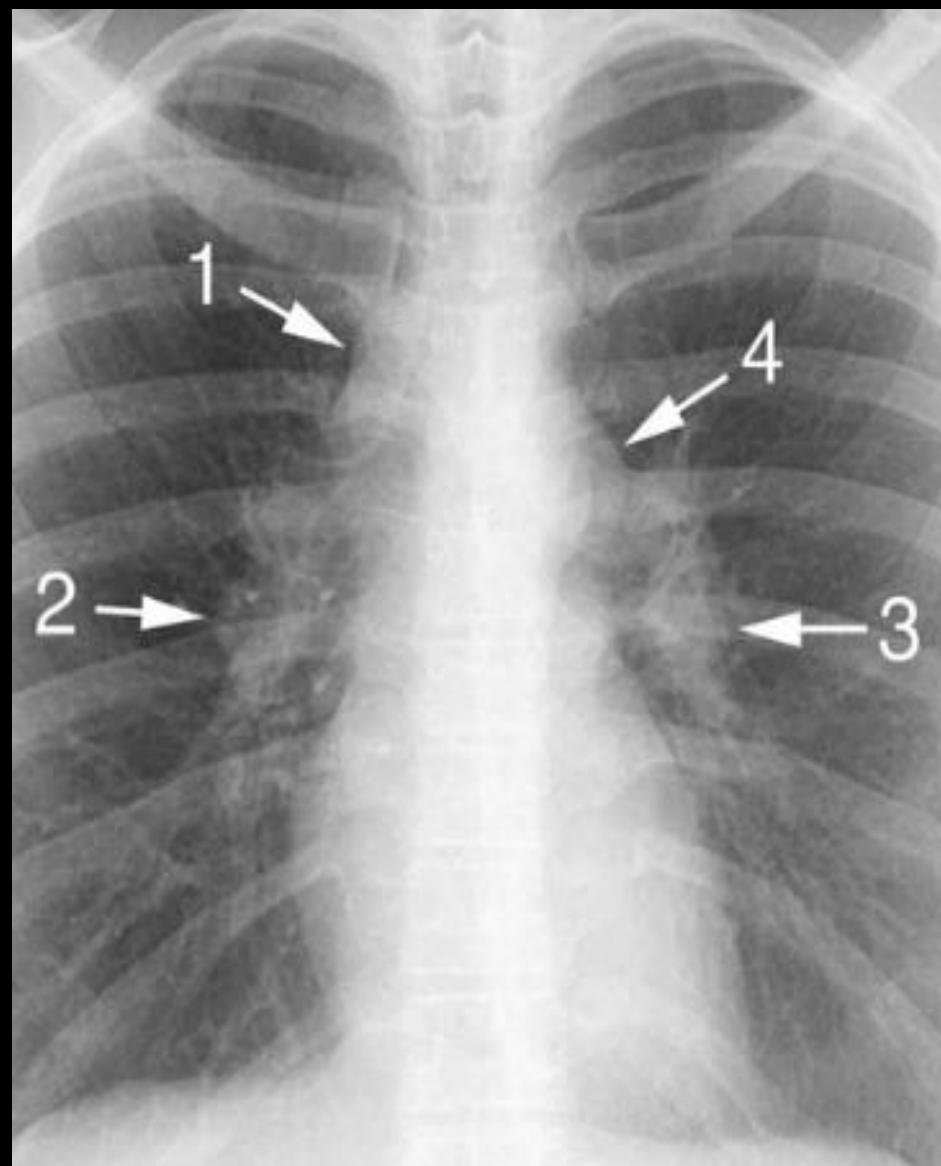




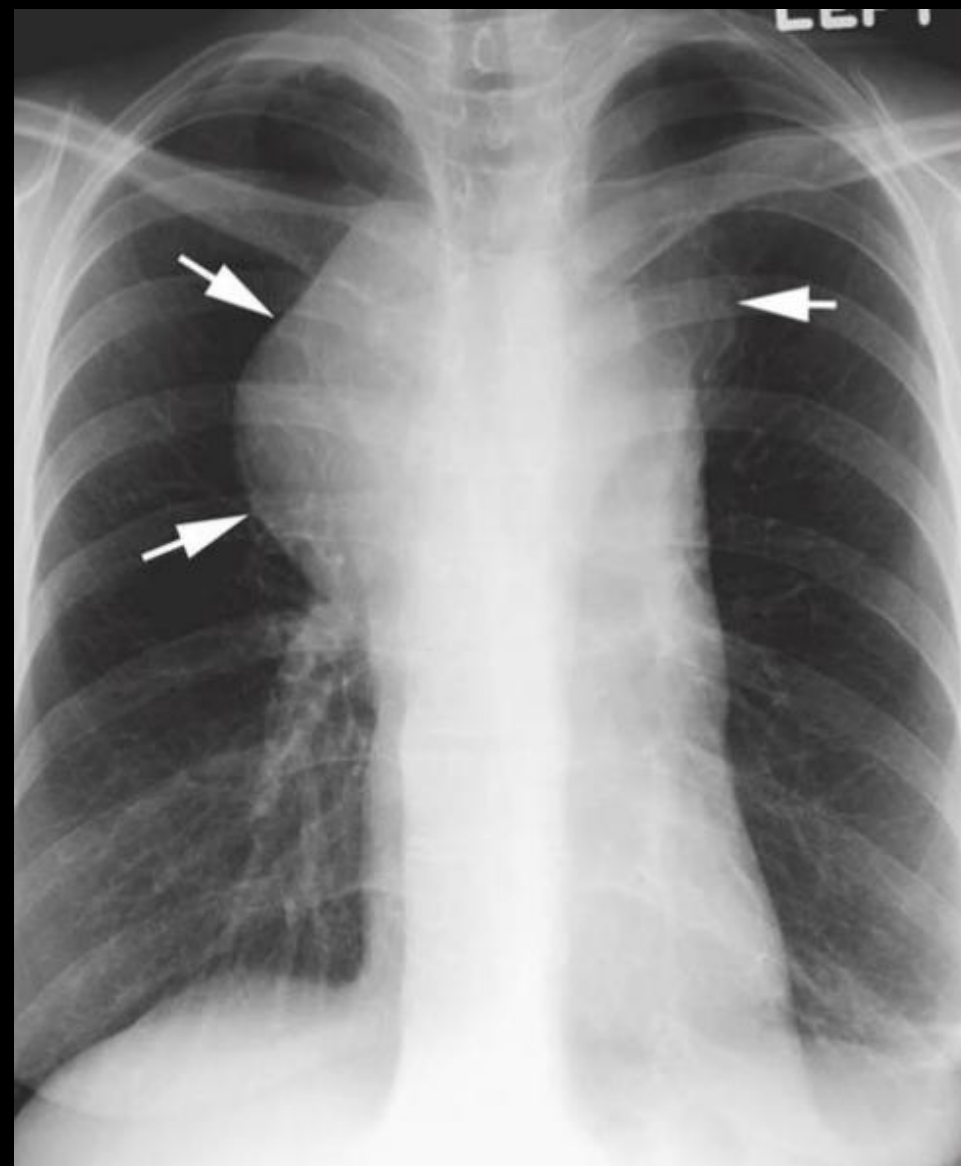Middle Mediastinal Mass

Esophageal tumor
Hiatal hernia
Duplication cyst
Tracheal tumor
Aneurysm
Achalasia





Sarcoidosis



Hodgkin's lymphoma

Foregut Cyst _ Bronchogenic Cyst

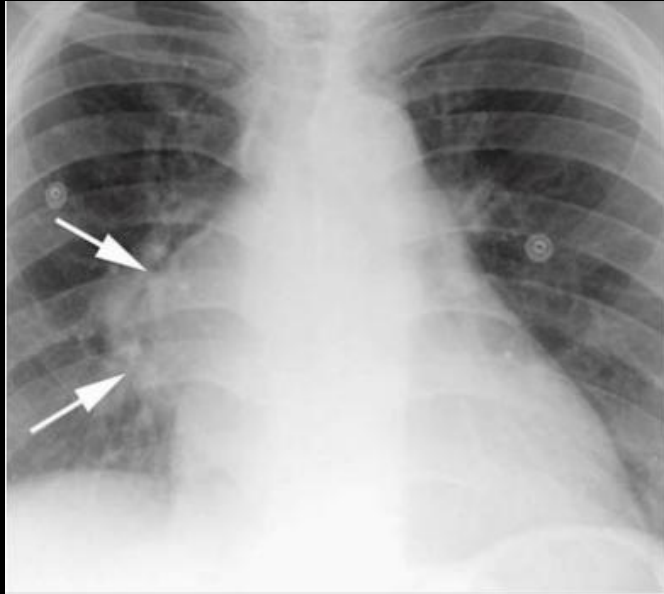
- Introduction

- Defective growth of lung budding during fetus
- Contained respiratory epithelium, smooth muscle, gland, or cartilage
- Gradually Enlargement, Mass effect and compression adjacent structure
- Rapid growth with pain, indicating hemorrhage or infection

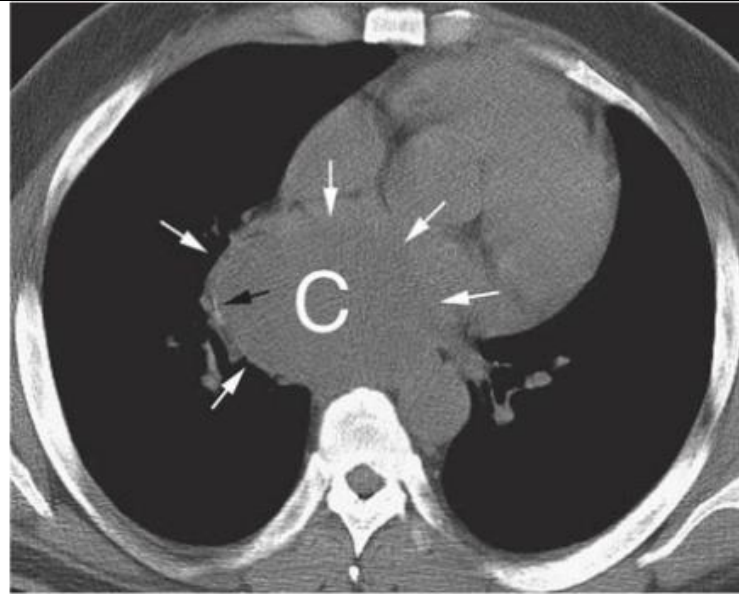
- Plain Film Character

- Round, smooth, sharply defined mass
- **Subcarina** (50%) > paratracheal (20%) > retrocardiac (10%)
- Can be large and displace trachea or bronchus
- Subcarinal cyst result in convexity in azygoesophageal recess

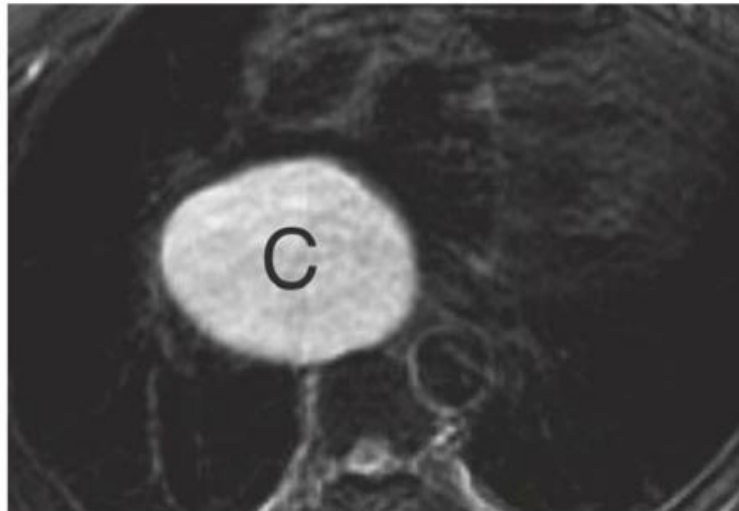
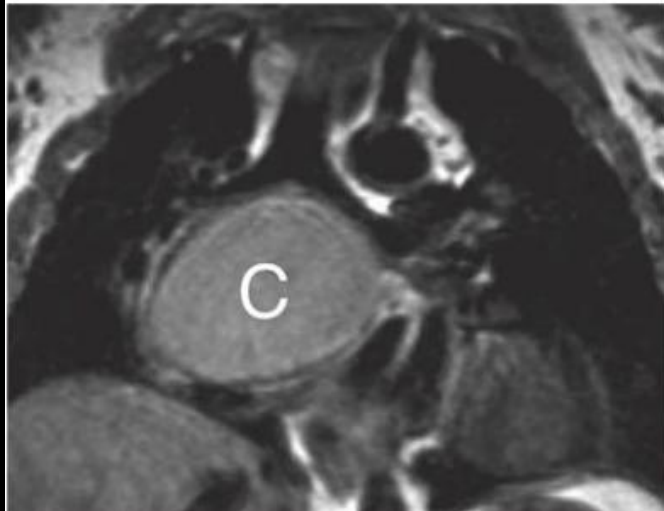Bronchogenic Cyst

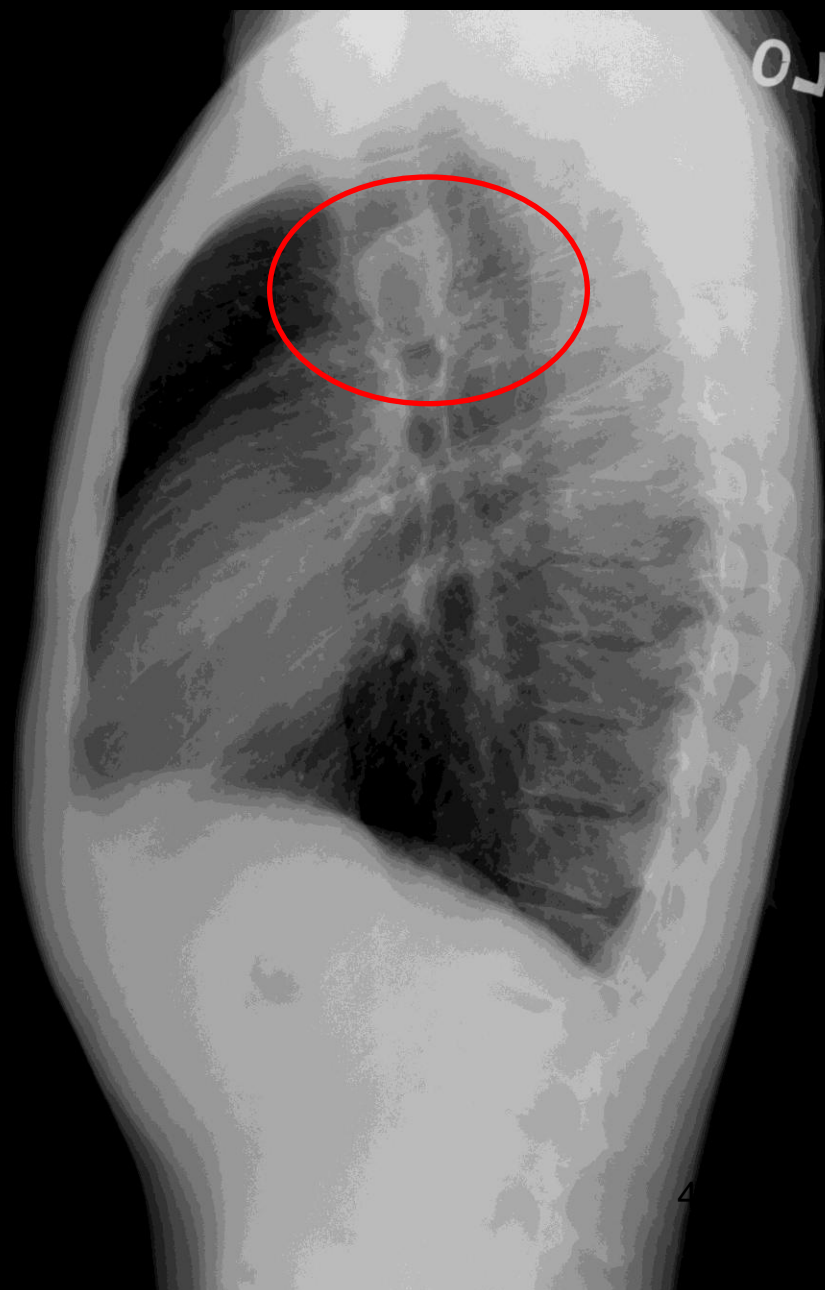
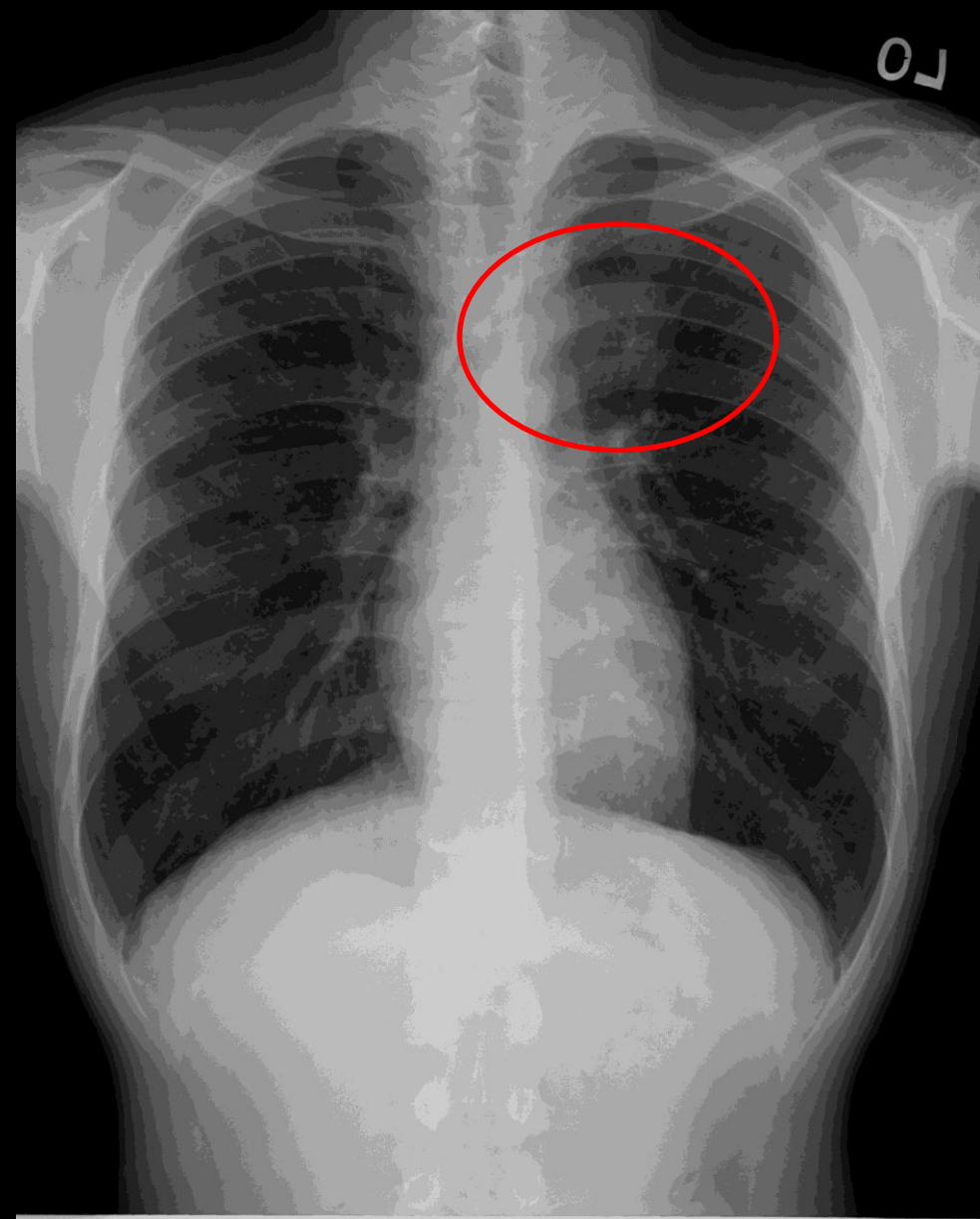


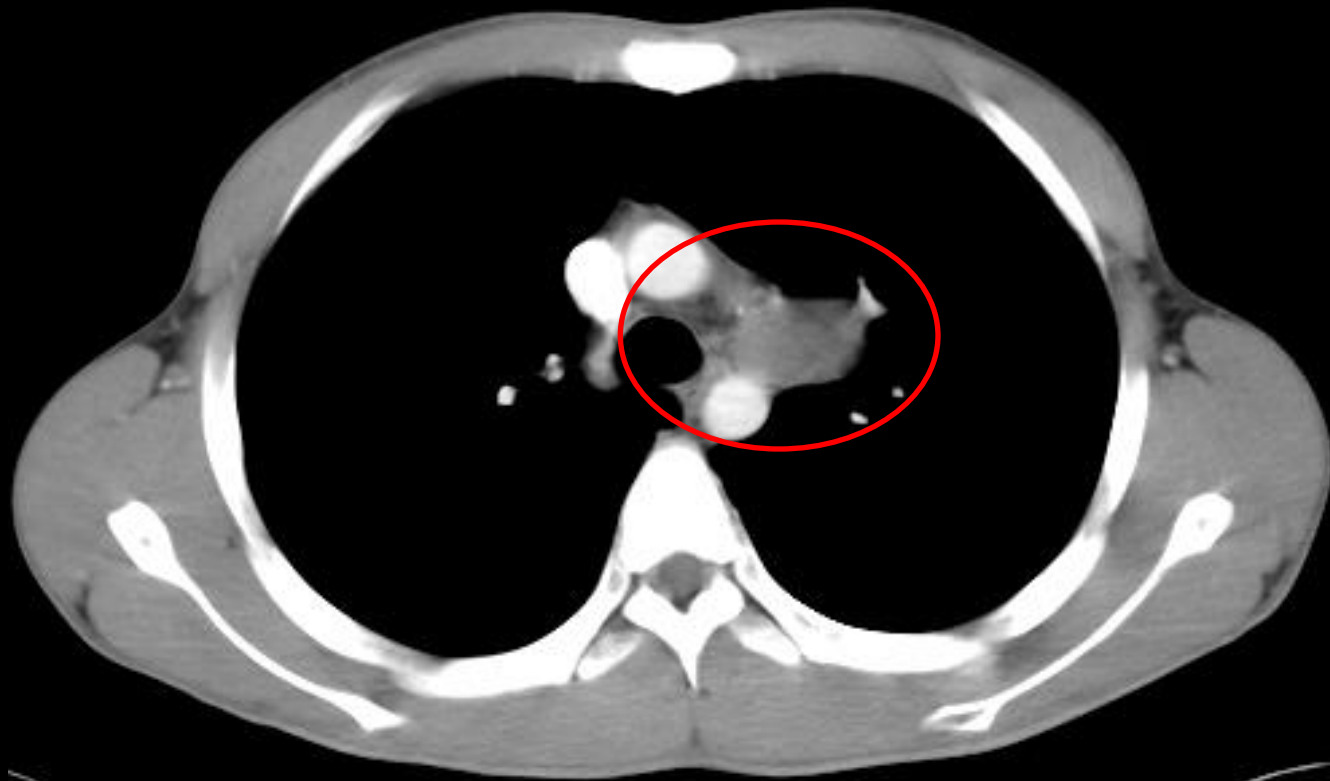
A



B

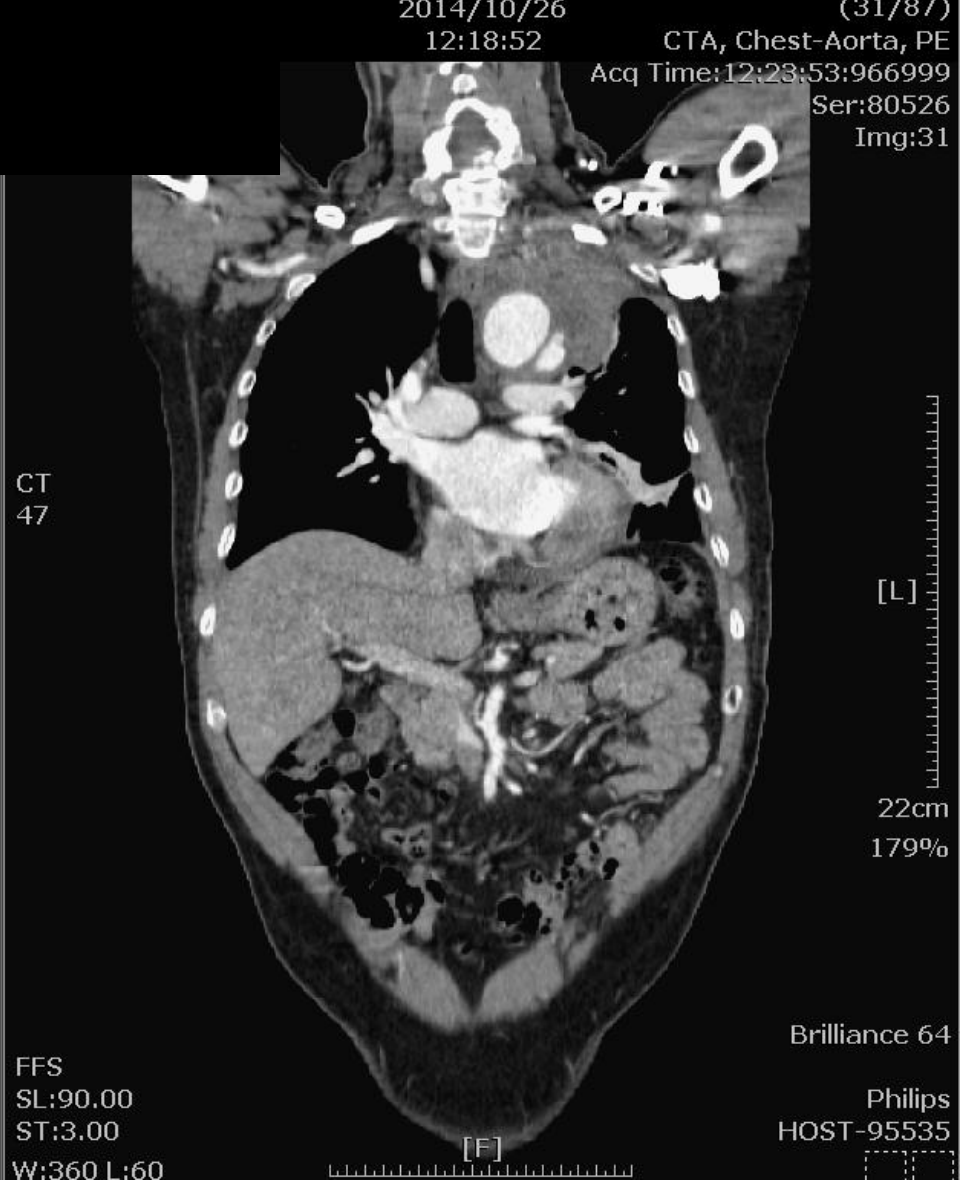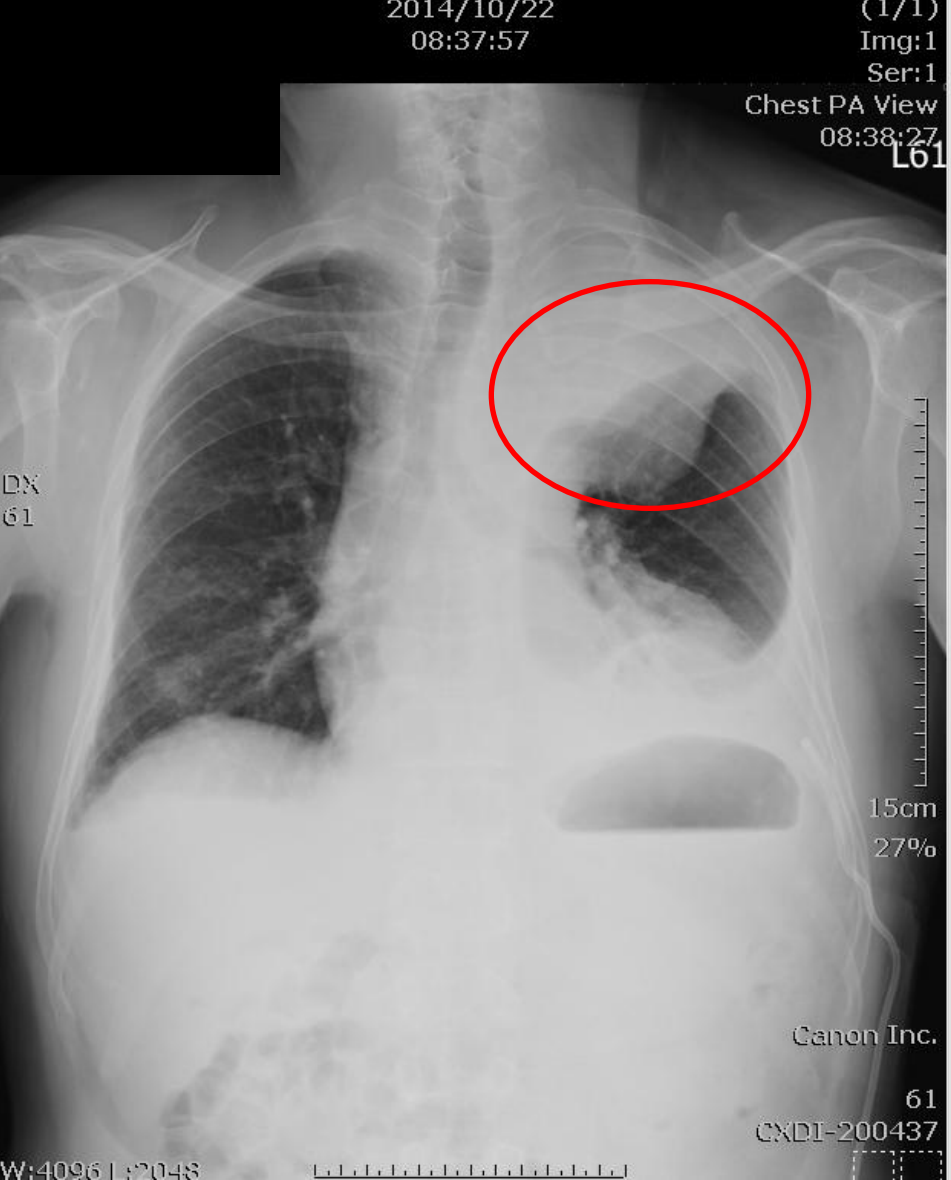




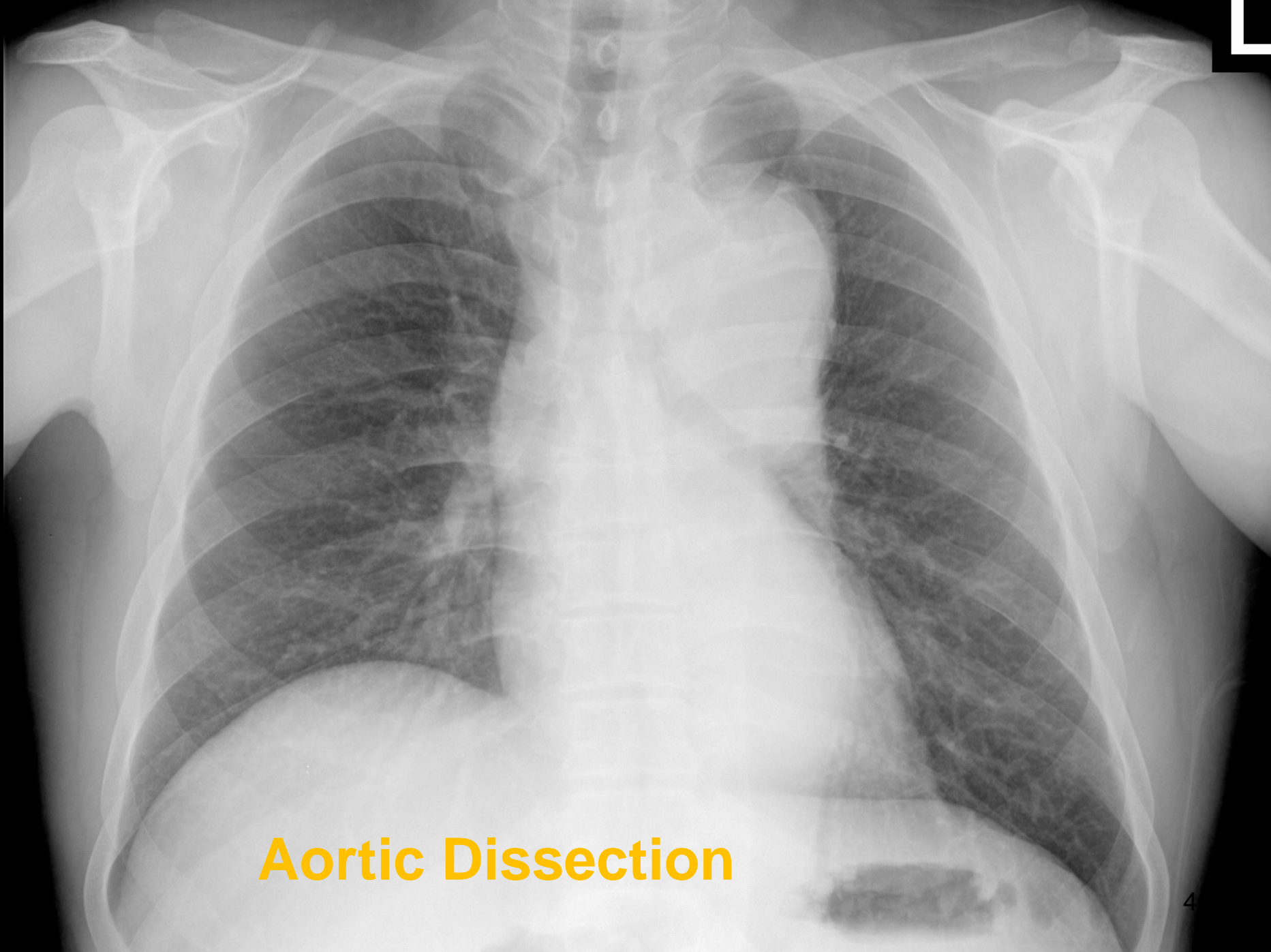


Vascular middle mediastinal disorders

- ****Aortic aneurysm (mycotic aneurysm)**
- Aortic dissection
- Penetrating atherosclerosis aortic ulcer
- Aortic intramural hematoma
- Traumatic aortic rupture
- Enlargement of the main pulmonary artery
- SVC obstruction

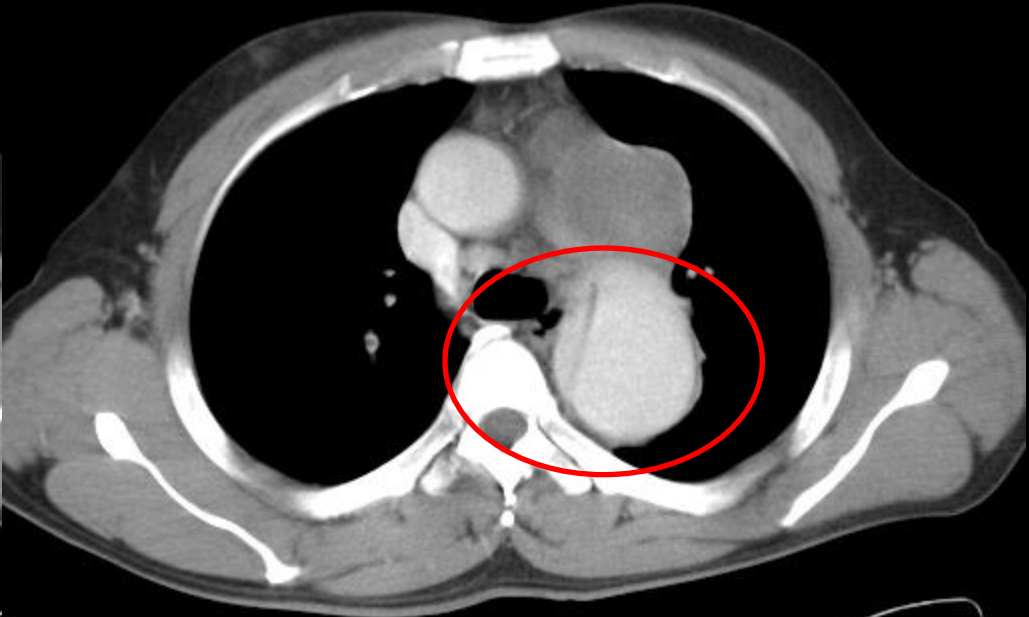
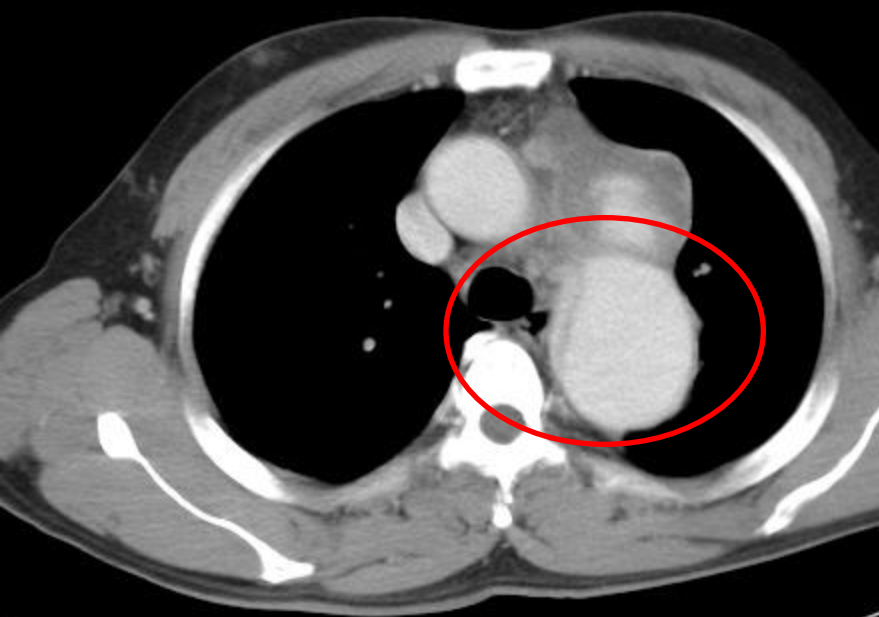


Middle mediastinum mass + hemothorax _ Penetrating aortic ulcer



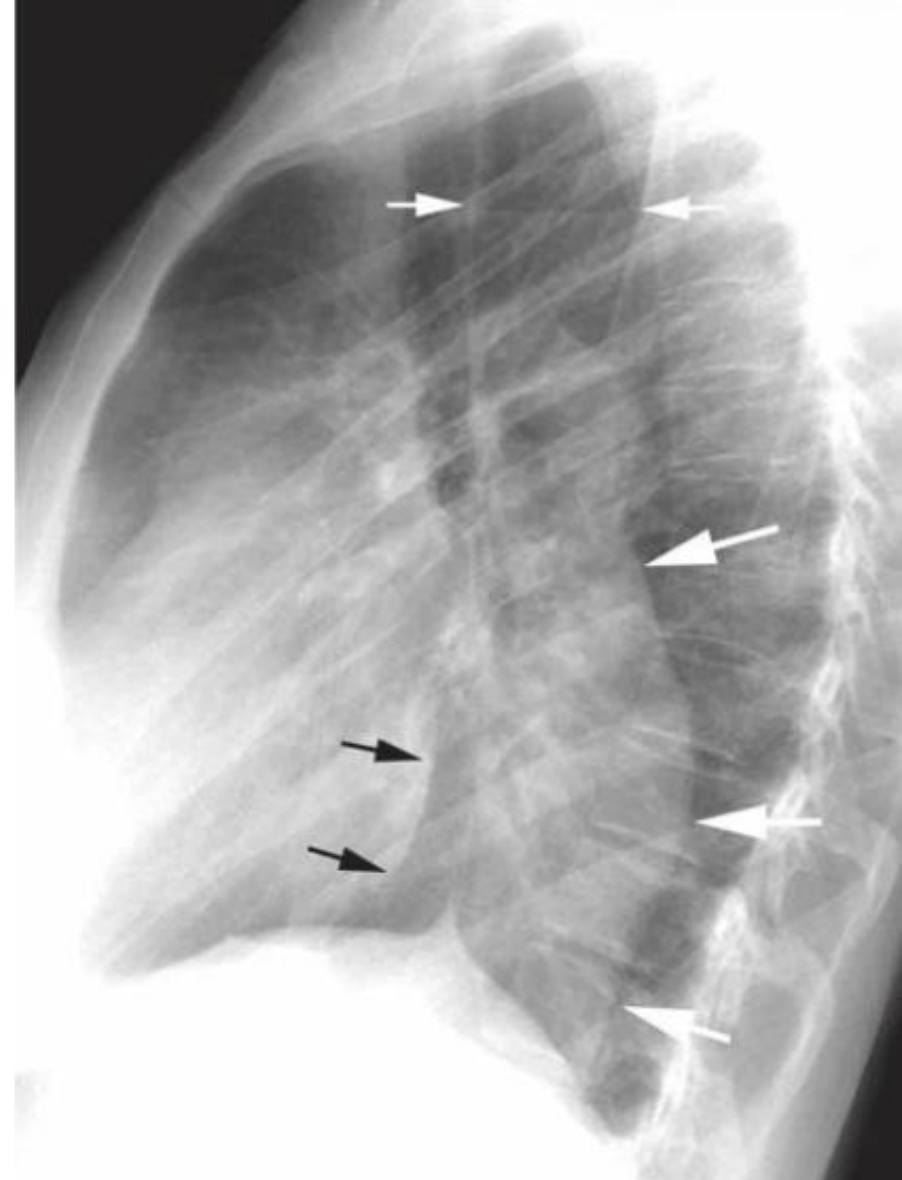
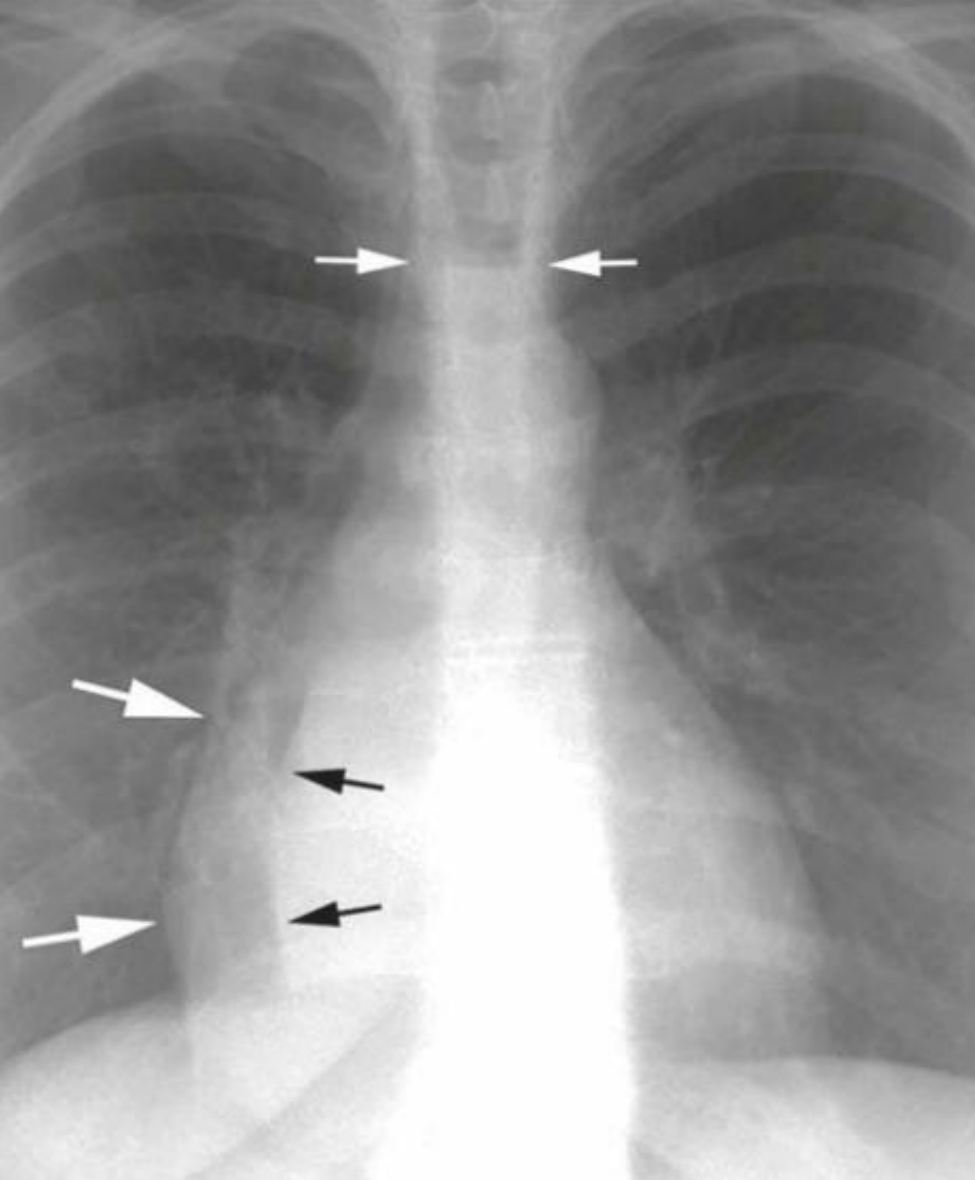
L

Aortic Dissection



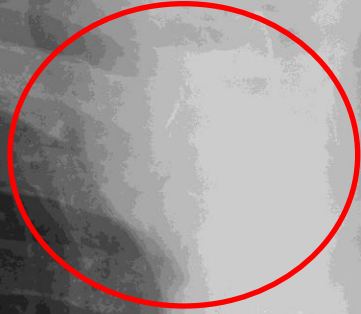Esophageal disease

- Esophageal neoplasm: esophageal ca, gastrointestinal stromal tumors
- Diverticula
- Dilation: achalasia, scleroderma, reconstruction
- Tracheoesophageal fistula
- Perforation & mediastinitis
- Hiatal hernia

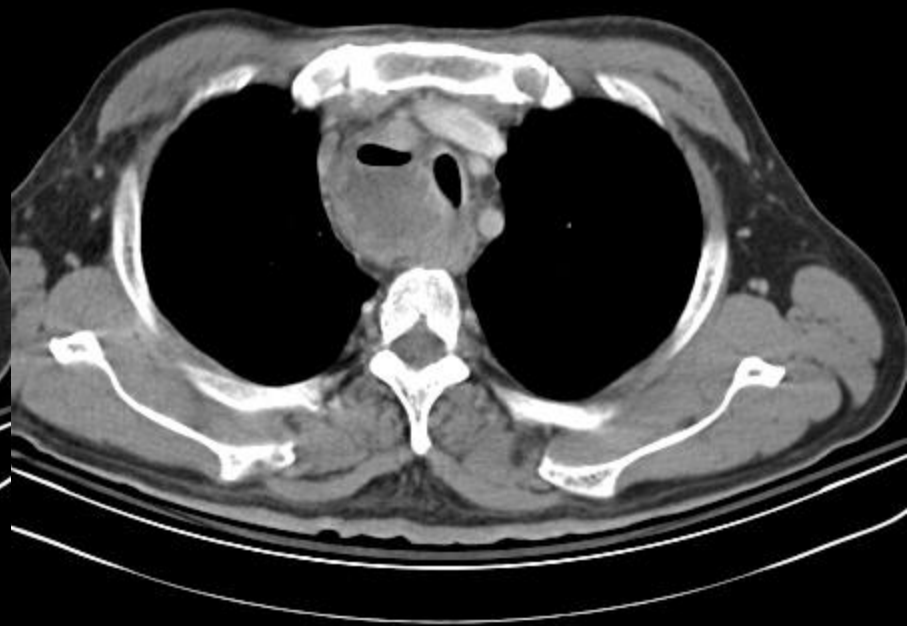
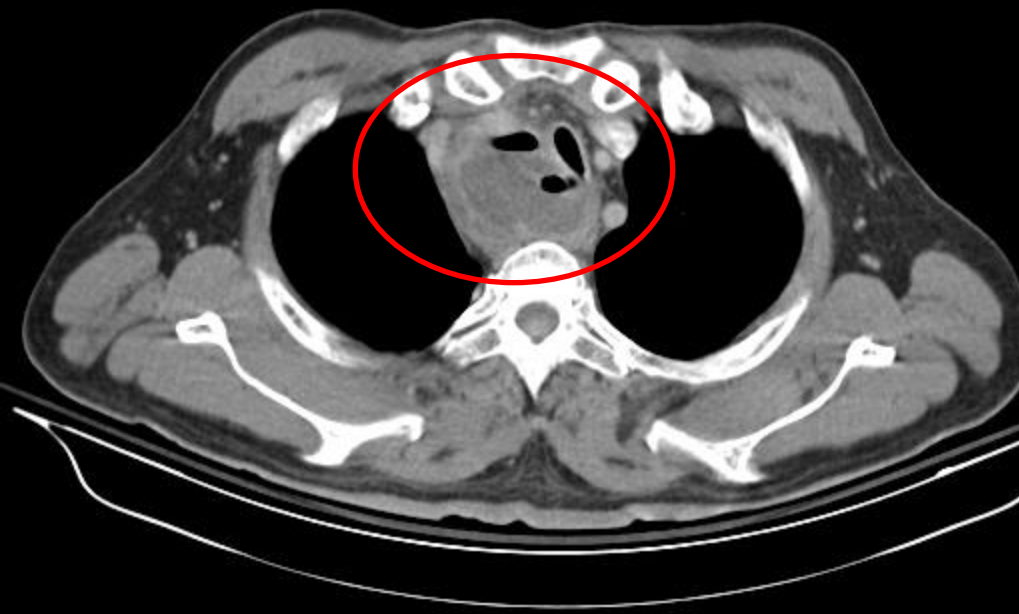


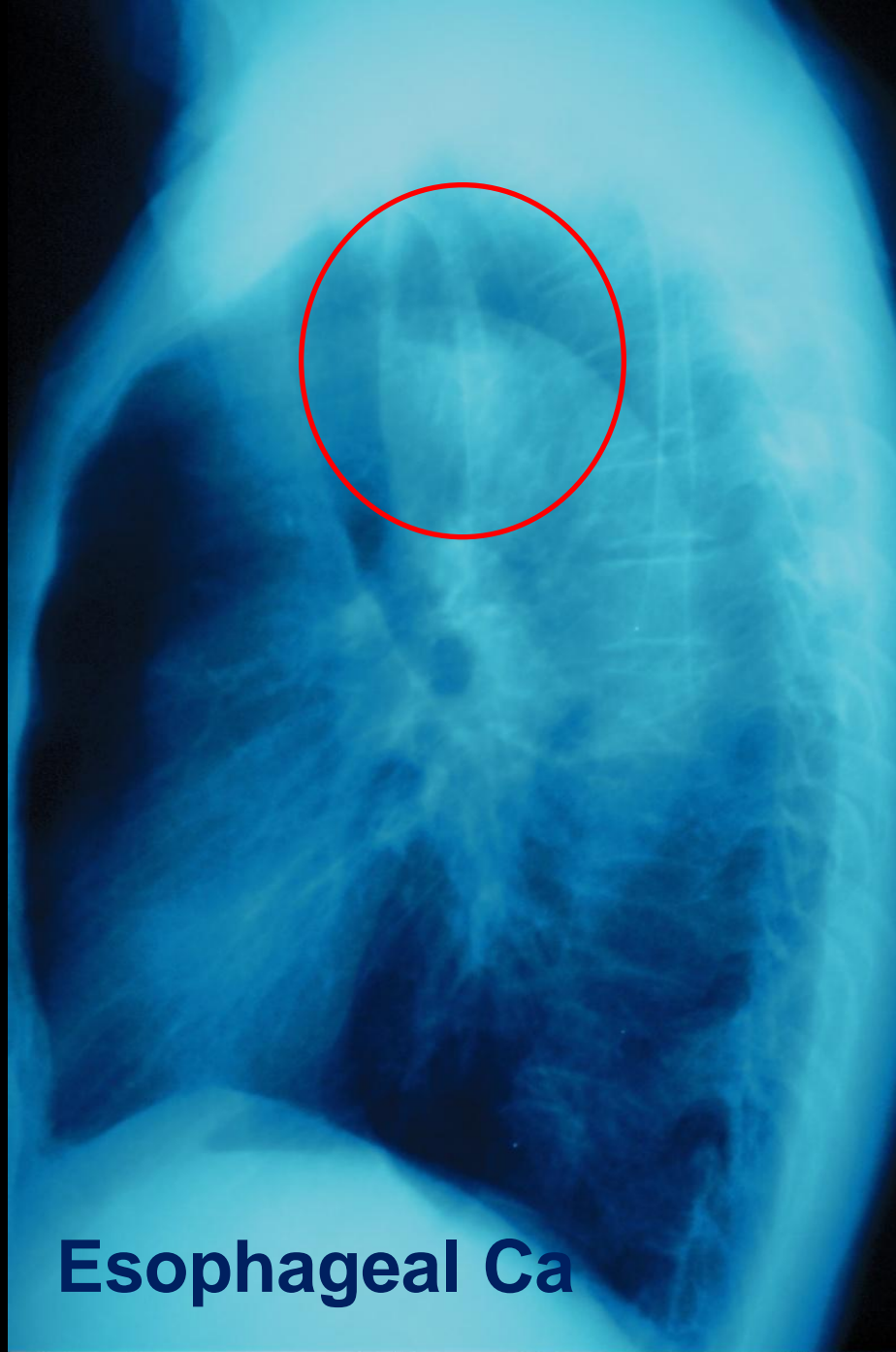
Air-fluid level and dilated esophagus _ Achalasia

L5

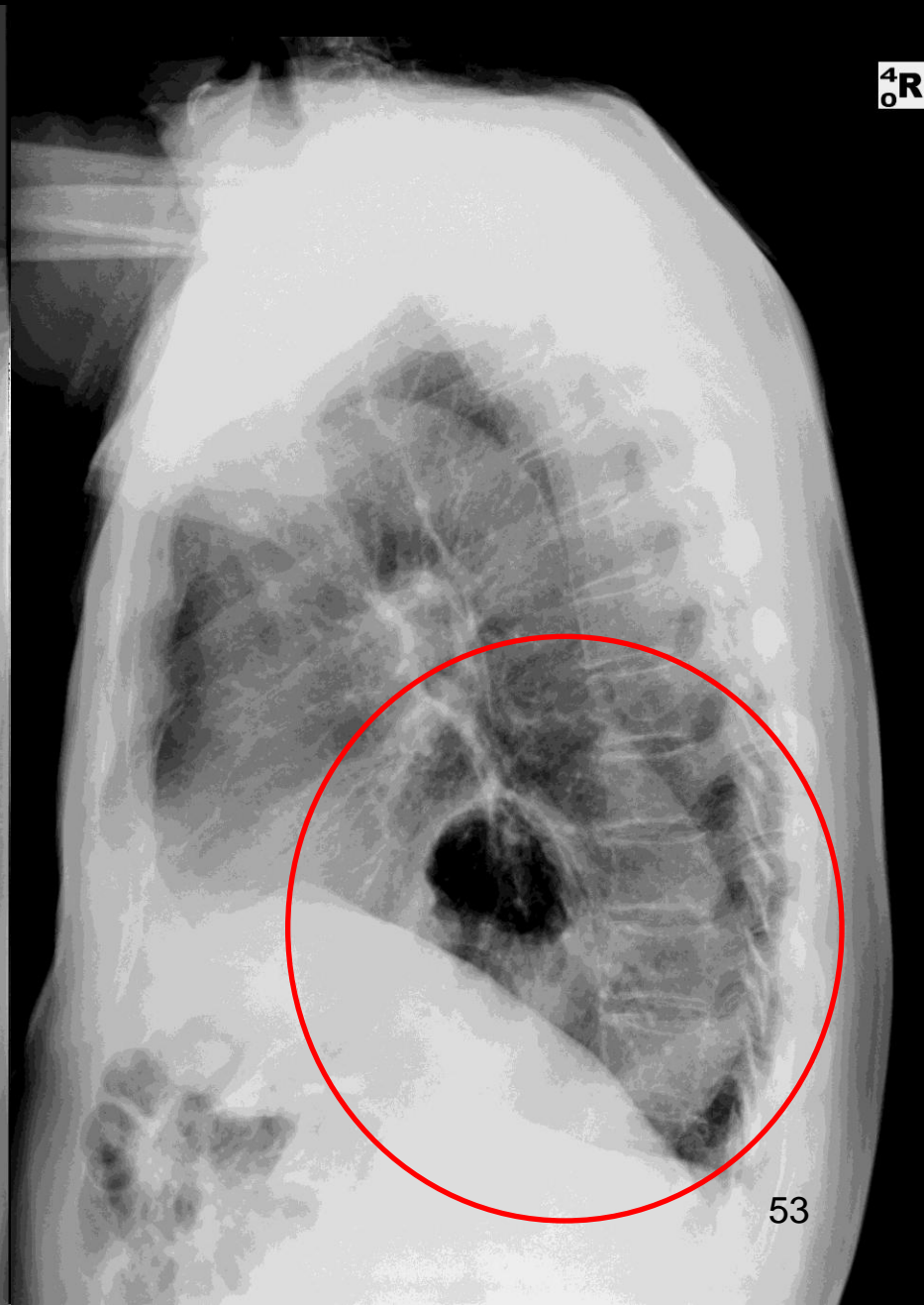
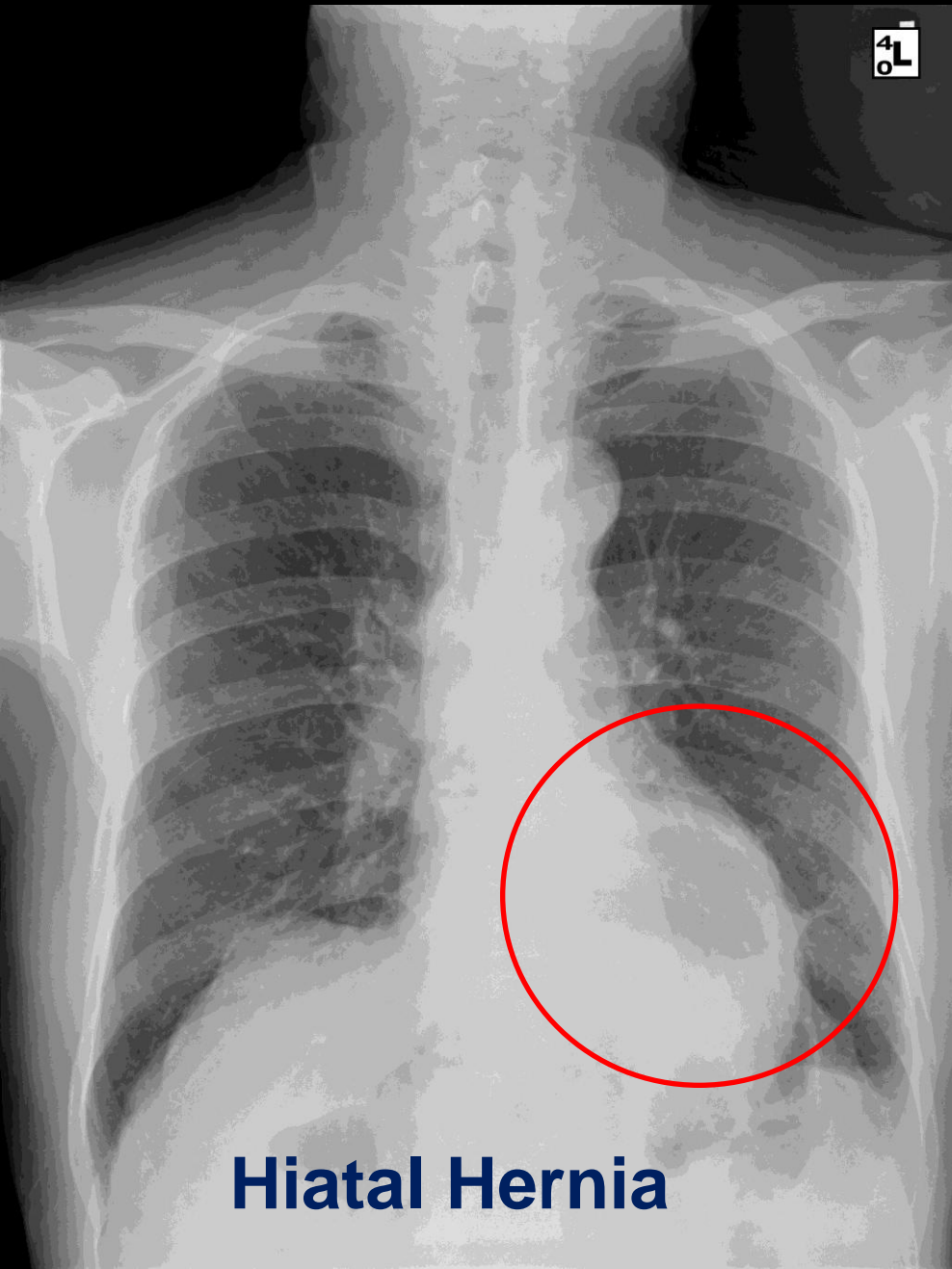


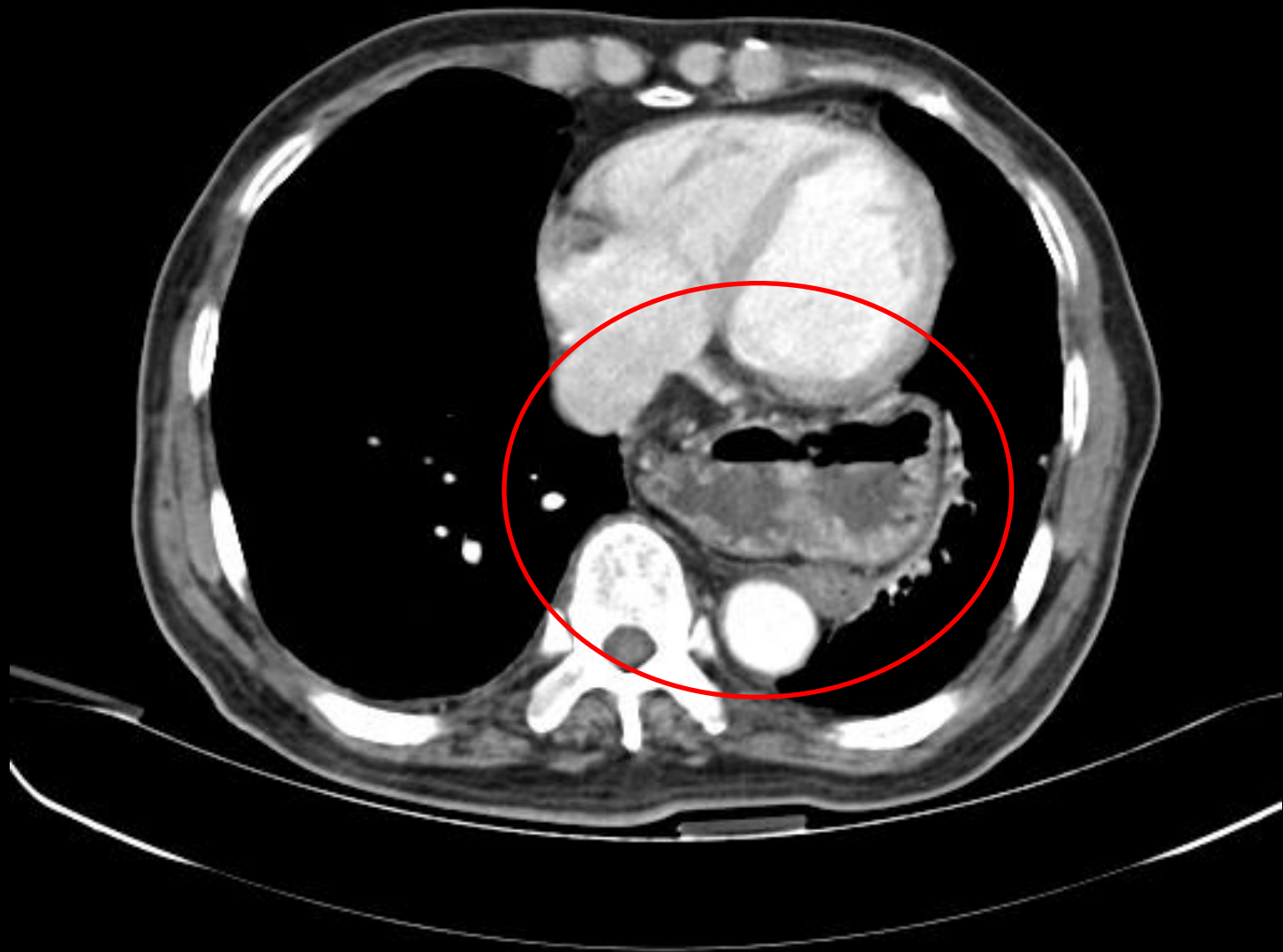
Paraesophageal abscess





Esophageal Ca

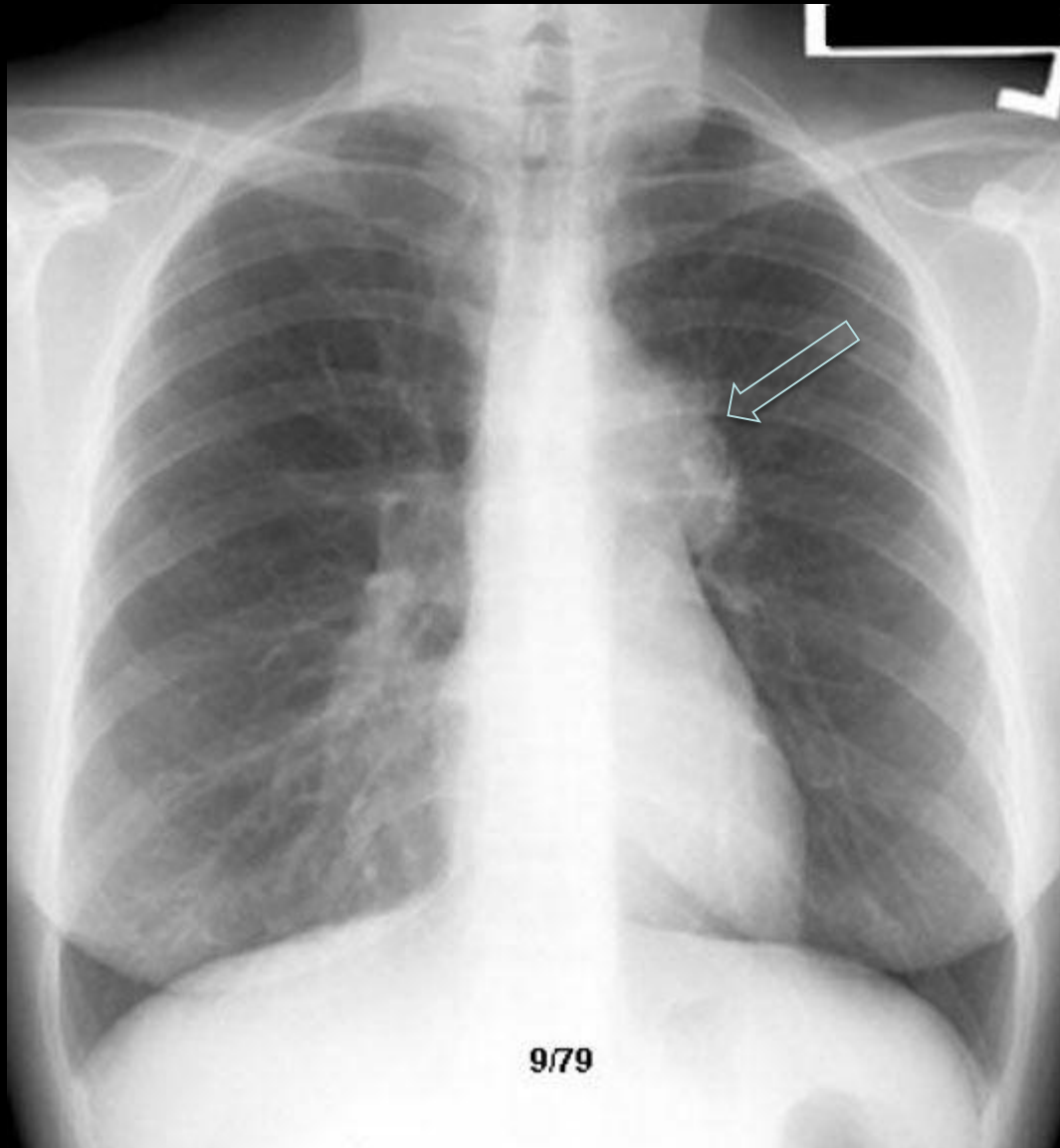




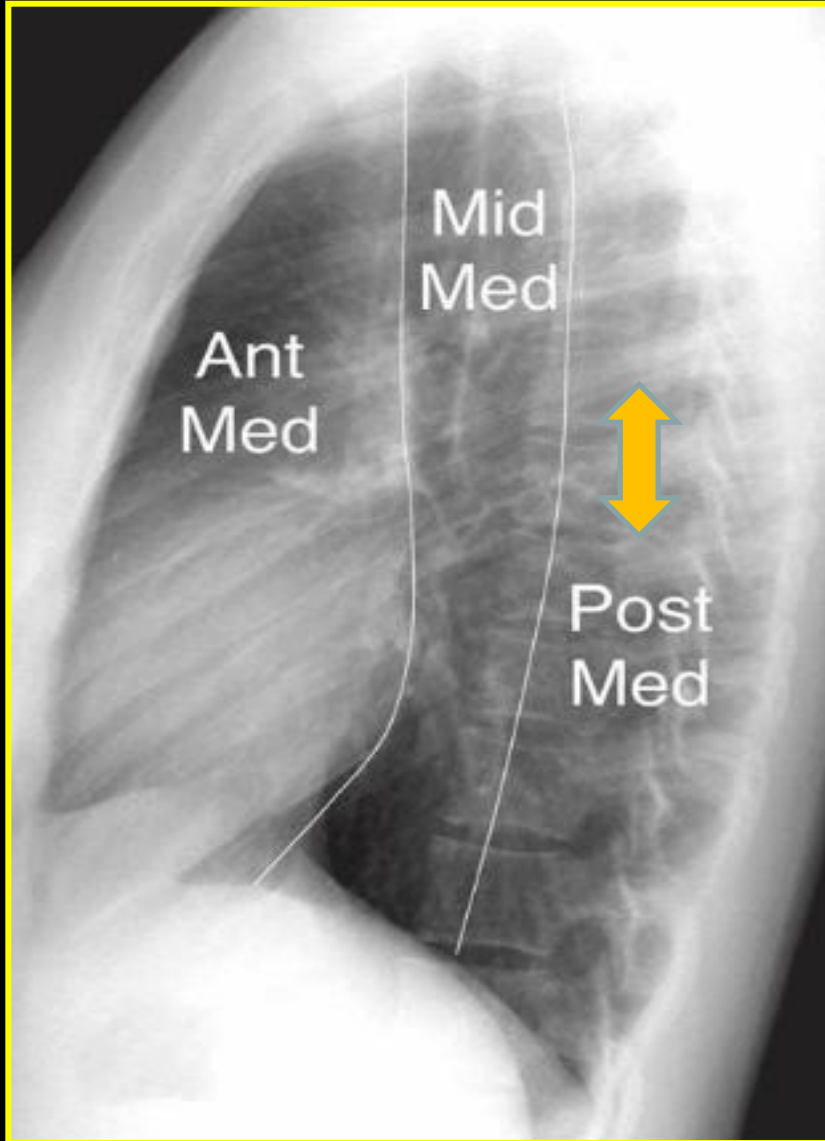
Lymphadenopathy

- Neoplastic : most common lung ca
 - 很少產生 calcification , 除了:
 - Osteogenic sarcoma (OGS)
 - Hodgkin' s lymphoma s/p R/T
- Infection / Inflammatory : TB, sarcoidosis
- Inhalational

Small cell lung cancer with hilar lymphadenopathy



Posterior mediastinum

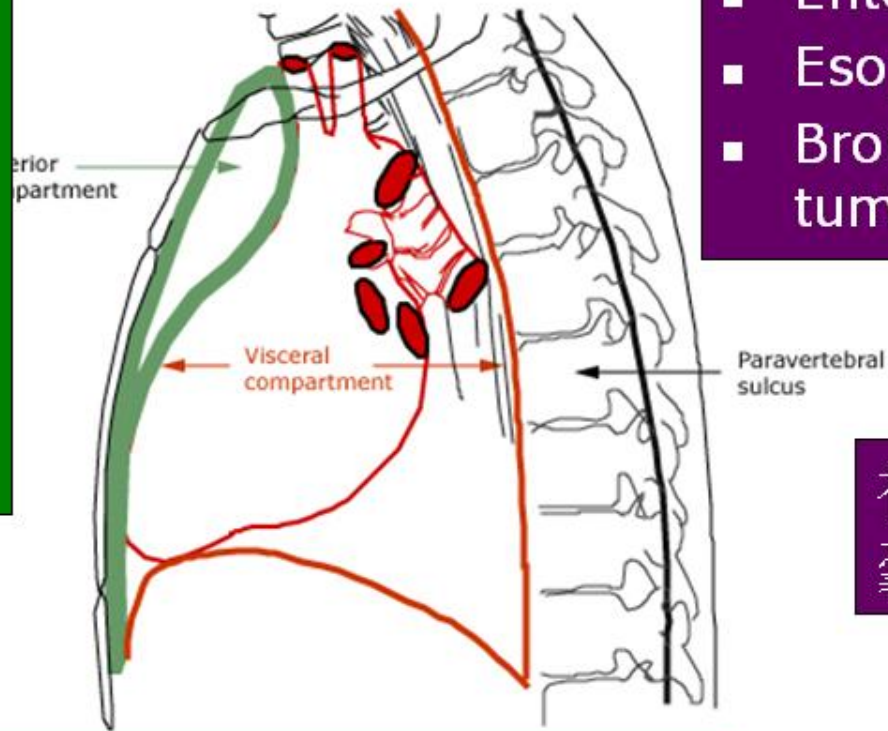


- 前邊界 : 1cm behind ant. vertebral column
- 後邊界 : chest wall
- 上邊界 : thoracic inlet
- 下邊界 : diaphragm
- 內容物:
vertebral body, paravertebral tissues,
descending aorta, azygos vein, lymph nodes
- 相關特徵:
paravertebral stripes

前縱膈腔

- Intrathoracic Goiter
- Parathyroid tumor
- Esophageal tumor
- Angiomatous tumor
- Teratoma
- Thymoma
- Pericardial cyst
- Terrible Lymphoma
- Morgagni hernia
- Lipoma

← 4 T



後縱膈腔

- Neurogenic tumor
- Aneurysm
- Enteric cyst
- Esophageal tumor
- Bronchogenic tumor



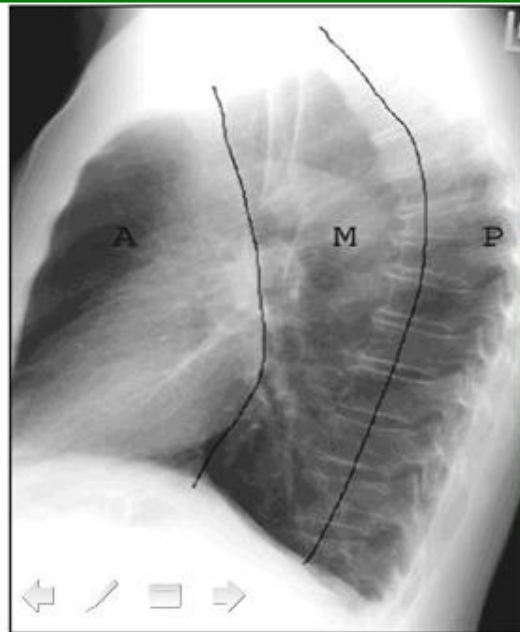
神經性腫瘤
囊腫, 動脈瘤

中縱膈腔

- Lymphoma
- Lymph node hyperplasia
- Bronchogenic tumor
- Bronchogenic cyst

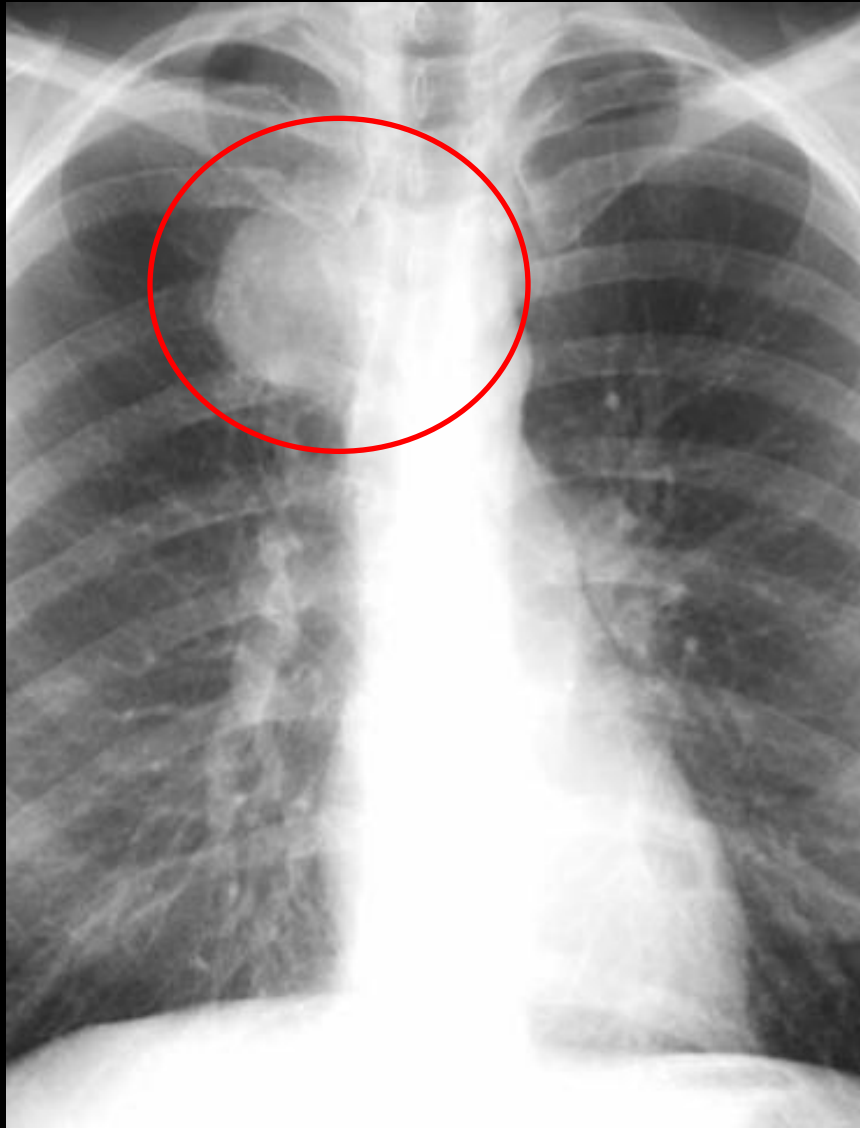


淋巴疾病及
縱膈囊腫

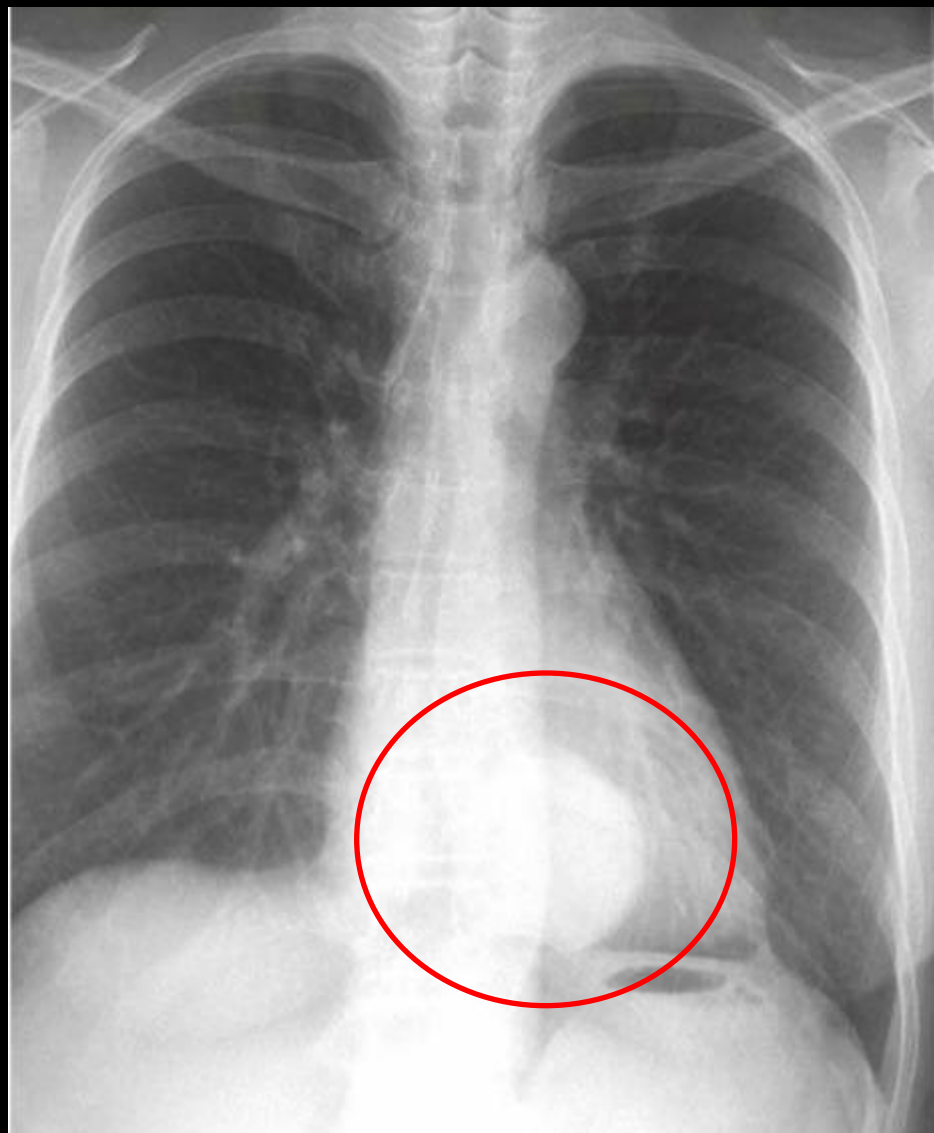


Neurogenic Tumors

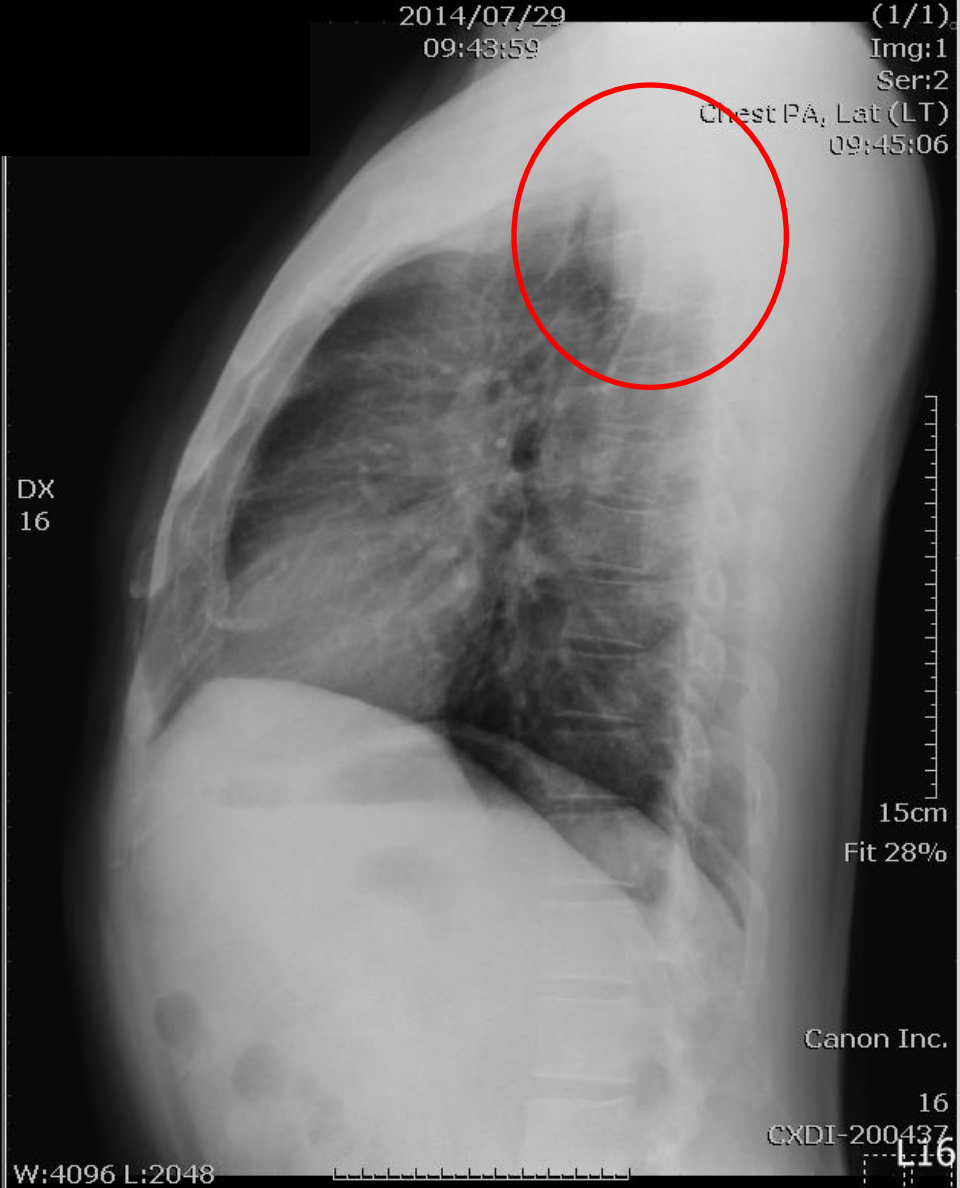
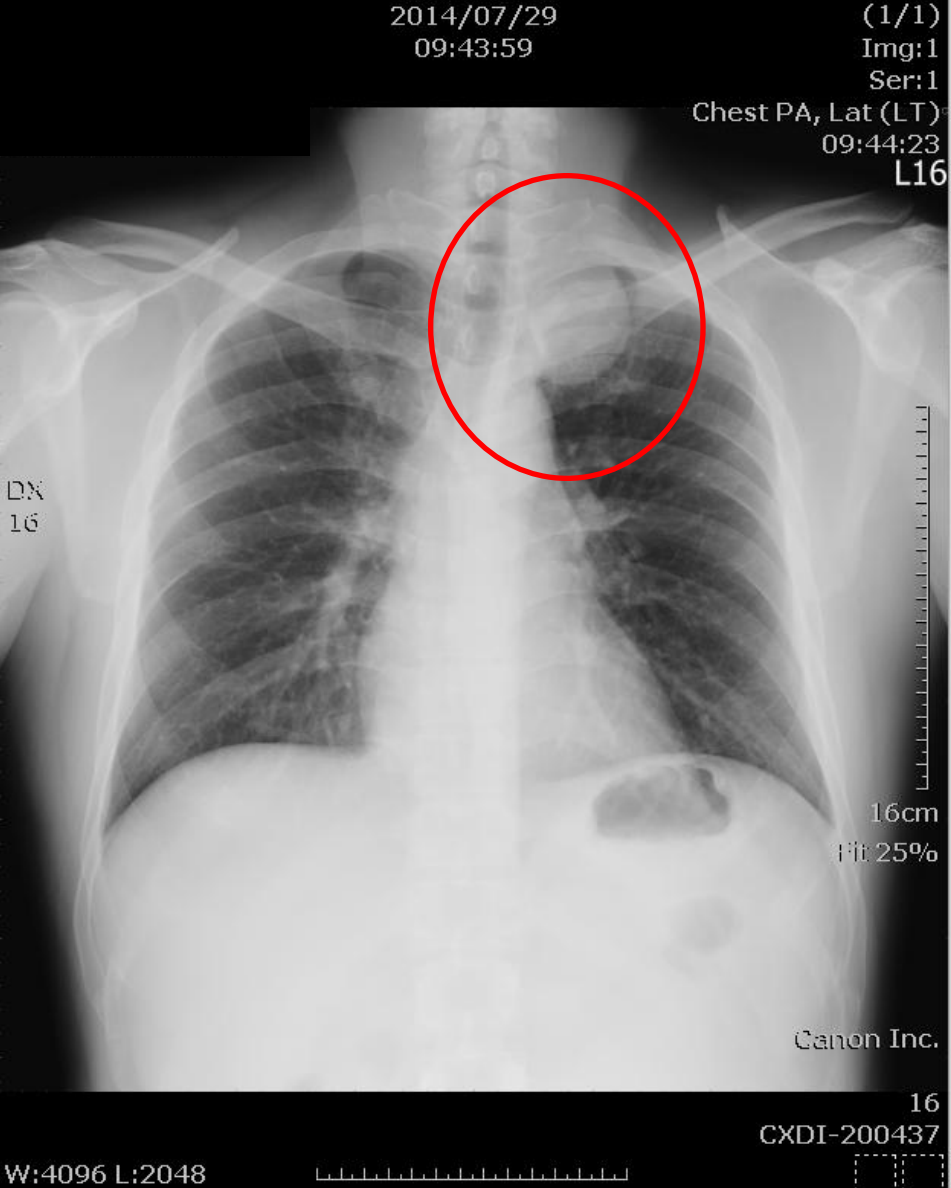
- Including schwannoma, neurofibroma, peripheral nerve sheath tumor
- **10~20%** primary mediastinal masses in adults
 - **75% posterior mediastinal** mass were neurogenic tumors
- CXR:
 - Round or elliptical (圓形或橢圓形), sharp-margined mass extending 1-2 rib interface (extent: <4 vertebral body)
 - Often centered at neural foramen
 - **Cervicothoracic sign**: air-soft tissue interface continues above clavicle indicating posterior location



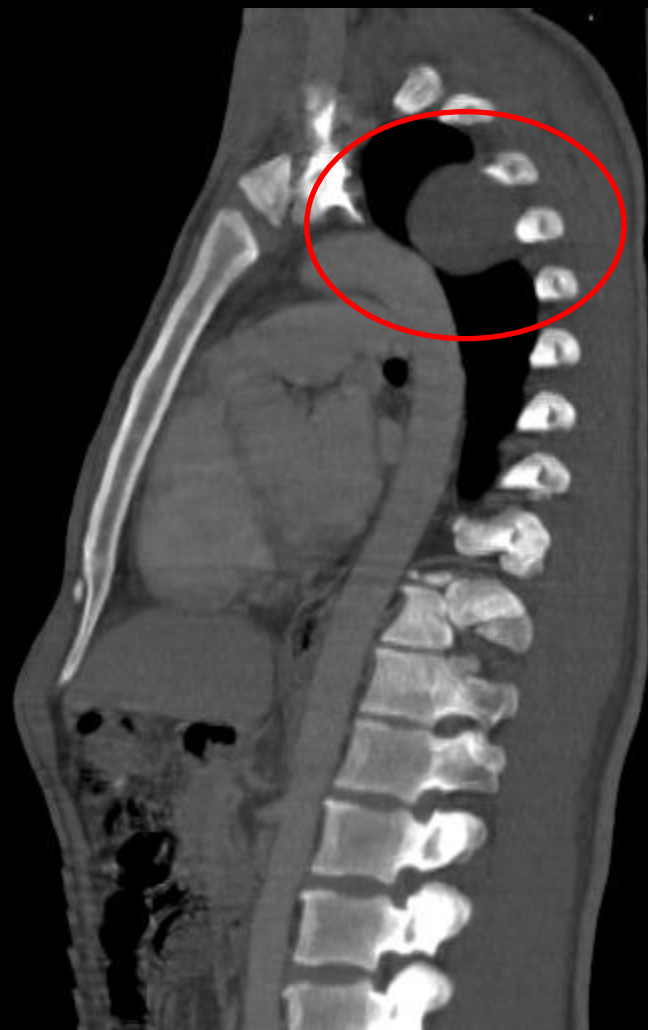
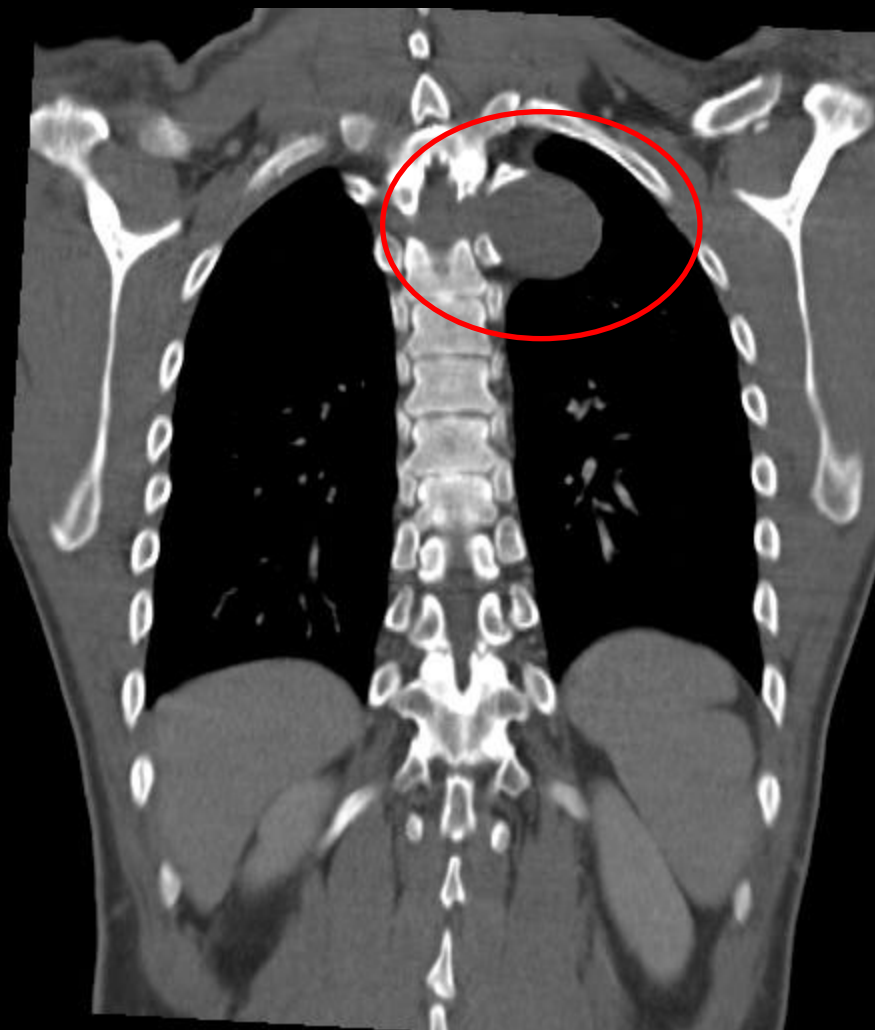
Schwannoma with right rib deformity



retrocardiac mediastinal mass, Schwannoma

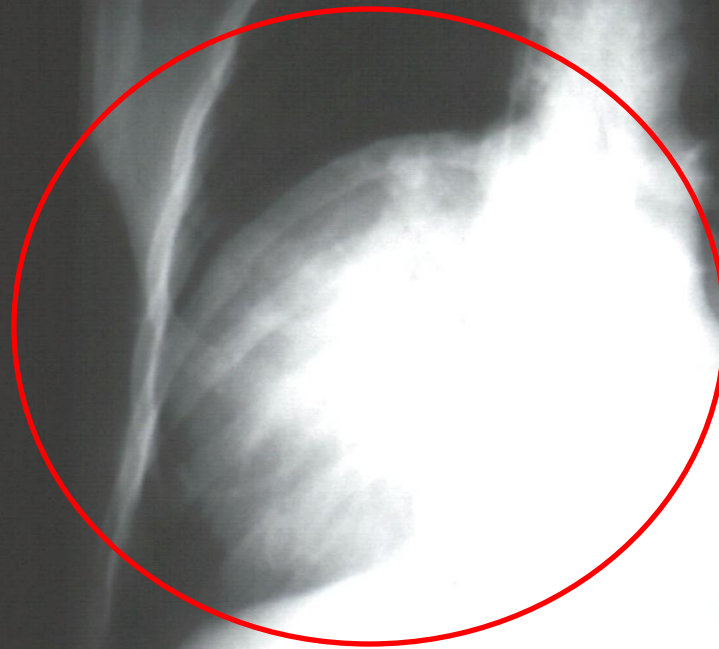
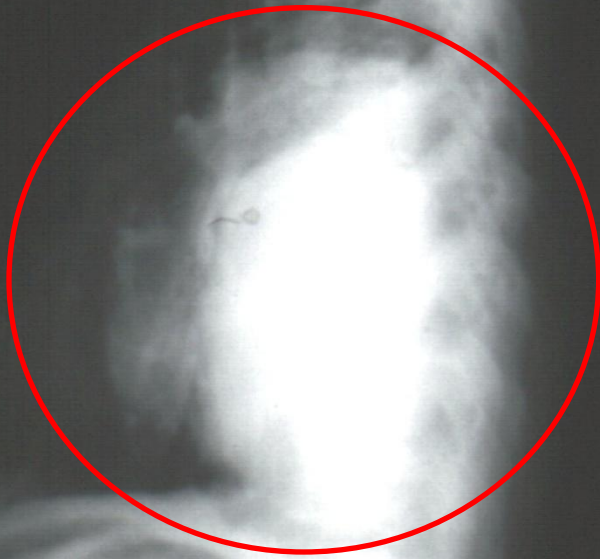

Posterior mediastinum tumor, Schwannoma



Extra-Medullary Hematopoiesis(EMH)

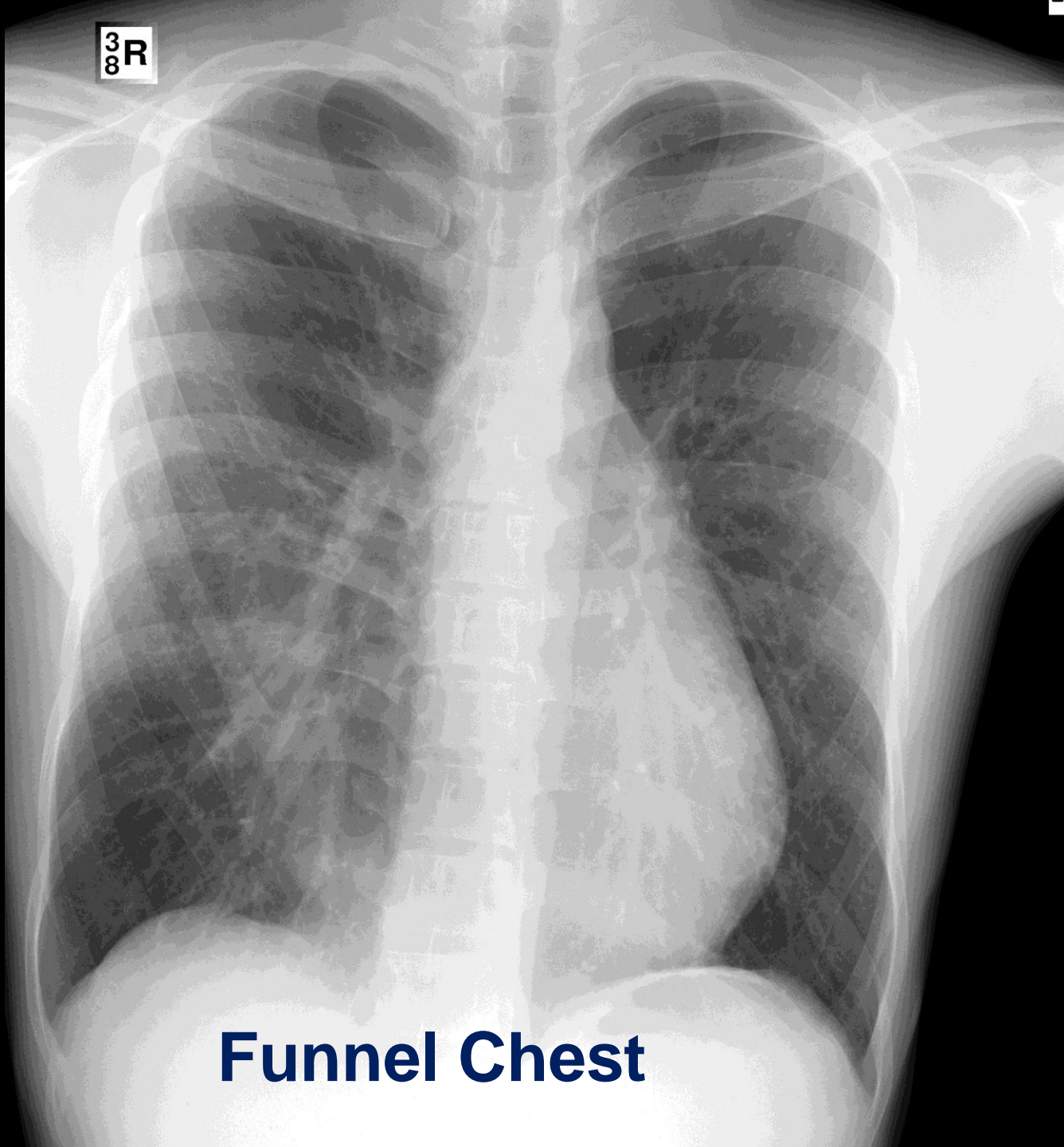
contrast CT, no CT biopsy



Chest Wall Lesions

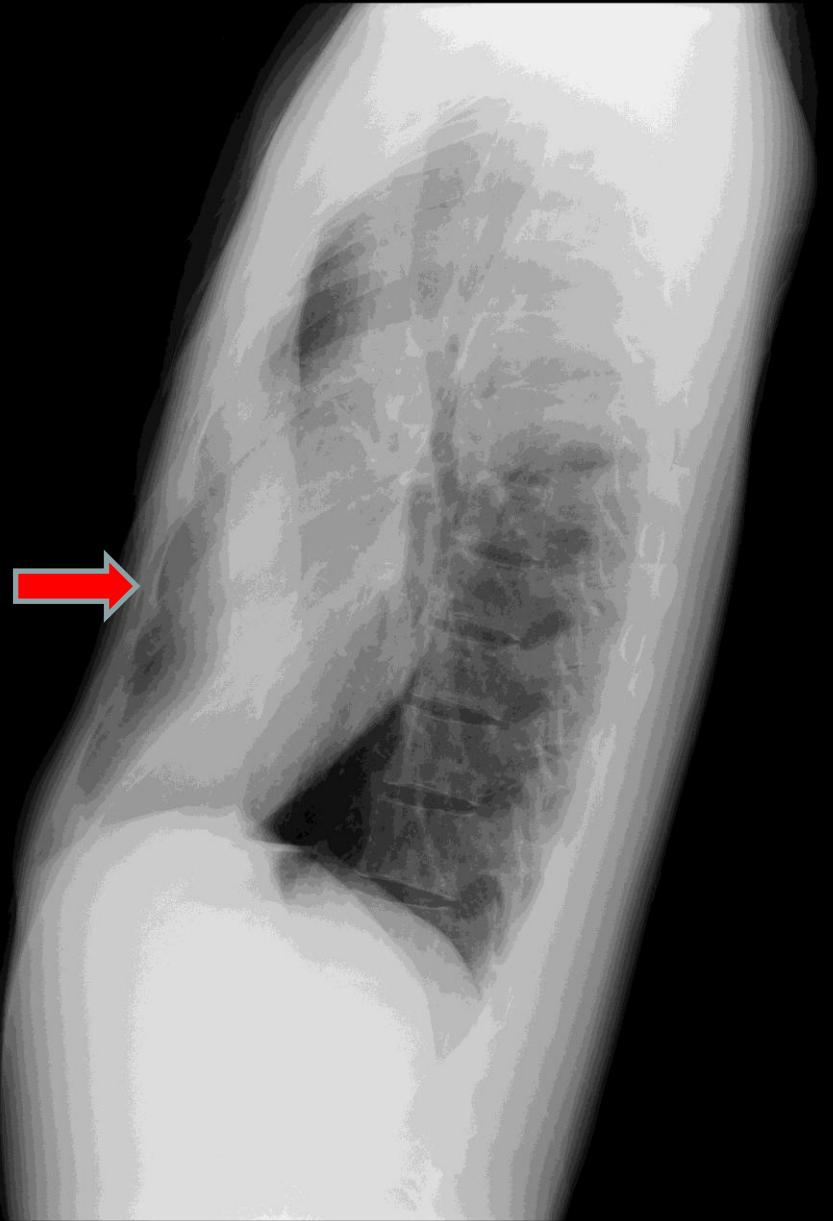
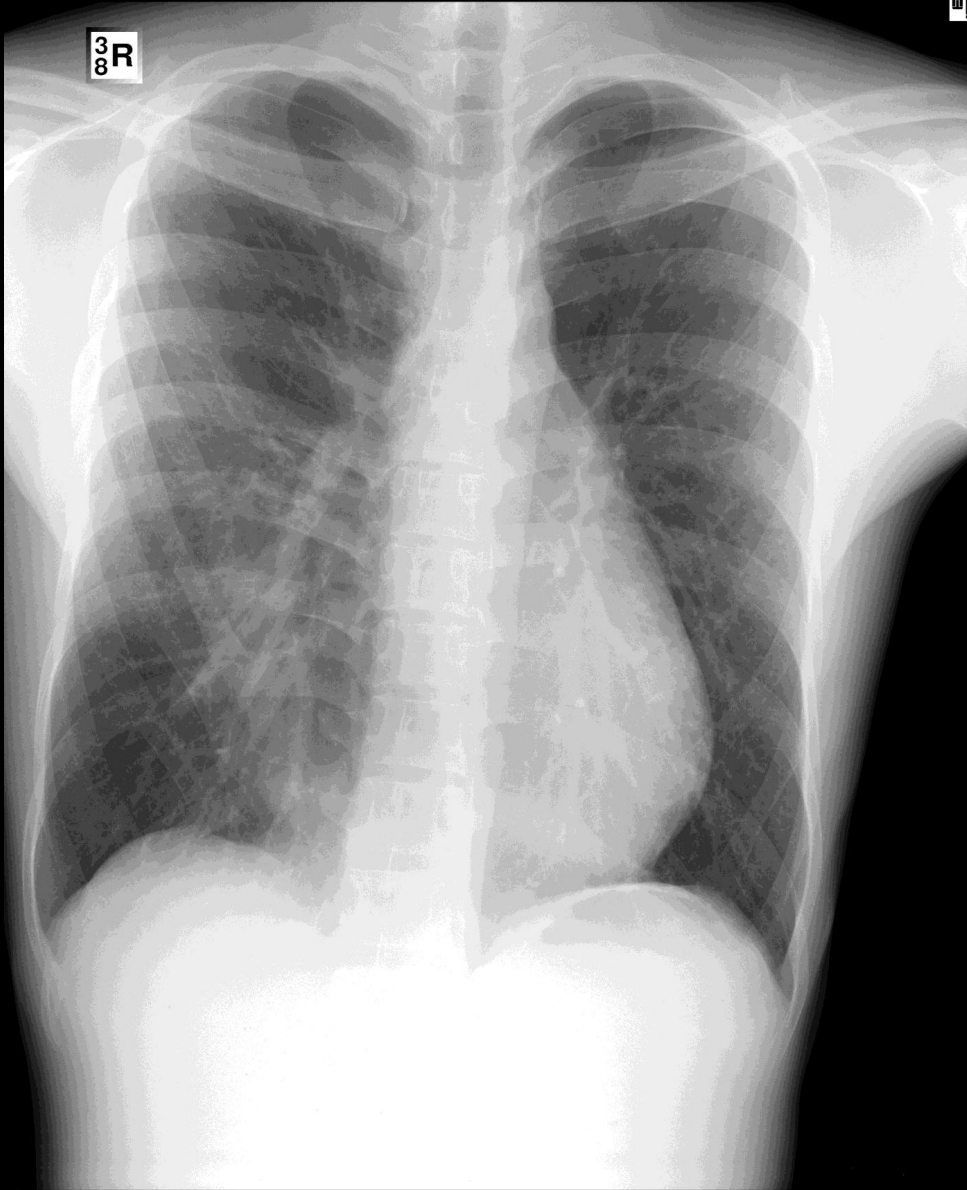
病灶的定位與辨別

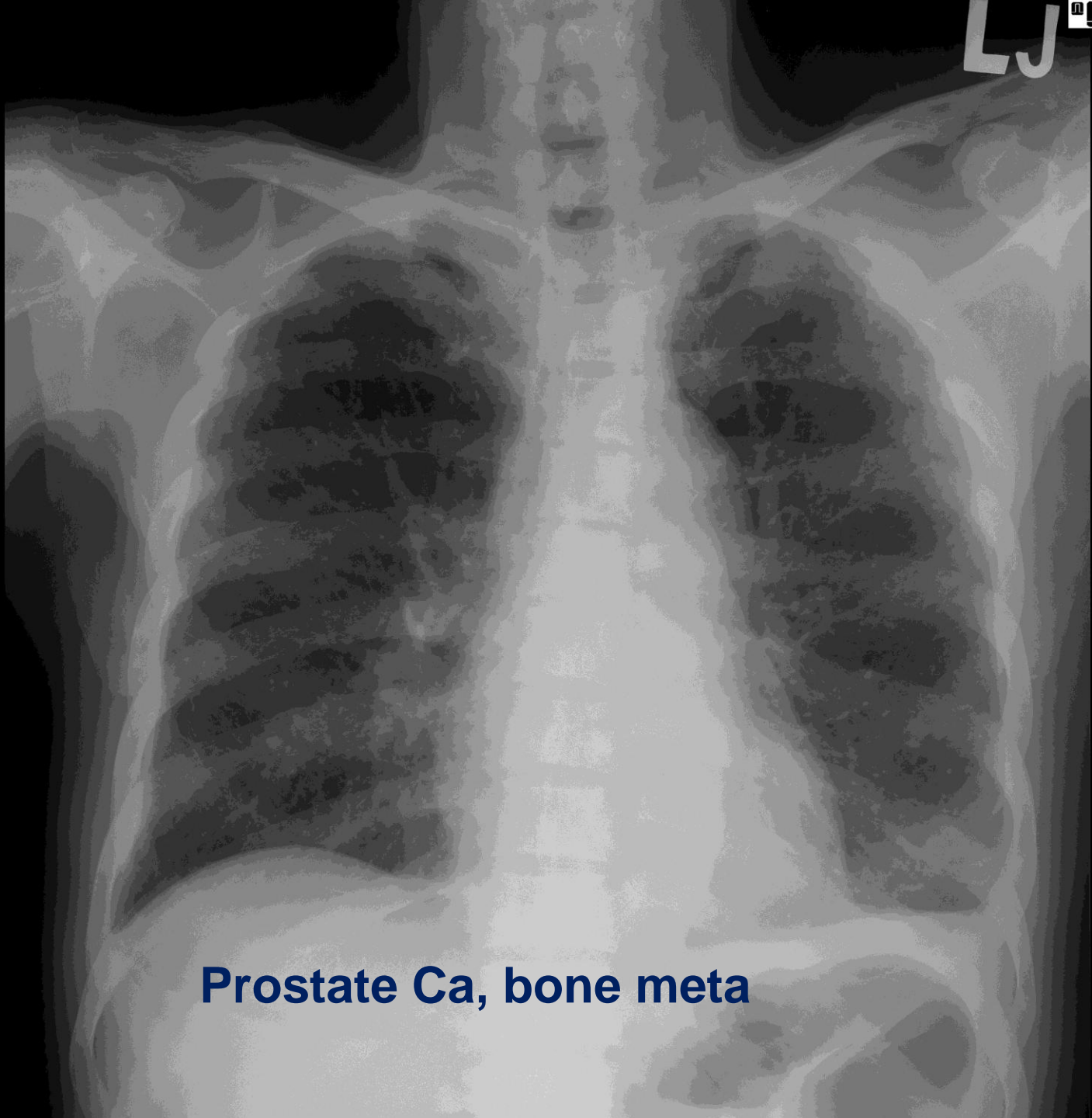
- 先判斷胸腔內或胸腔外 → lateral view、PE
- 胸腔外 (extra-thoracic)
 - Skin
 - Foreign body
- 胸腔內 (intra-thoracic)
 - 肺內 (intrapulmonary) : 肺實質病灶
 - 肺外 (extrapulmonary) : pleura, chest wall (bone, soft tissue)



3
8 R

Funnel Chest



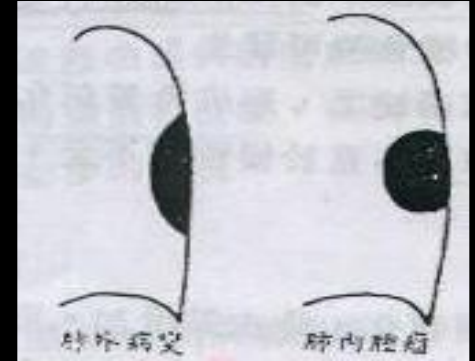


Prostate Ca, bone meta

Intrapulmonary vs. Extrapulmonary

- Incomplete border sign
- Tapered margin sign
- Center outside the lung
- Bilateral lesion

胸腔病灶線索 (位置、位移)

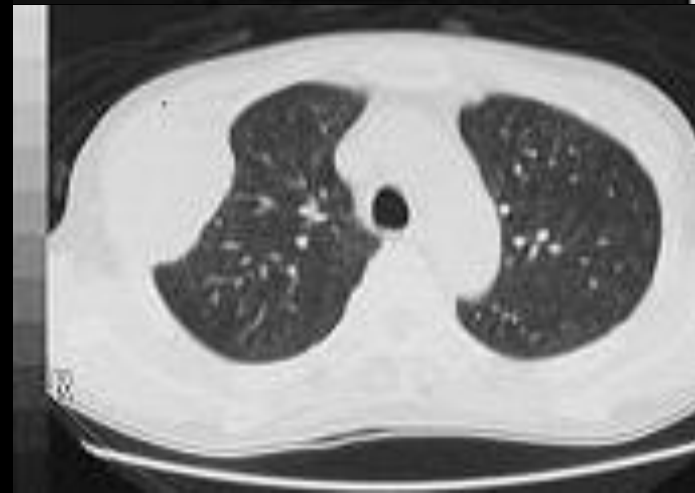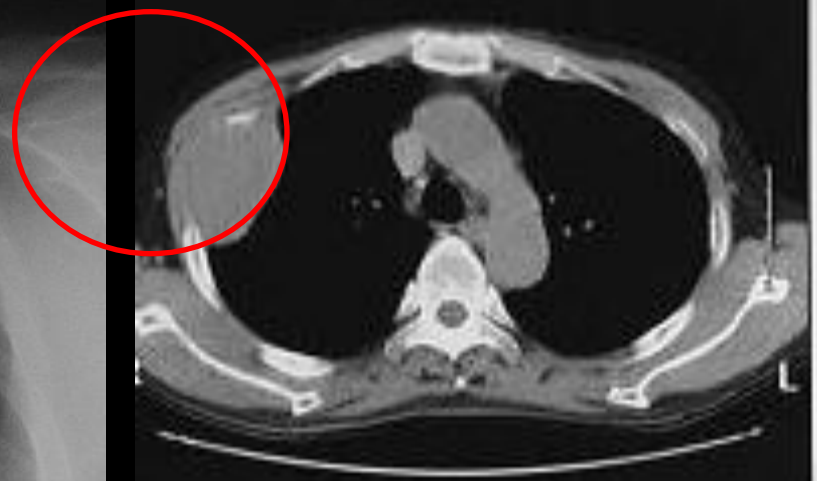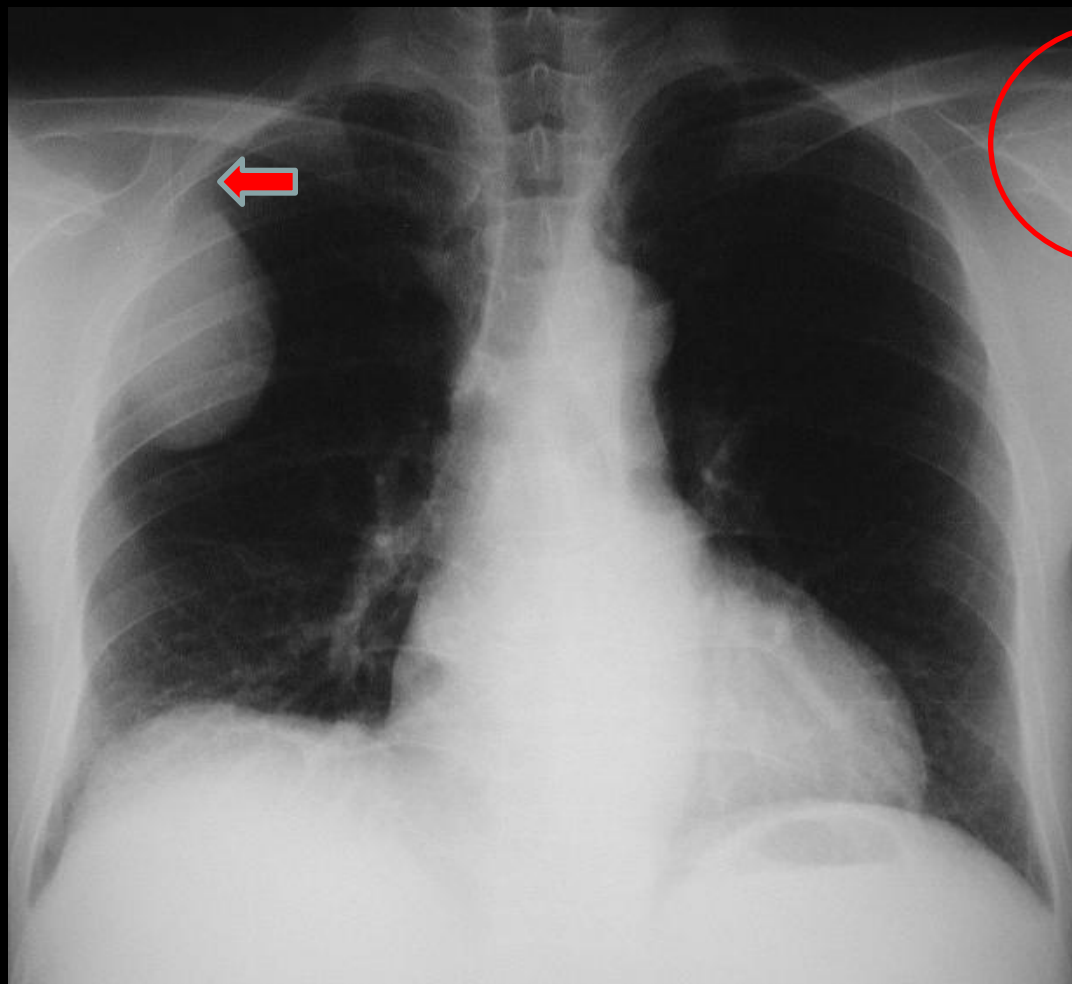


• Extrapleural Signs

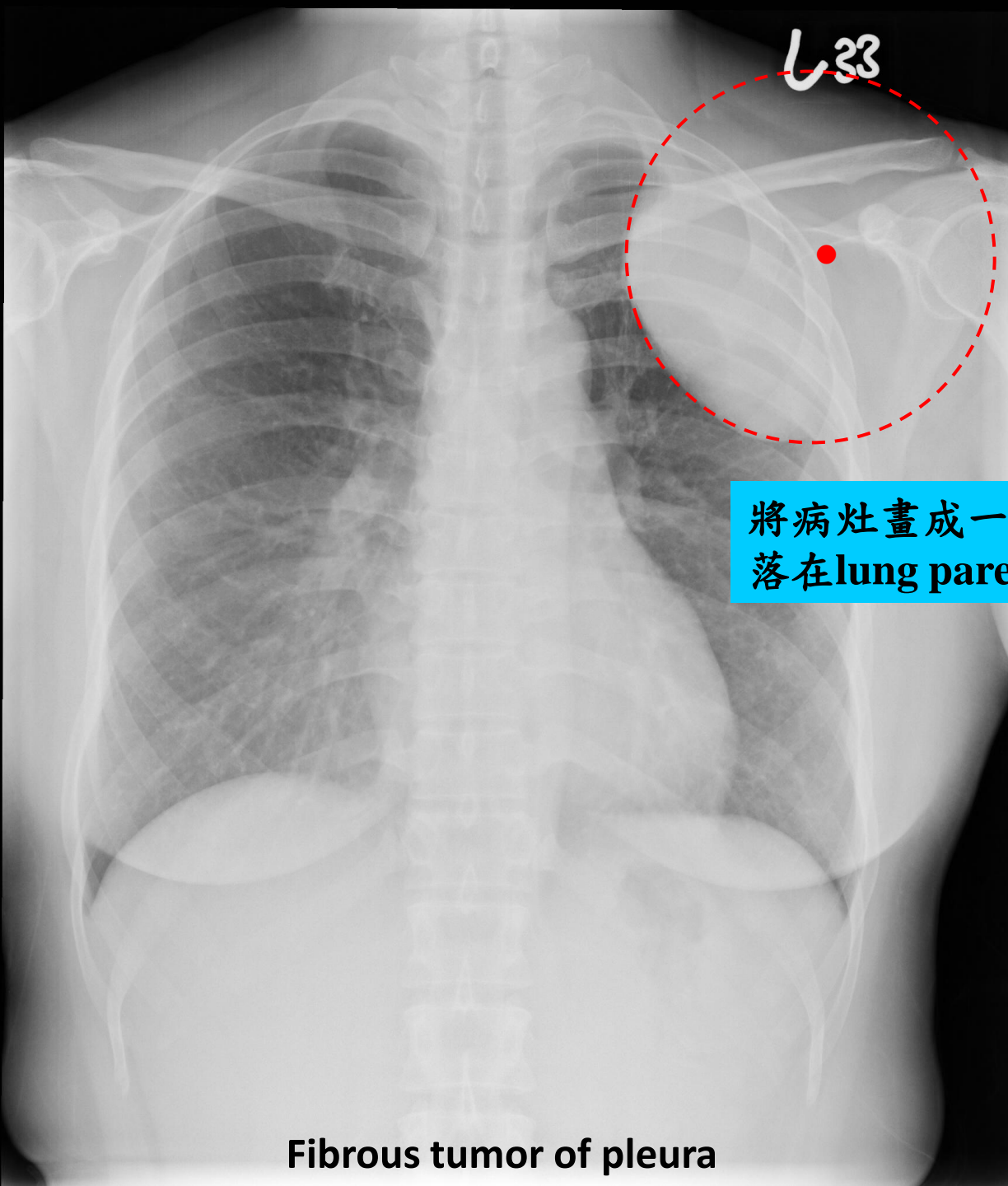
- 病灶位於**周邊**
- 病灶的convex border**朝著肺部**
- 病灶外緣(與肺部交界面)**邊緣清晰 (incomplete border sign)**
- 病灶基部較寬或是與縱隔/胸廓/橫膈的**交角是鈍角**
- 病灶有**air-bronchogram sign**可確定是位於**肺內**

• Mediastinal line deviation

Incomplete border sign (邊緣)



- 用以區別 intrathoracic (胸腔內) - 肺內/肺外
- 內緣清楚而外緣不清，指向肺外的病兆 (join to the chest wall)
- Not aid in distinguishing 胸腔外 vs. 胸腔內



將病灶畫成一個圓，圓心
落在lung parenchyma之外

Fibrous tumor of pleura

Pleural Lesions

- Pleural effusion
- Pleural mass
- Pleural thickening / calcification
- Pneumothorax

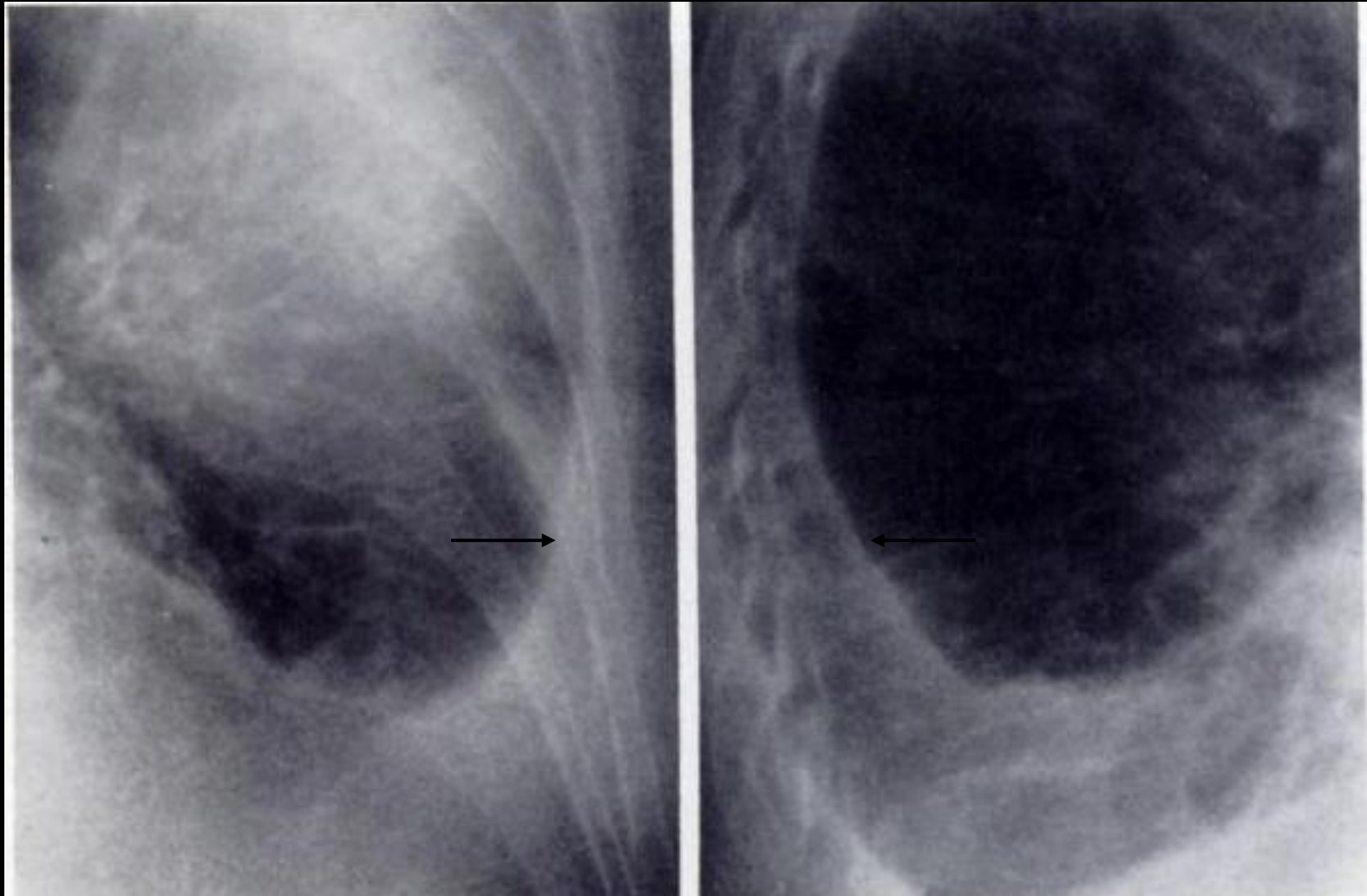
Pleural Effusion

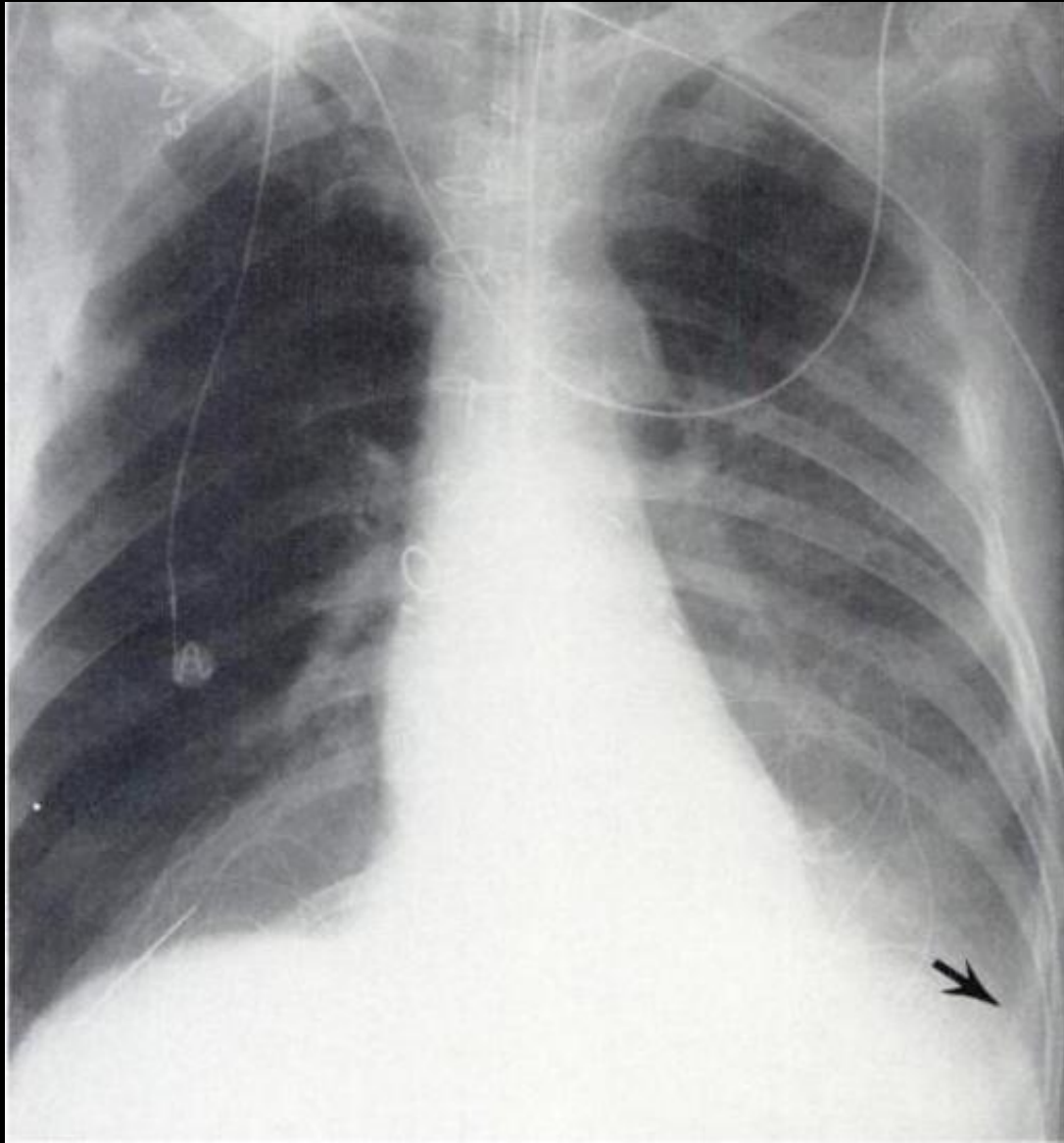
- Free pleural effusion
- Subpulmonic effusion
- Encapsulated pleural effusion
- Interlobar pleural effusion

Free Pleural Effusion

- Normally, 10-15cc in one pleural space
- 隨姿勢改變形狀
- PA view:
 - Lateral C-P angle or medial phrenicovertebral sulcus
 - Meniscus sign or angle blunting
 - 通常積水量 > 300cc
- Lat view:
 - Posterior CP angle blunting，積水量 > 150cc
 - More sensitive than PA view
- Supine view:
 - 由橫膈至肺尖呈現homogenous GGO (略有漸層)
 - 當lateral CP angle blunting時，積水量約500~1000cc
- Decubitus view:
 - Can detect PE less than 100cc

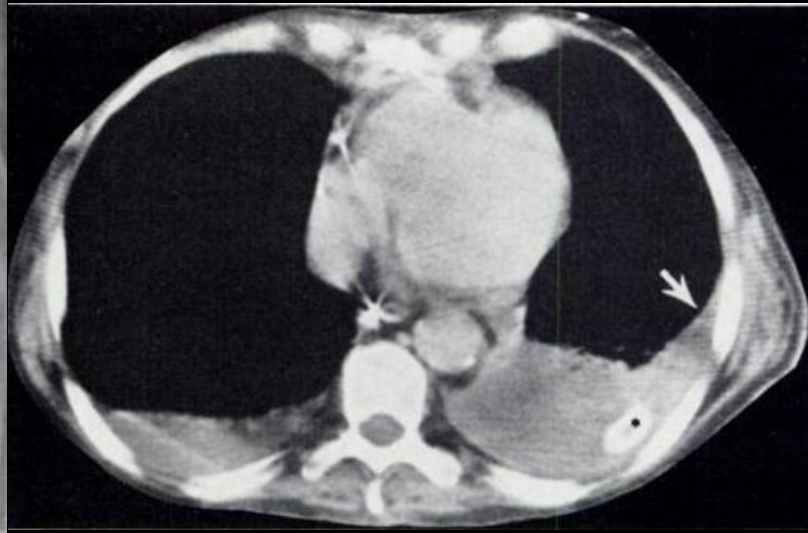
Typical Meniscus Sign of Free Pleural Effusion





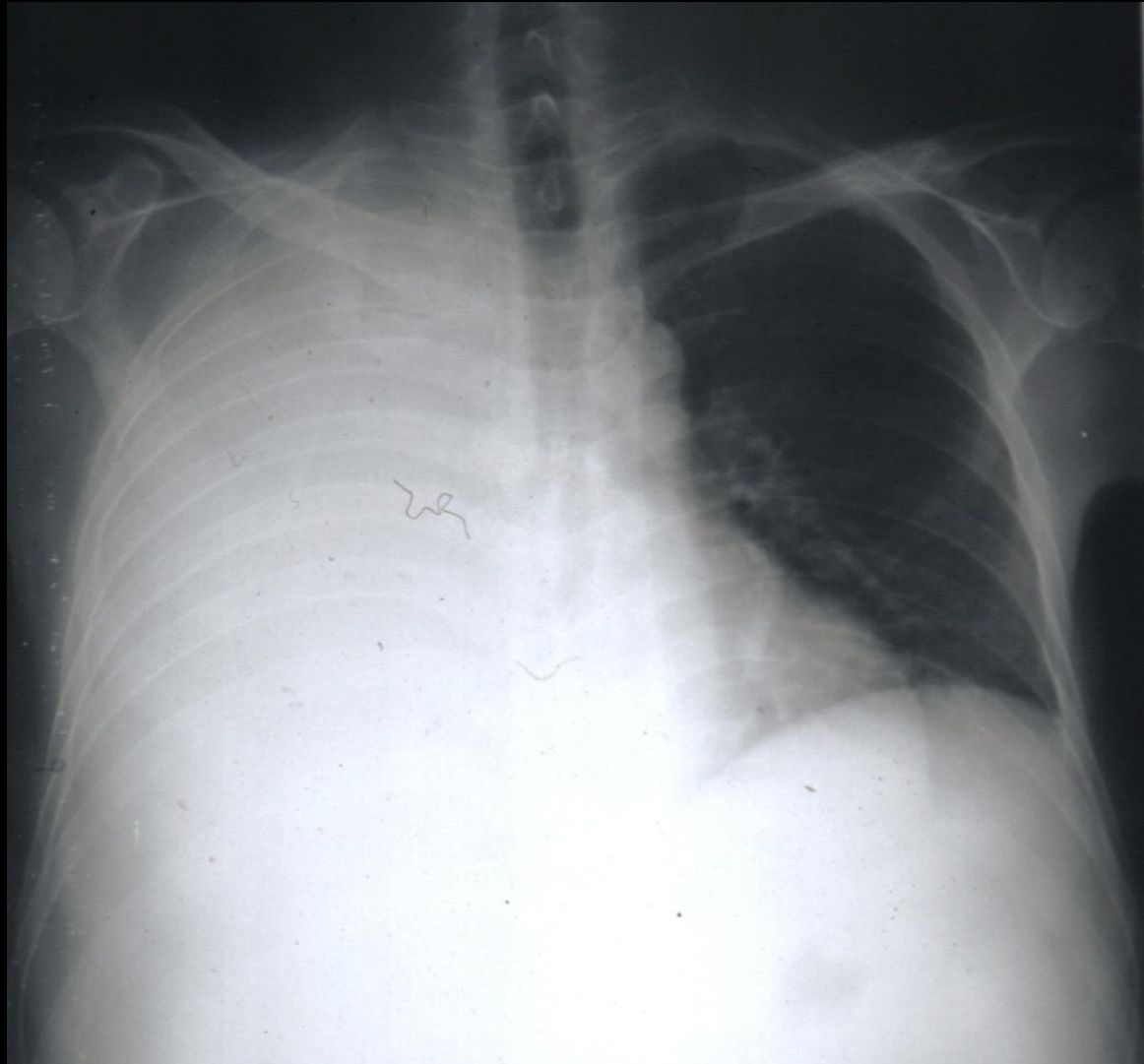
• **L't : Moderate amount PE**

- Increased opacity
- Obliteration of hemidiaphragm
- Meniscus sign



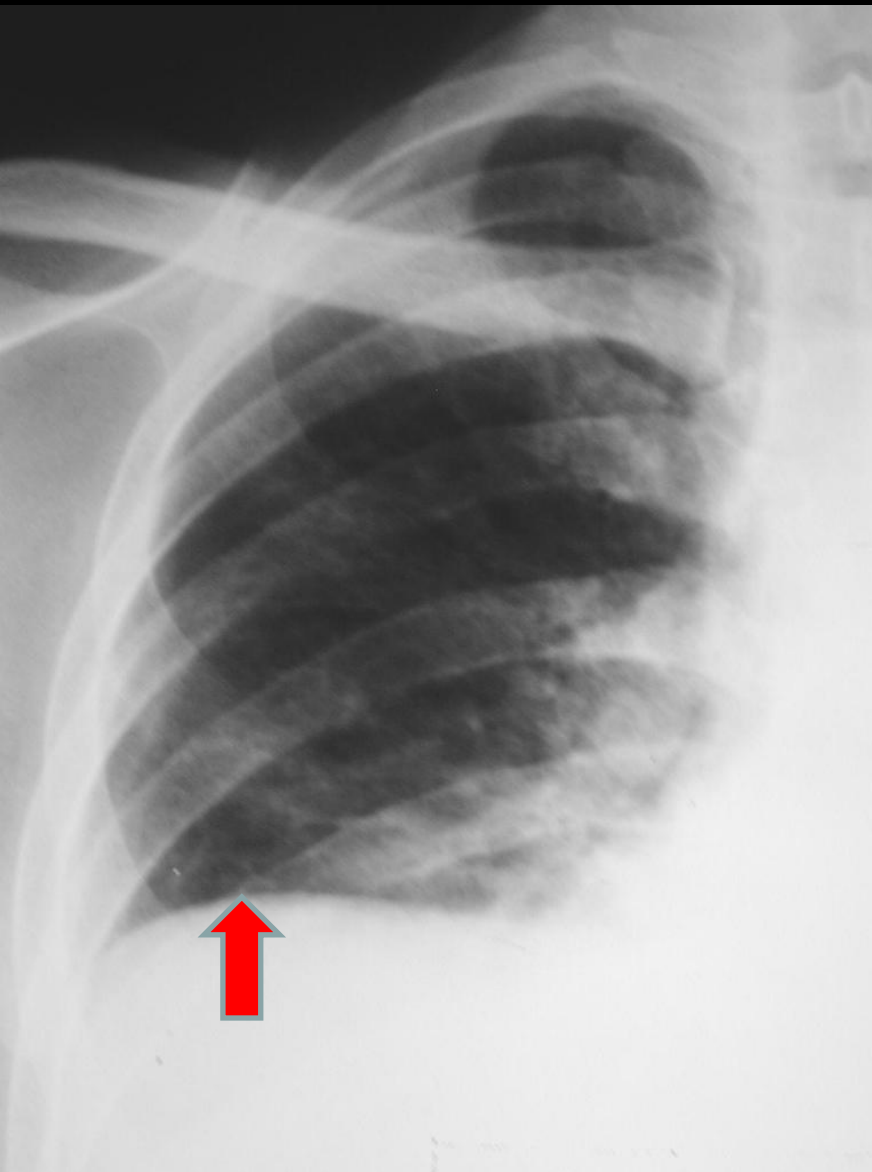
R't : Small amount PE - Increased opacity

Large amount pleural effusion



-Increased density over **entire hemithorax**

Subpulmonary Pleural Effusion



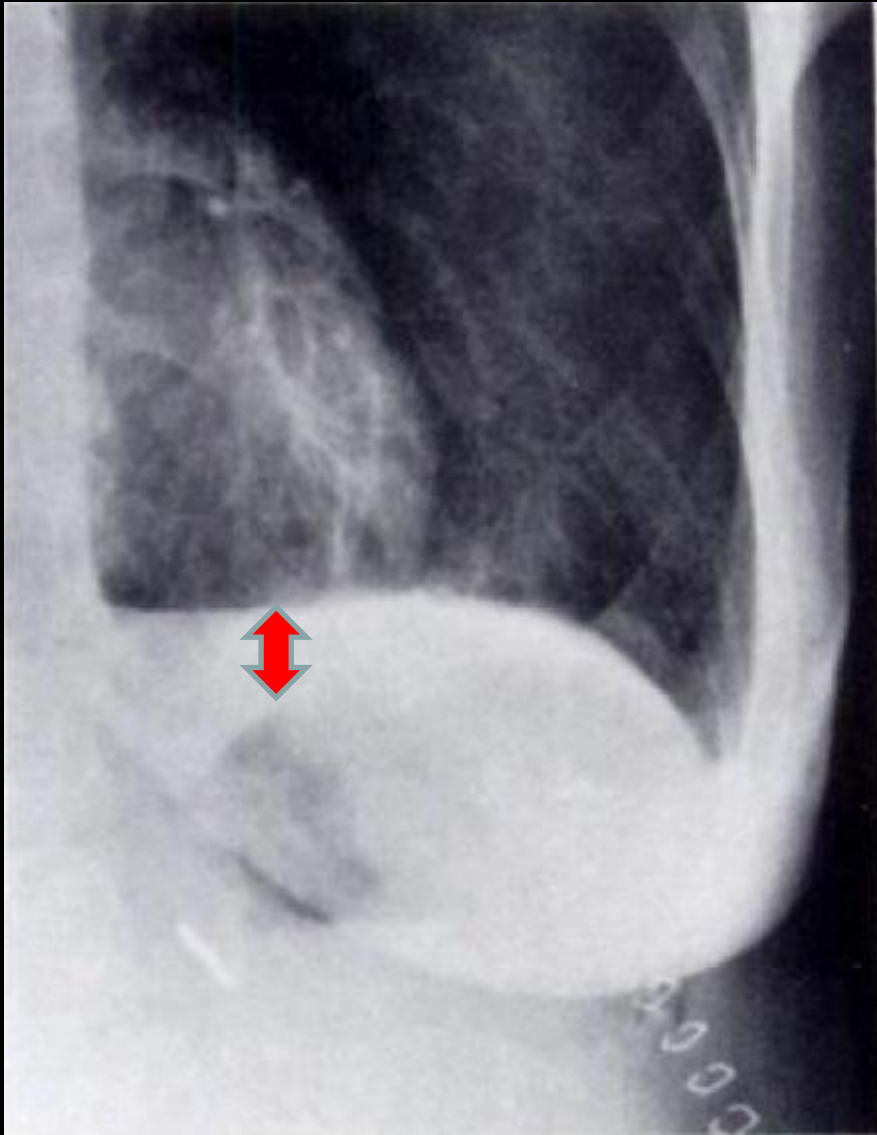
■ 定義

- Pleural effusion 只會積在下肺葉和橫膈之間，而不會溢出至同側的C-P sulcus。
- 由於積液積存於橫膈和visceral pleural of lower lobe之間，積液量愈多，則lower lobe愈往上推移，所以CXR上有如橫膈一般，稱為“**pseudodiaphragm**”。

■ PA view

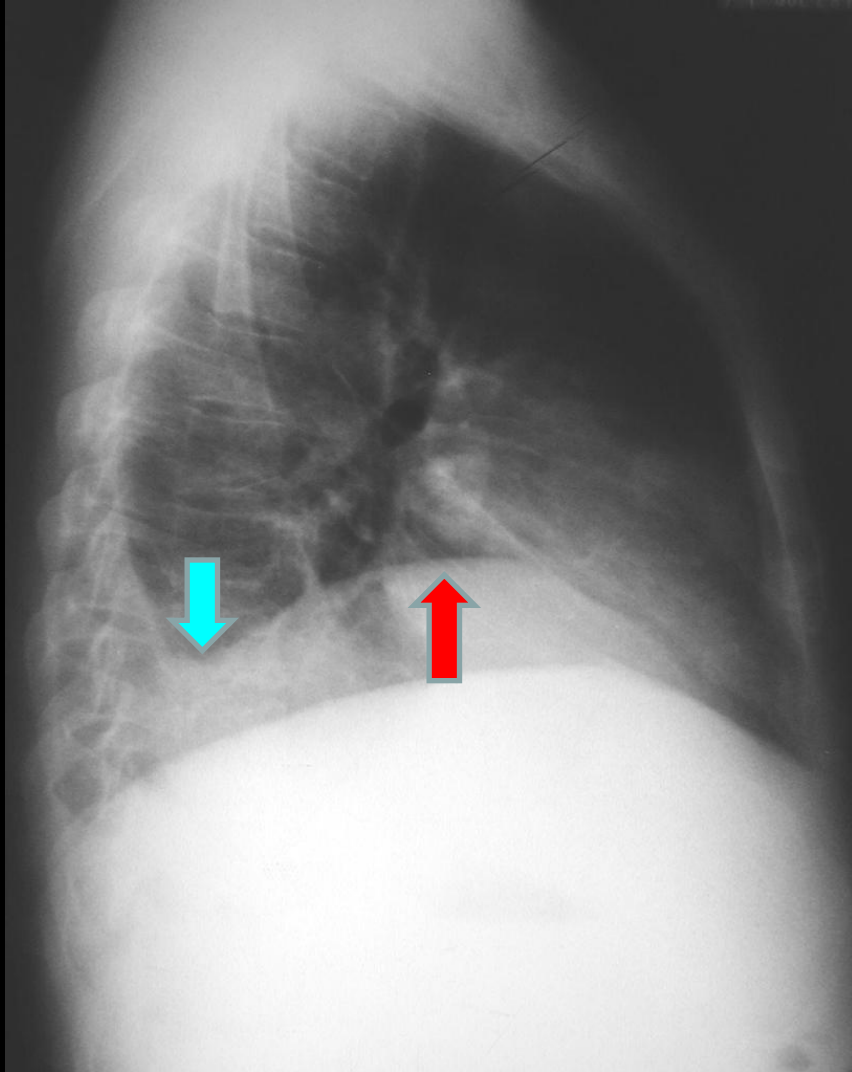
- Diaphragm 的最高點向外移至外 1/3 (正常的在內1/2~1/3)
- C-P angle 變鈍、變淺
- Diaphragm 以下的lung markings 消失
- L't side: diaphragm 和 gastric bubble 相隔 > 2cm

Subpulmonic Effusion



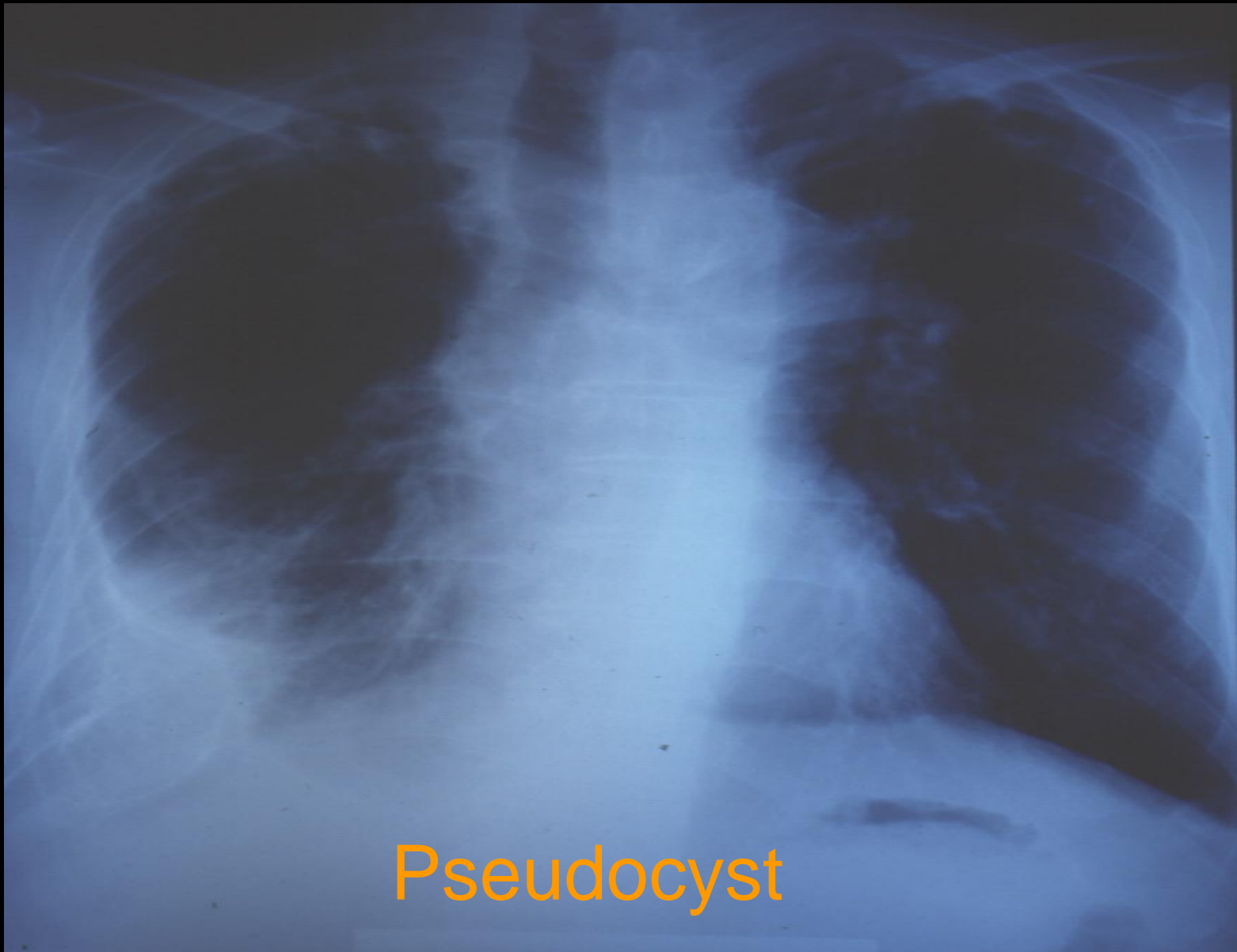
- L't side: diaphragm 和 gastric bubble 相隔 > 2cm

Subpulmonary Pleural Effusion

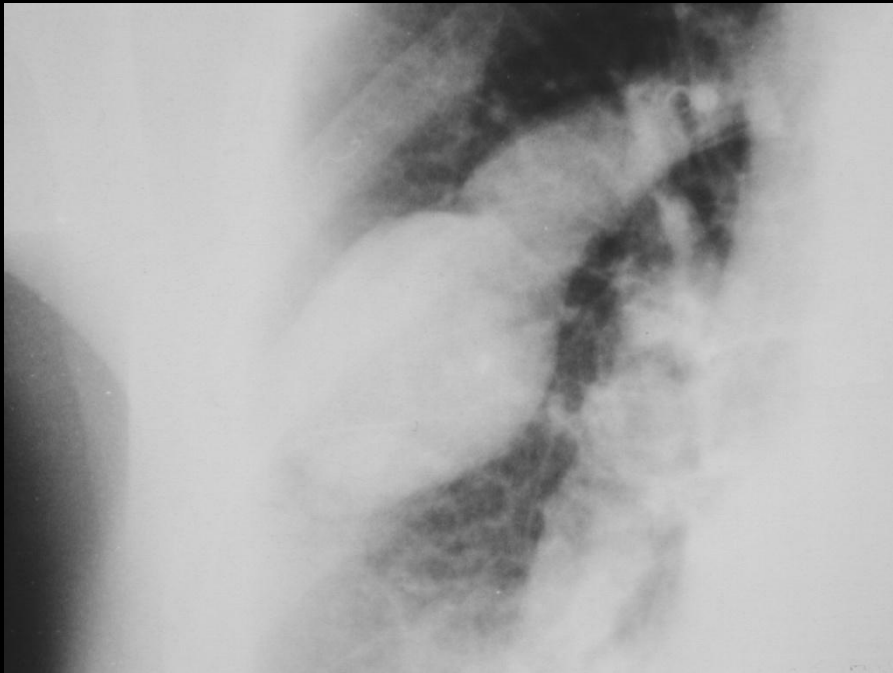

■ Lateral view

- 後段diaphragm變平 (curve消失), 並且會中止在major fissure處
- Meniscus in posterior C-P angle

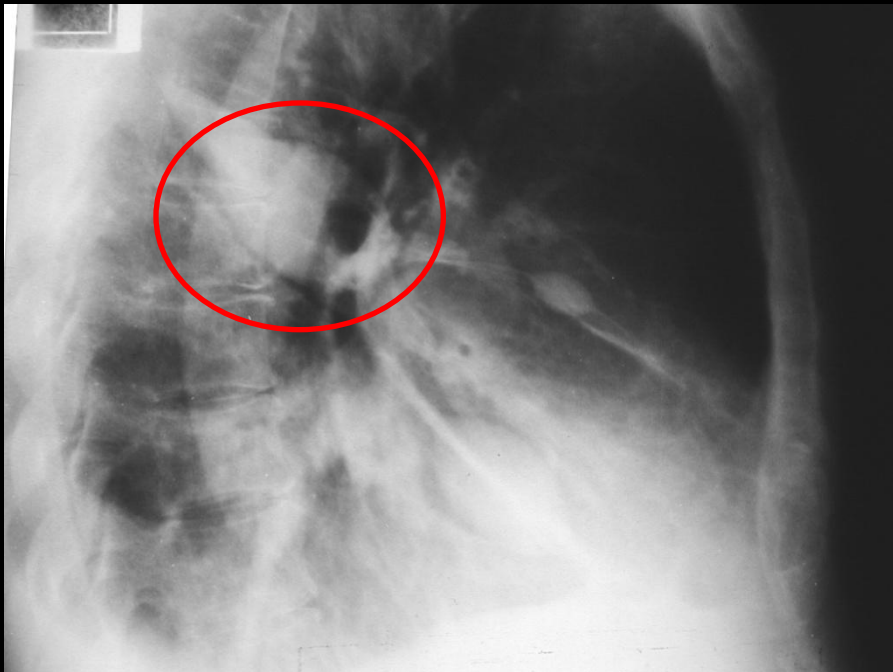


Pseudocyst

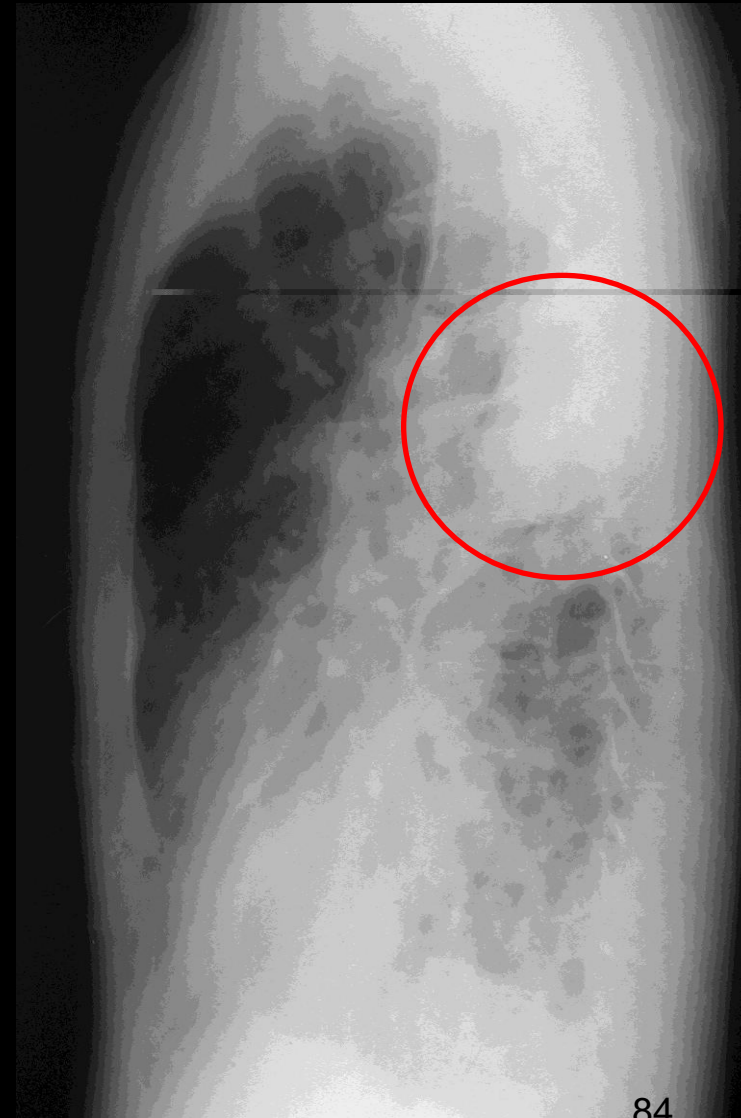
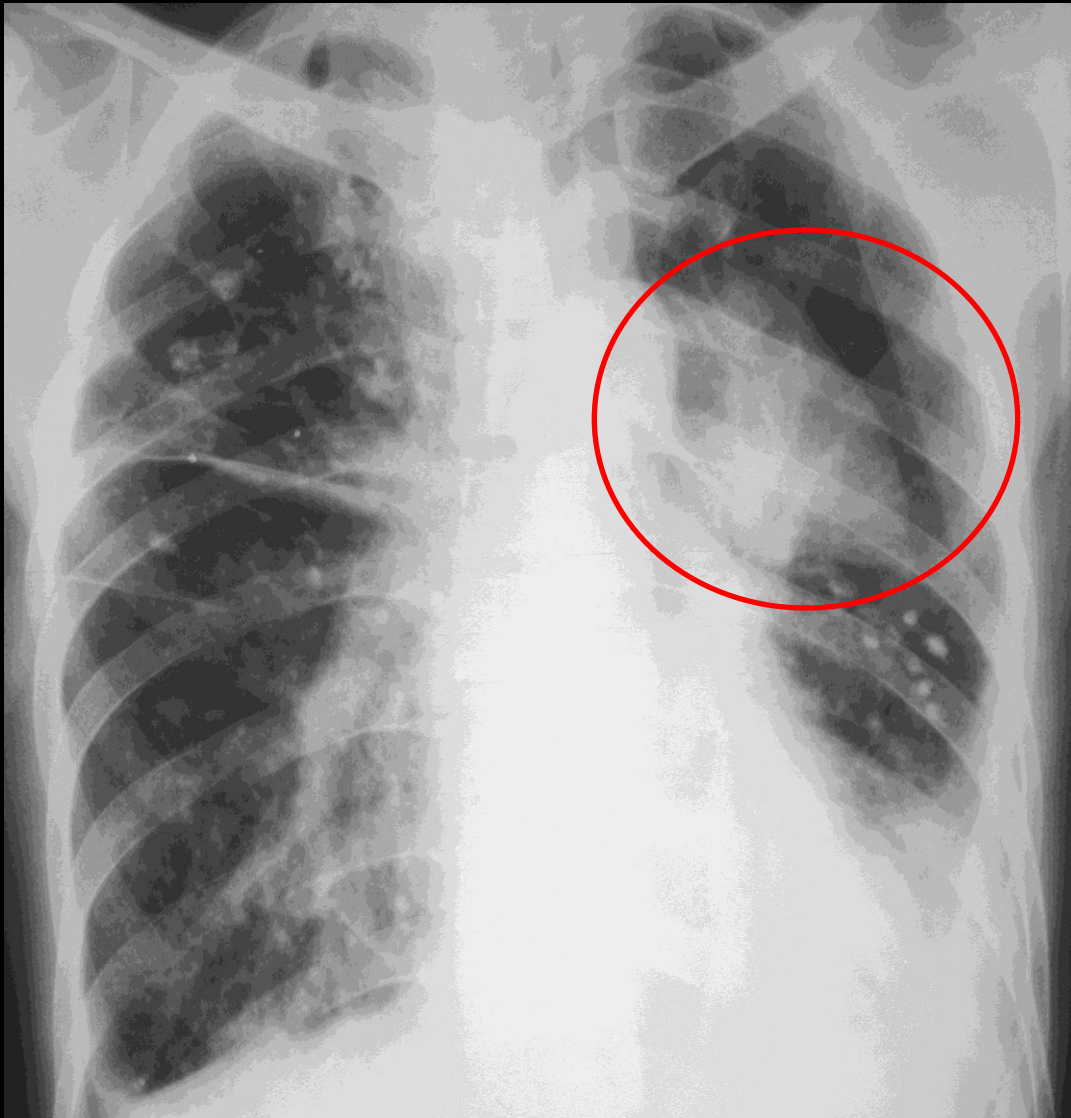


Interlobar Effusion

- Encapsulated within fissures, particularly in **heart failure**
- 好發頻率：
 - **R't side** > L't side
 - **Minor** > major fissure
- 邊緣：
 - well-demarcated or incomplete upper border
- 形狀：
 - PA view : round or oval
 - Lat. View : lenticular shape
- 又叫做” **phantom tumor**”
 - 用 diuretics 後會消失



CHF with Interlobar Effusion



Pneumothorax

■ Upright patient

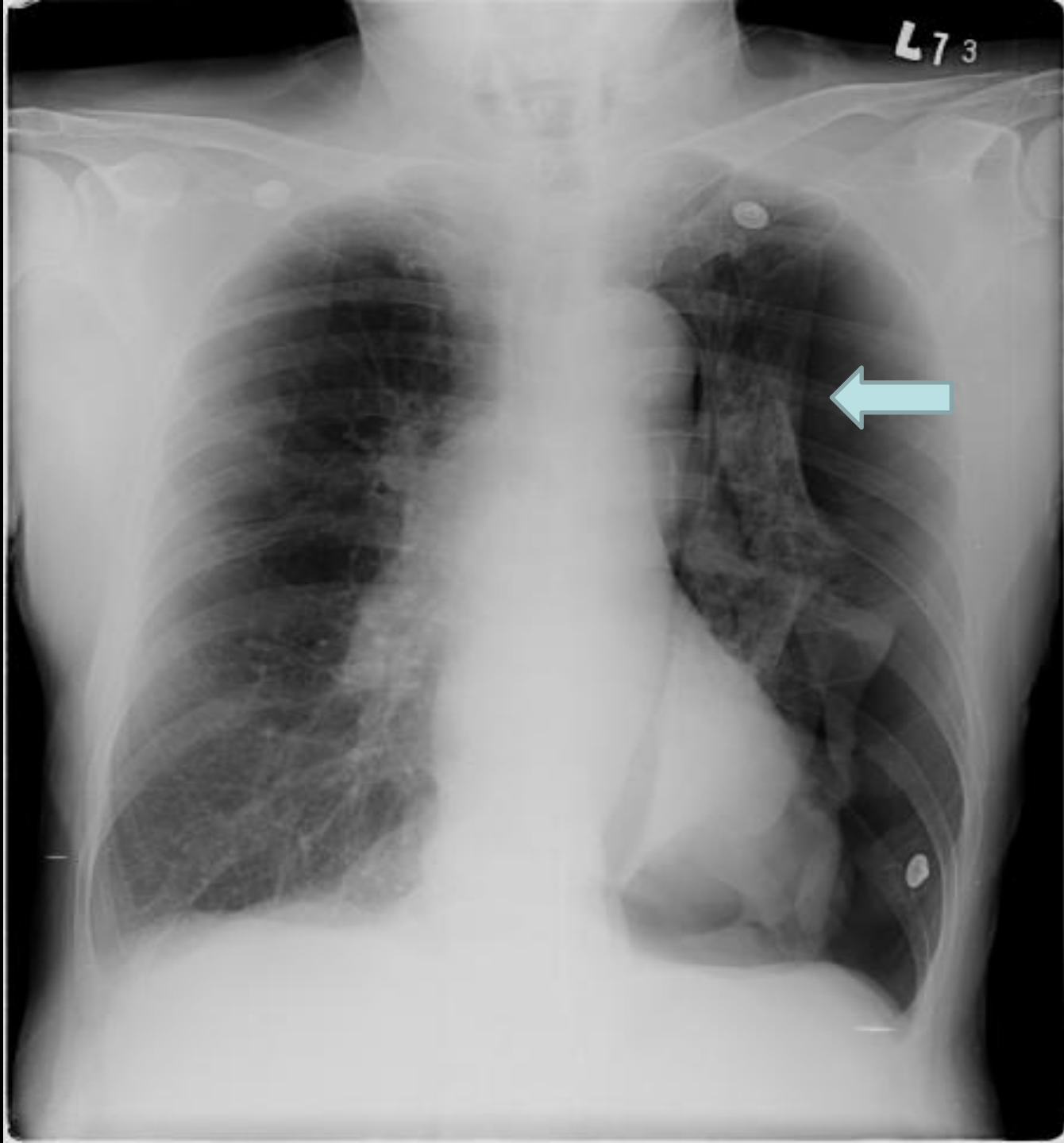
- Identify the **pleural line**
- Most often near the **apex**

■ Supine patient

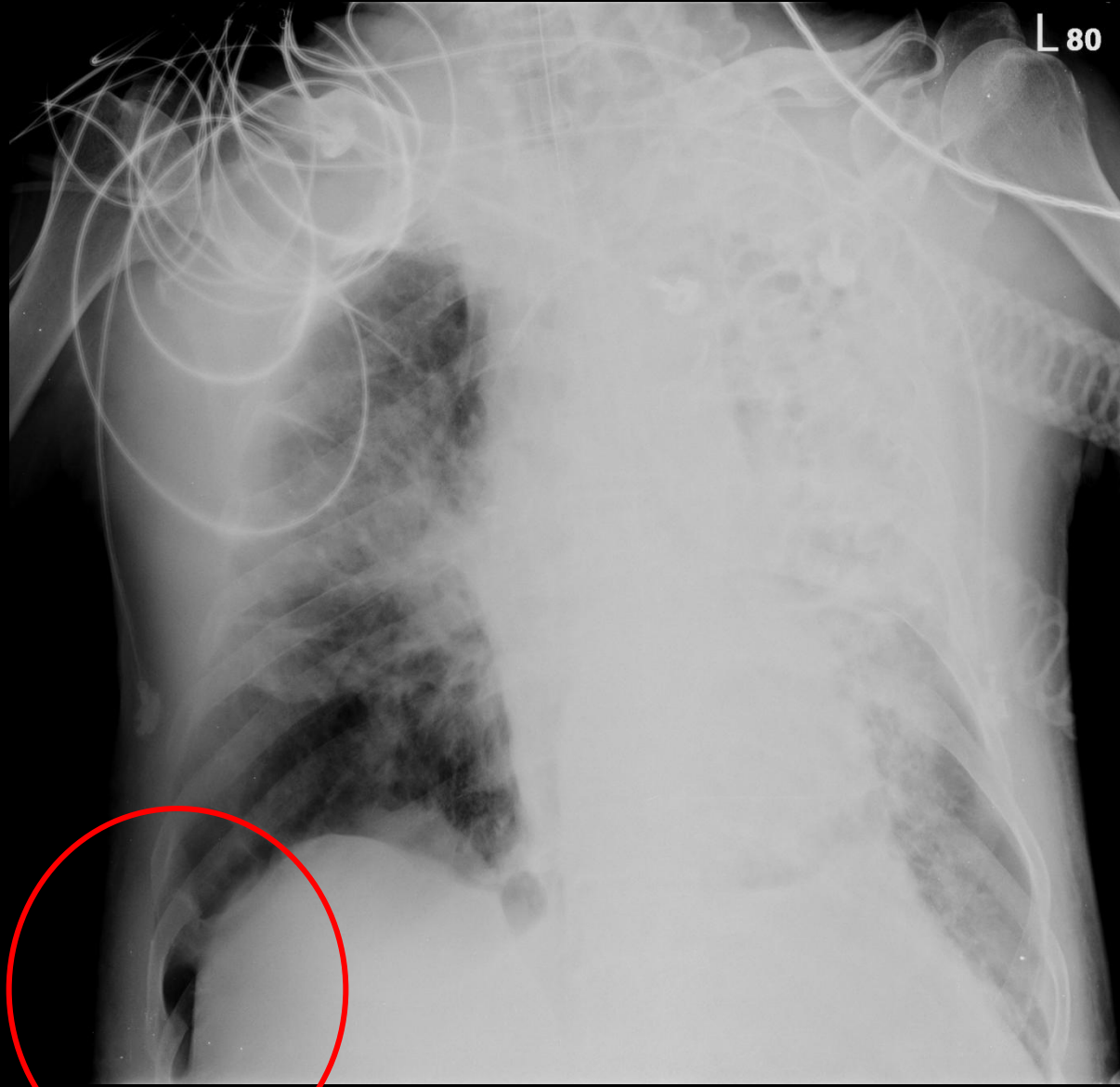
- 在supine position，胸腔最高處為**anterior C-P sulcus**，其次為**lateral CP sulcus**。所以發生氣胸時，air最先填充至anterior CP sulcus，量更多時，lateteral CP sulcus亦被填滿。
- **Deep sulcus sign**: anterior和lateral CP sulcus顯得非常深，橫膈被襯托得很清晰
- Sharper than normal appearance of hemidiaphragm

■ When pleural line is not identified

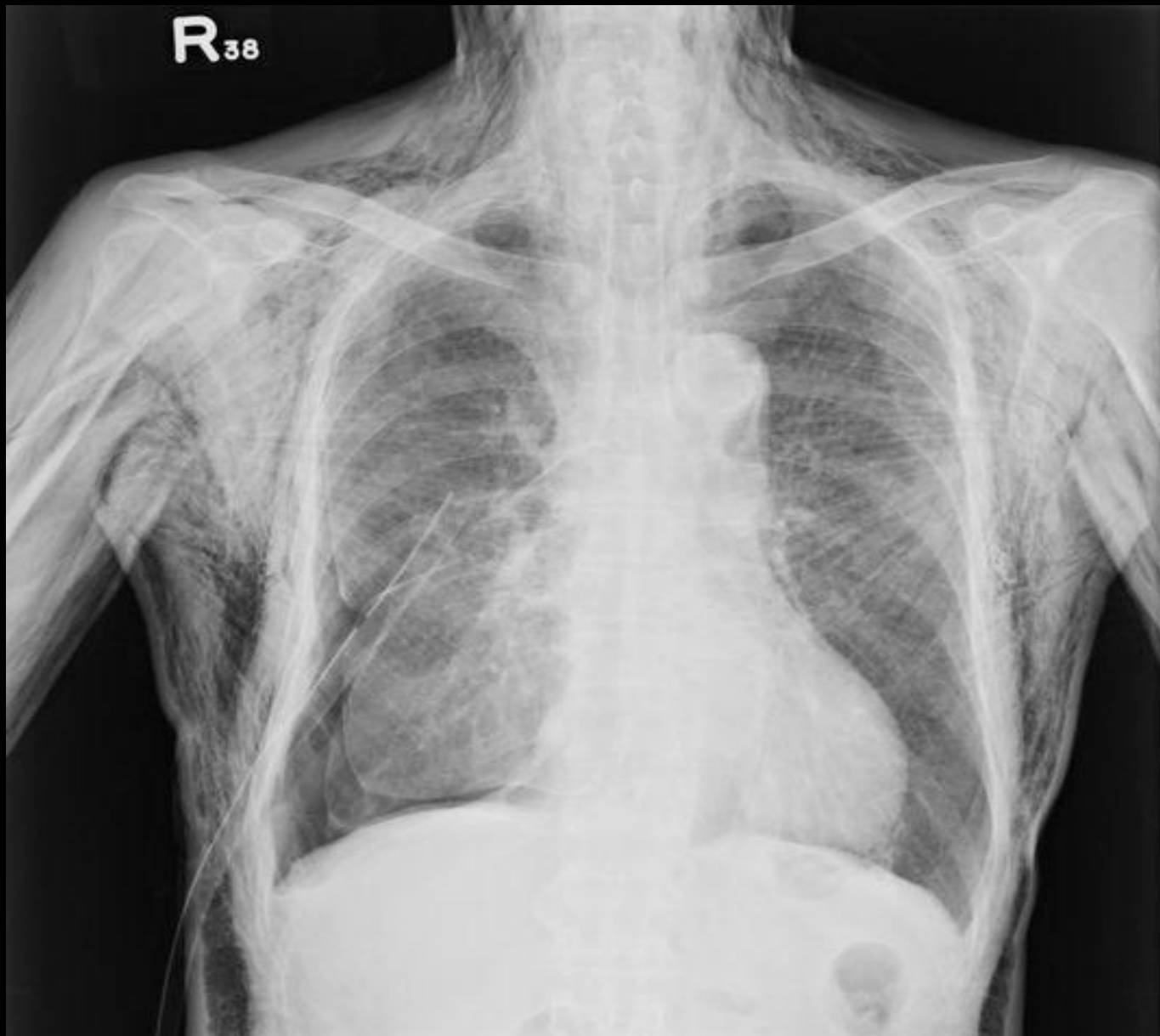- Lateral decubitus view
- Expiratory film: no more useful



Pneumothorax - Deep Sulcus Sign



Pneumothorax - Subcutaneous Emphysema

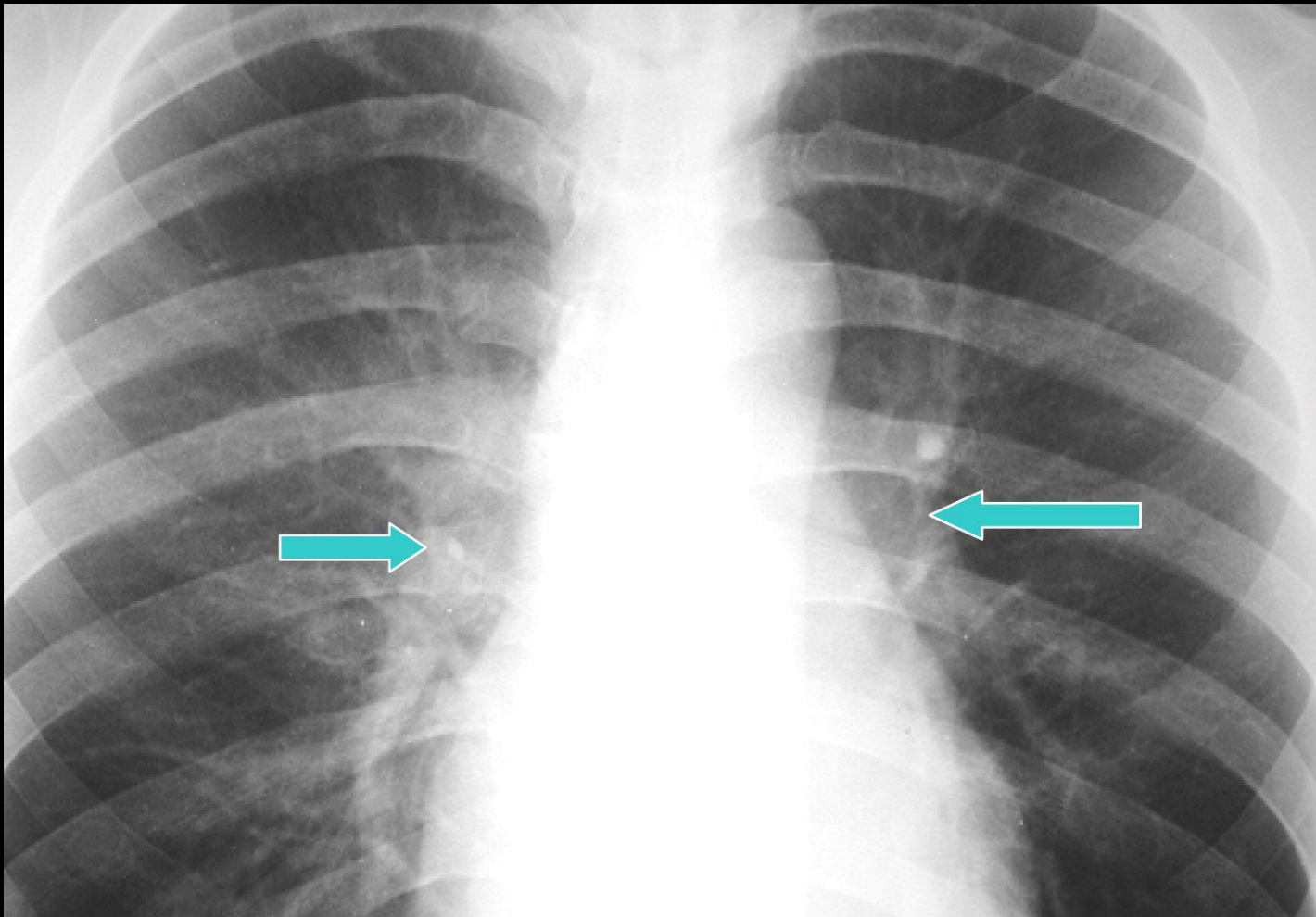


補充教材

Hilar Lesions

Hilum

- 左右主支氣管及肺動脈進入肺臟的部分
- 含 血管，支氣管分支，及淋巴



Hilum

■ 觀察重點：

- 大小、位置、形狀、濃度(density)

■ 位置：

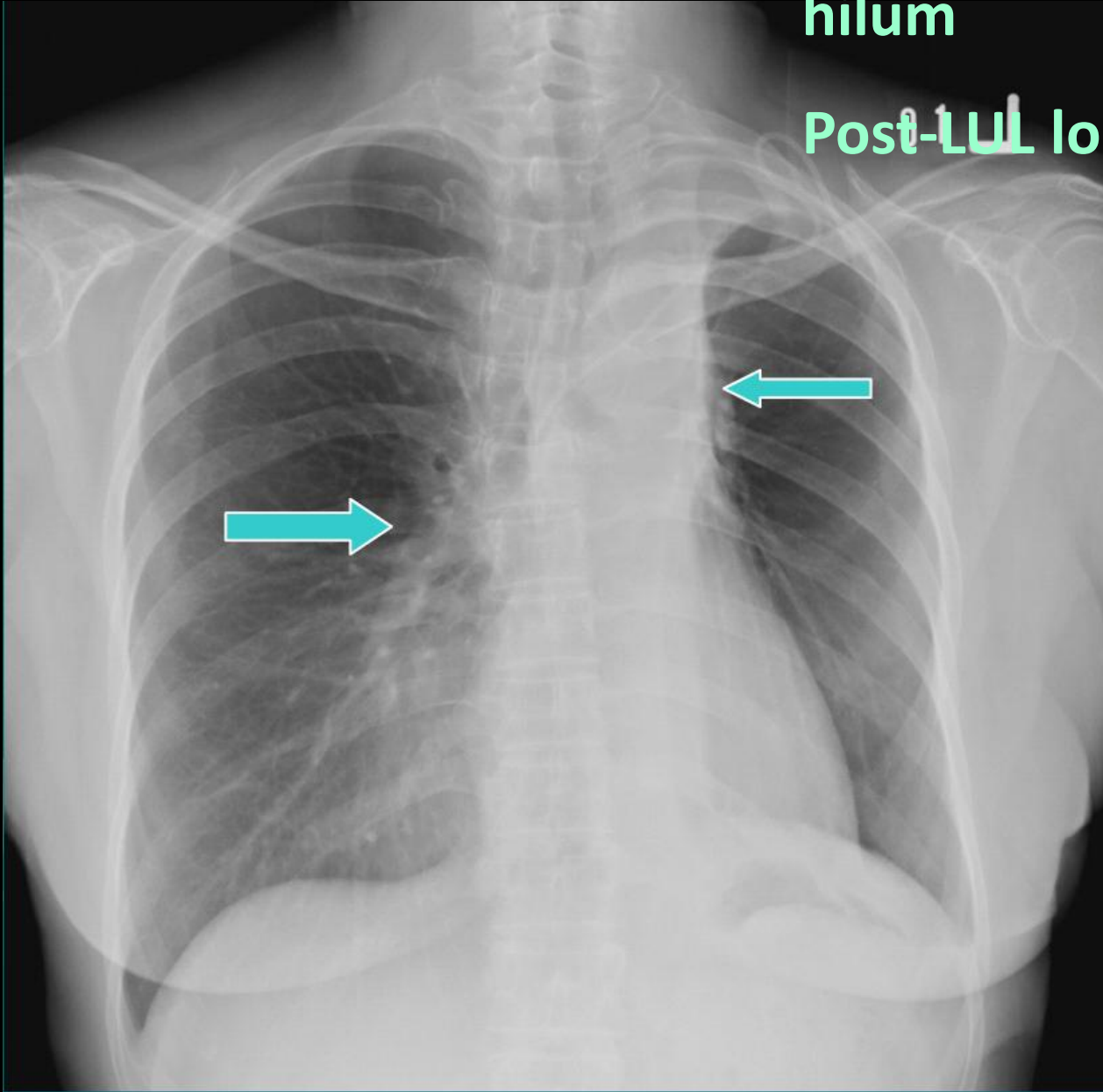
- 正常：左高於右(97%，0.75-3cm，左右等高(3%))
- 異常：右高於左

■ Hilum enlargement

- Hilar lesion
 - Vessel
 - Lymph Node
- Superimposed mass (lung, mediastinum)

**Elevation of Left
hilum**

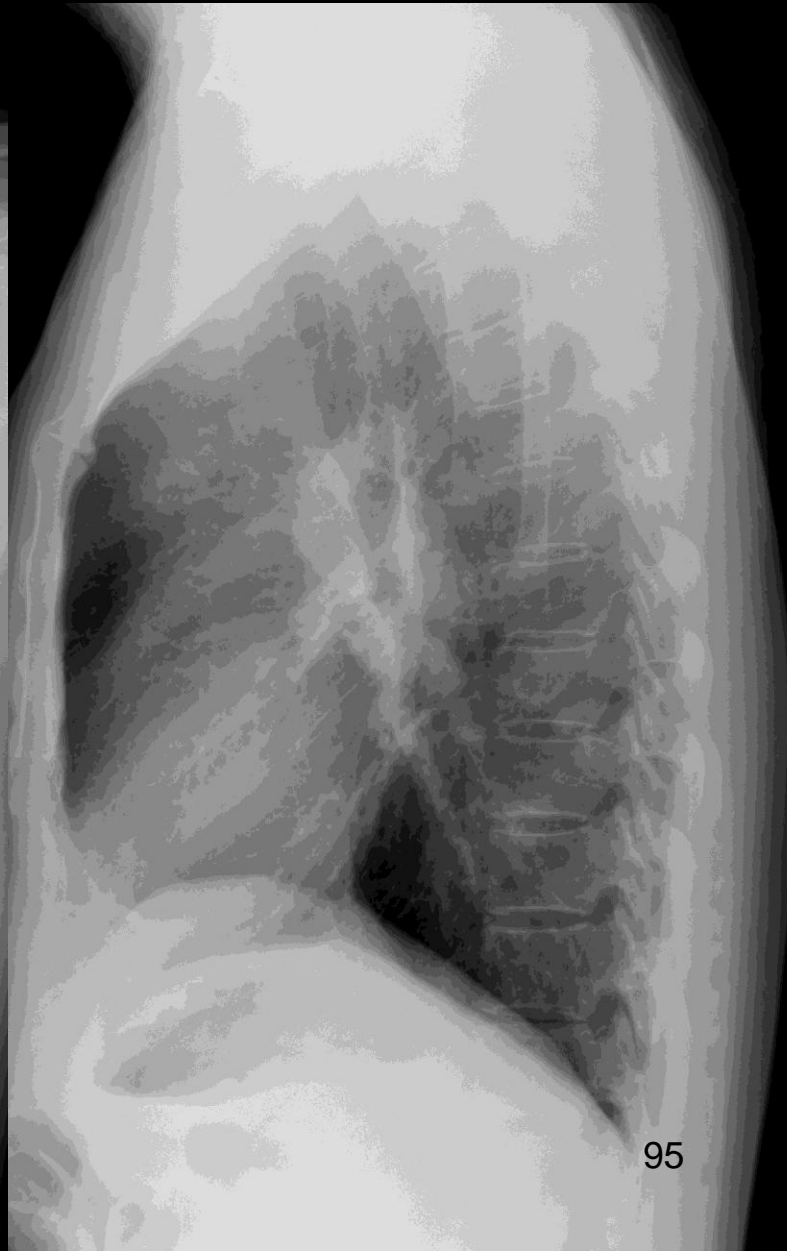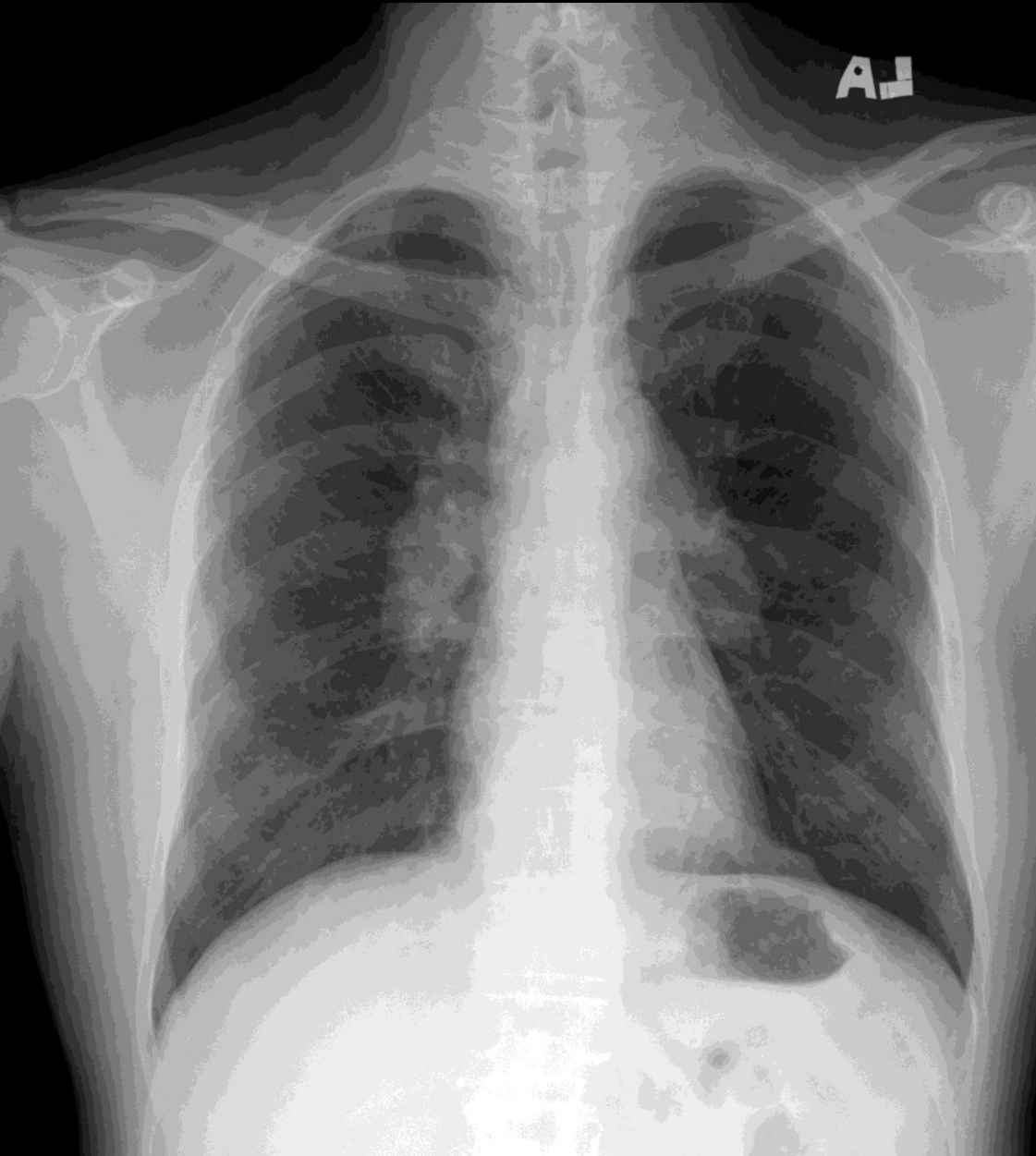
Post-LUL lobectomy



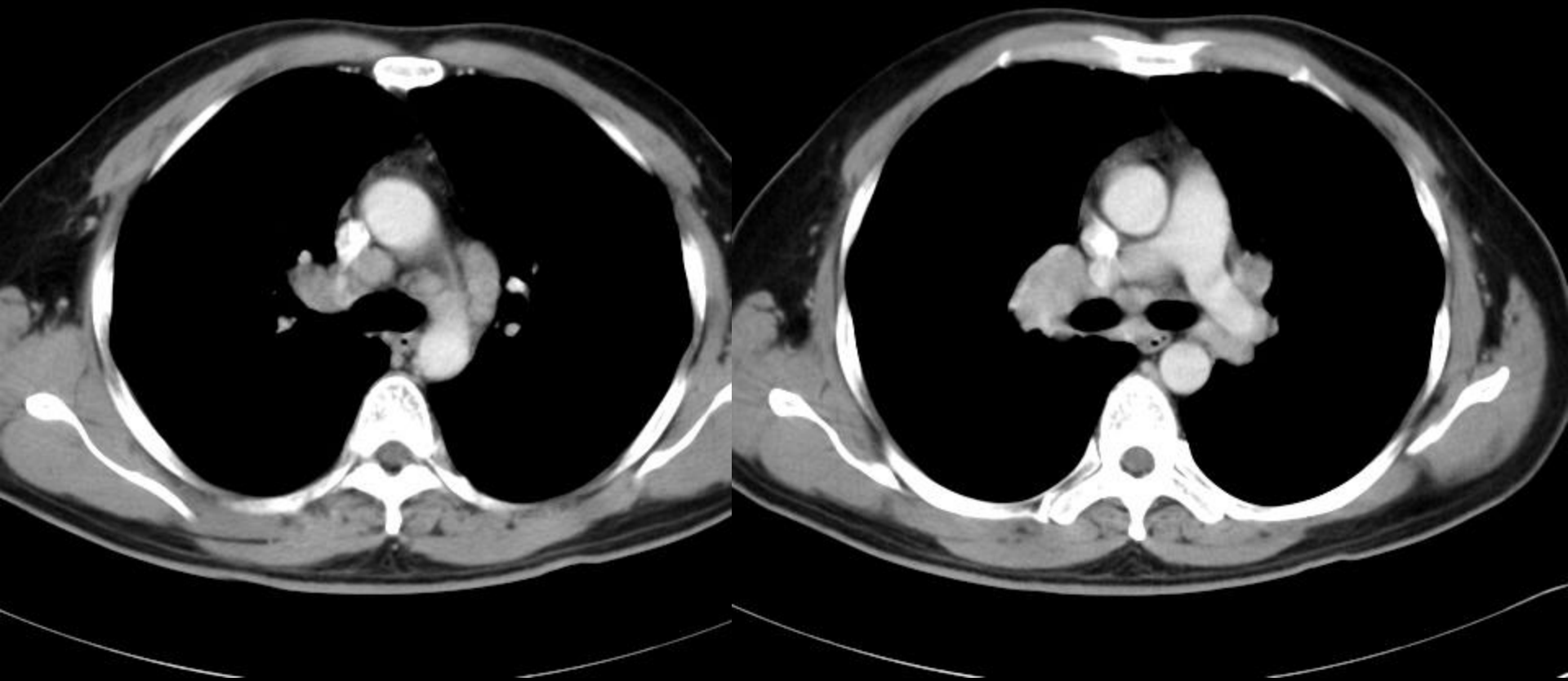
Hilar : Lymphadenopathy (most common)

- **Sarcoidosis**
 - Symmetric and bilateral, 1-2-3 pattern
- **Granulomatous infections**
 - tuberculosis, NTM, histoplasmosis, cryptococcus
 - lower attenuation due to necrosis, calcification
- **Lymphoproliferative disorders**
 - Multiple nodes, Prevascular and AP window node
- **Metastatic tumor**
- **Lung carcinoma**
- Inflammatory adenopathy
- Others: Castleman's disease, drug toxicity, silicosis, pneumoconiosis

Asymptomatic hilar enlargement



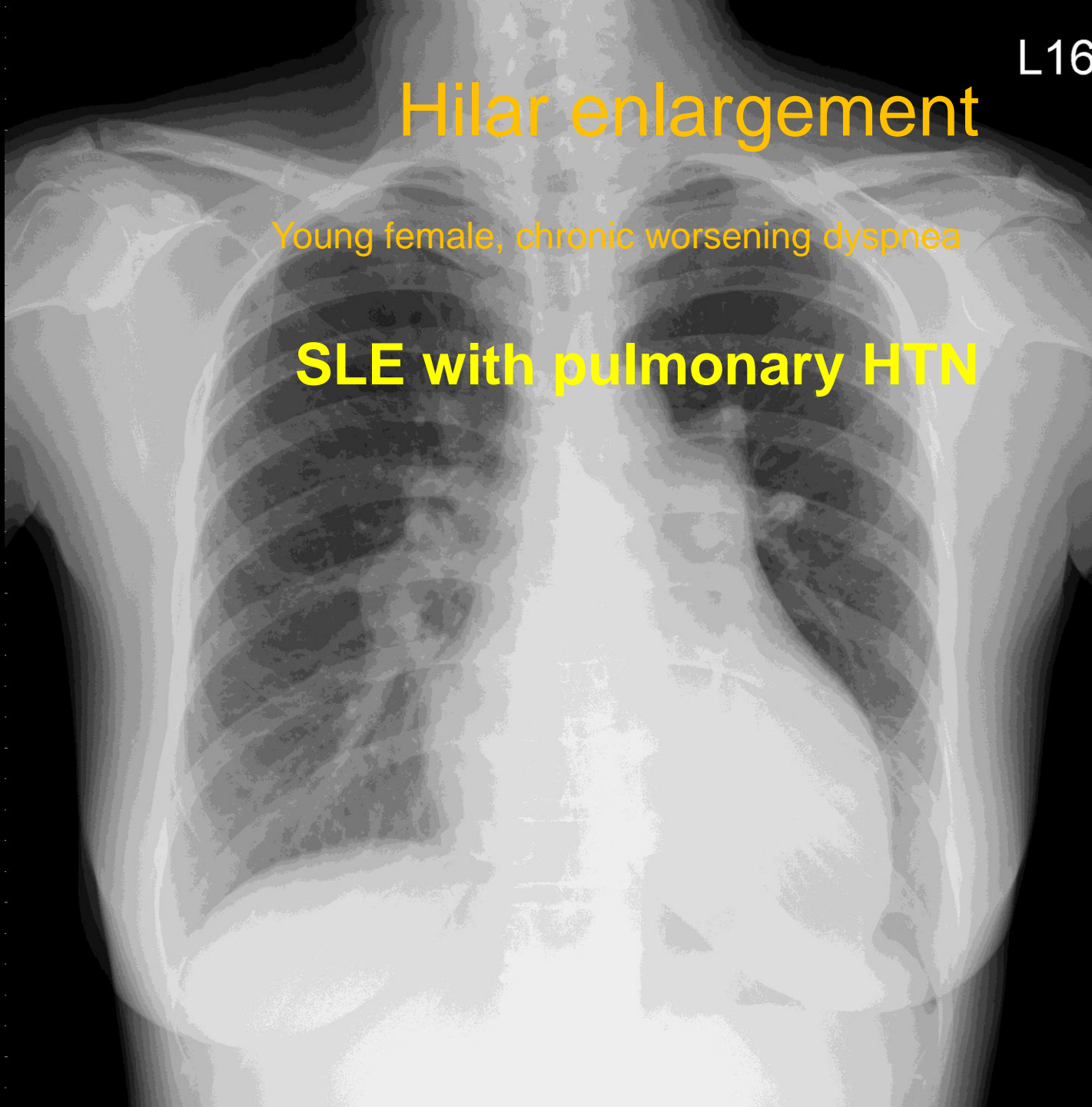
Sarcoidosis : Chronic benign LAP



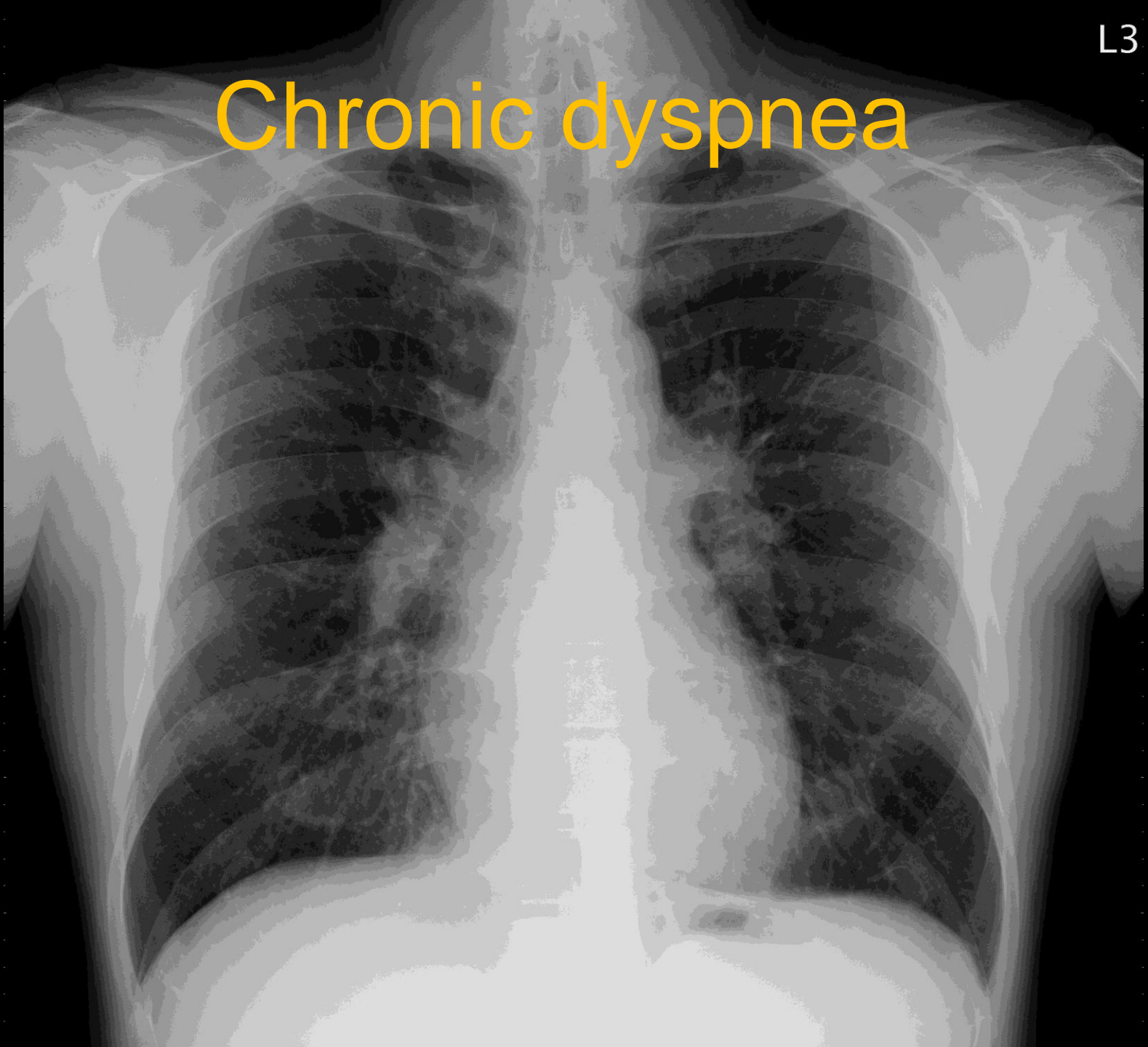
Hilar enlargement

Young female, chronic worsening dyspnea

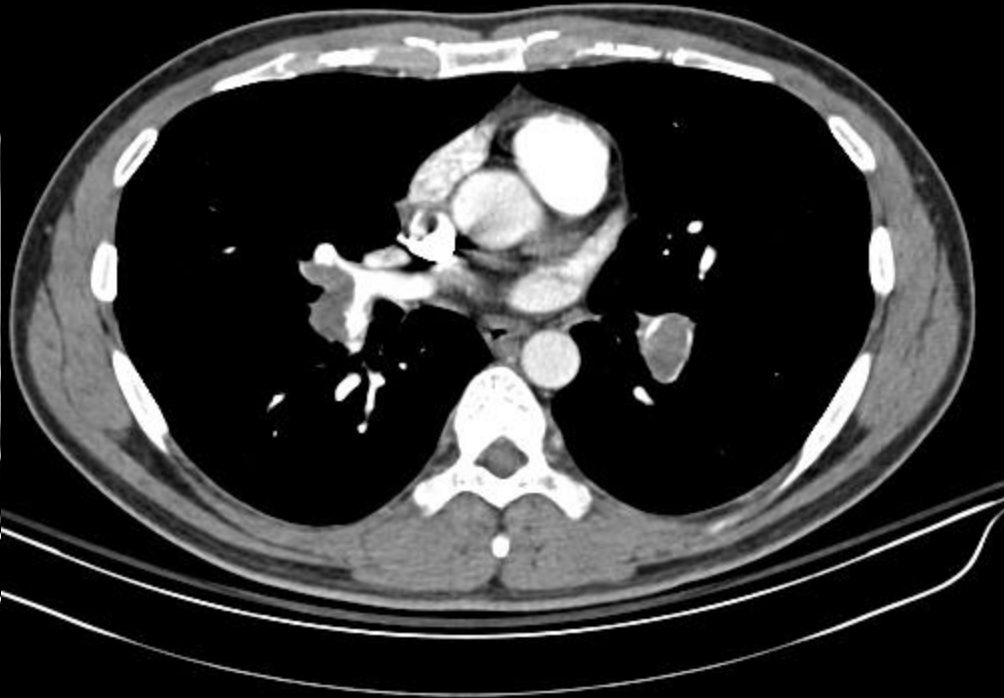
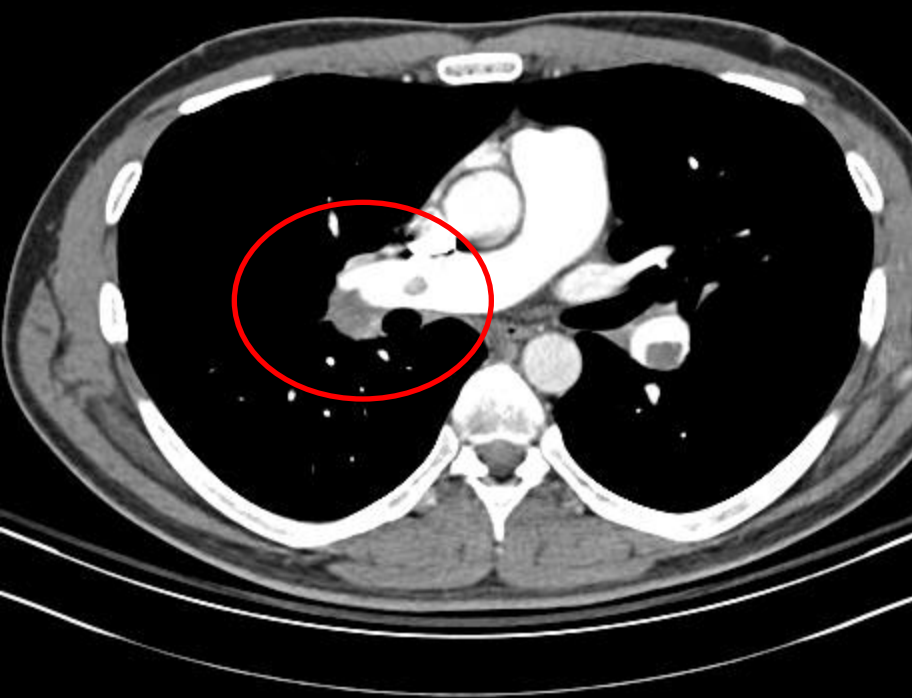
SLE with pulmonary HTN



Chronic dyspnea

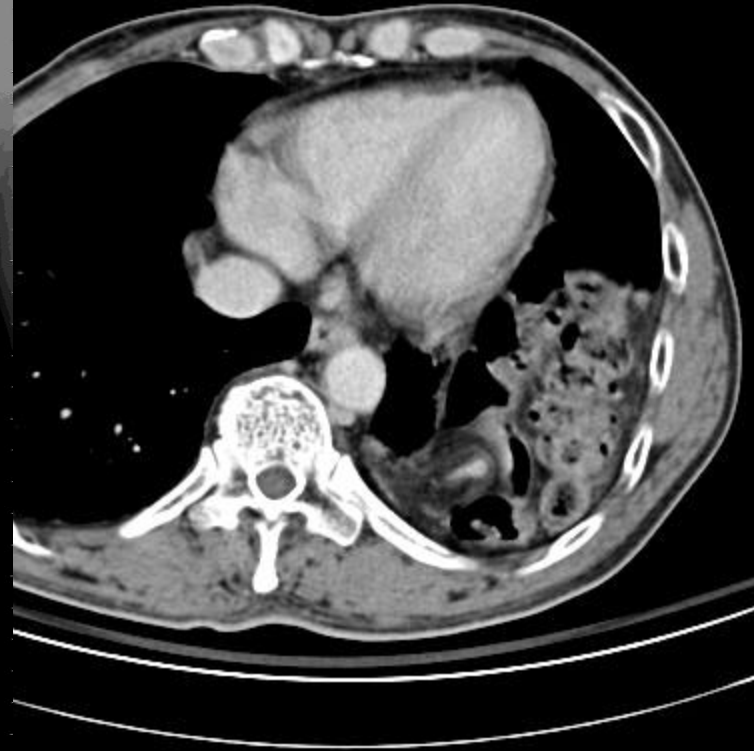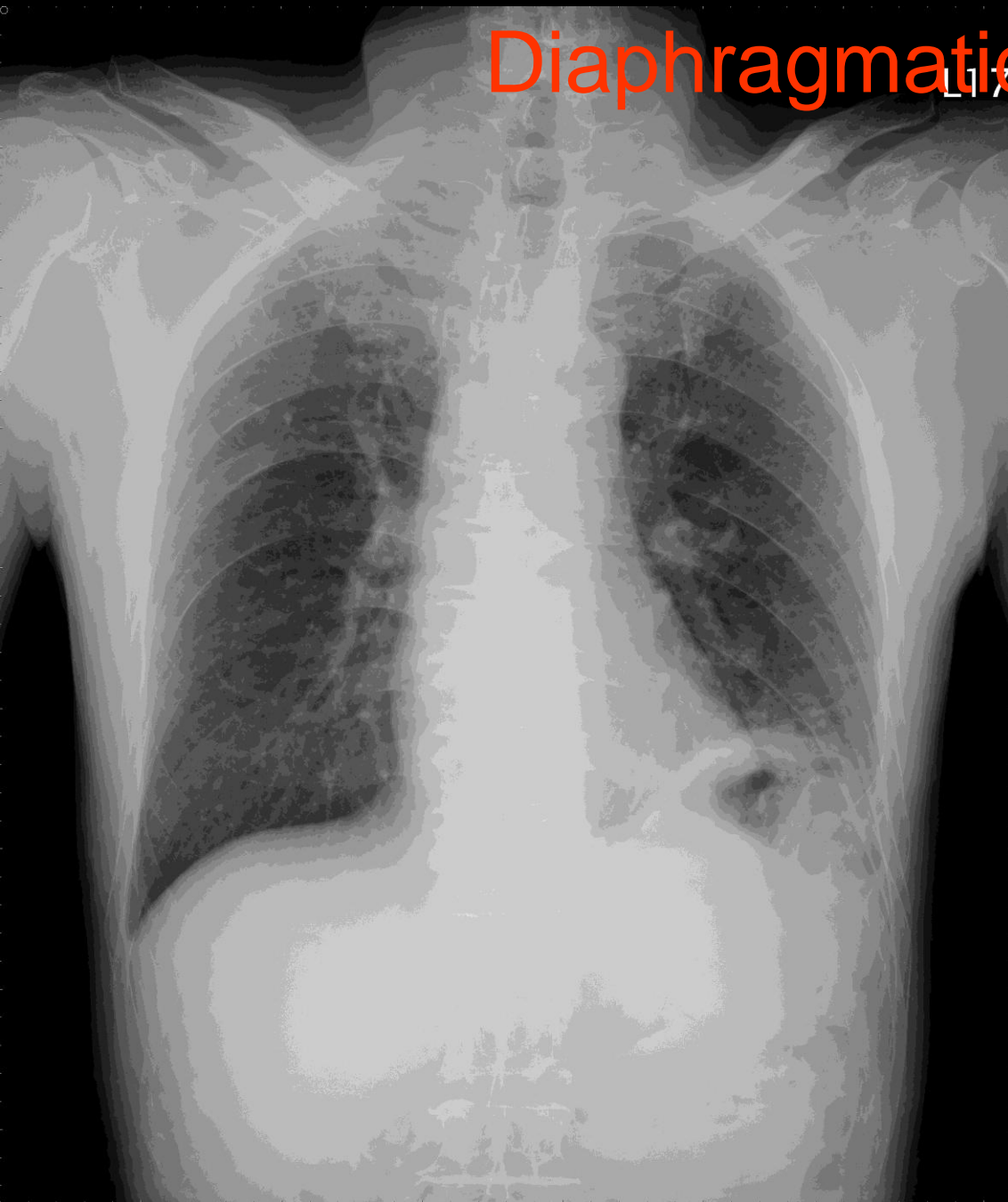


Pulmonary thromboembolism



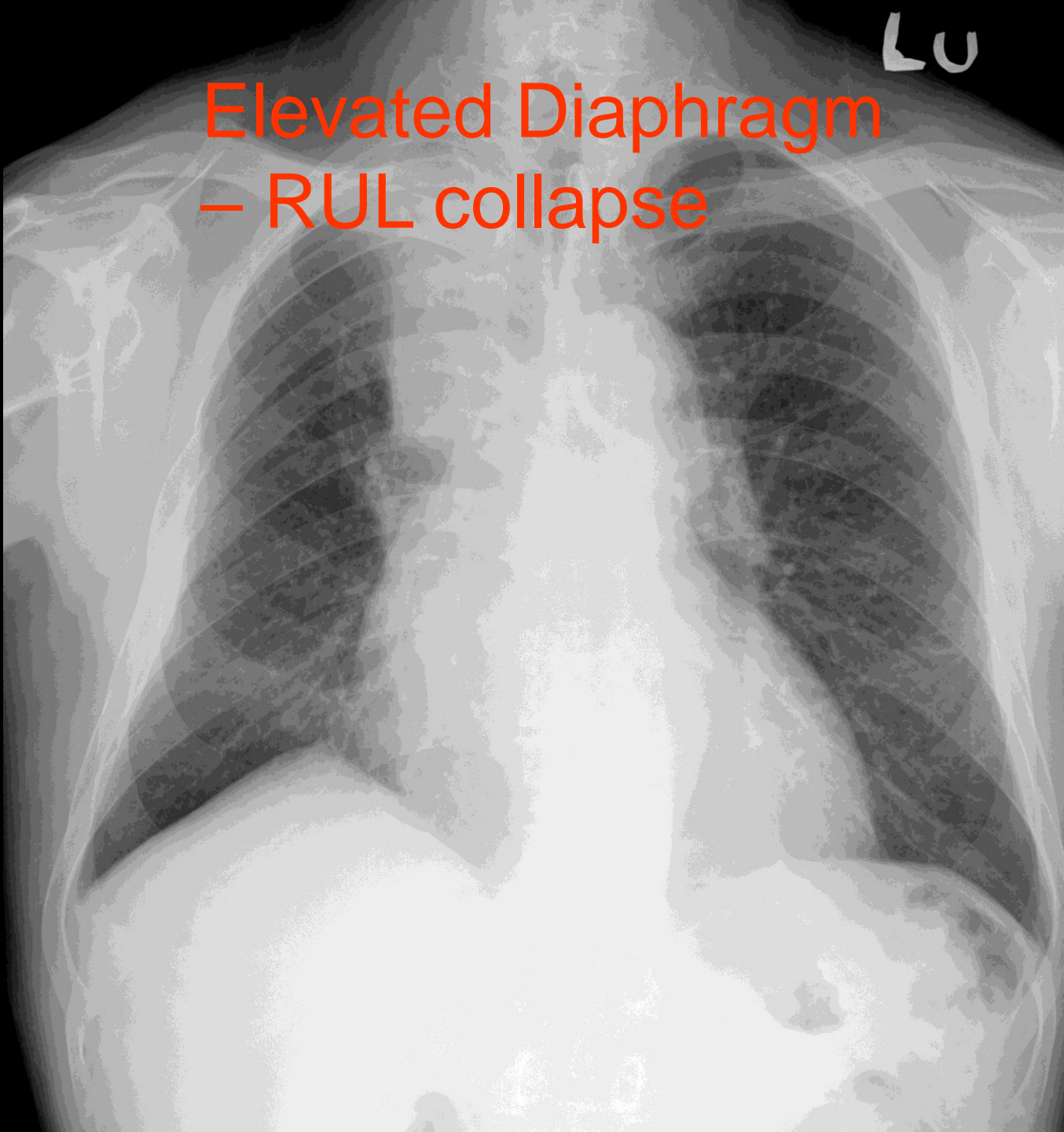
Diaphragm Lesions

Diaphragmatic hernia

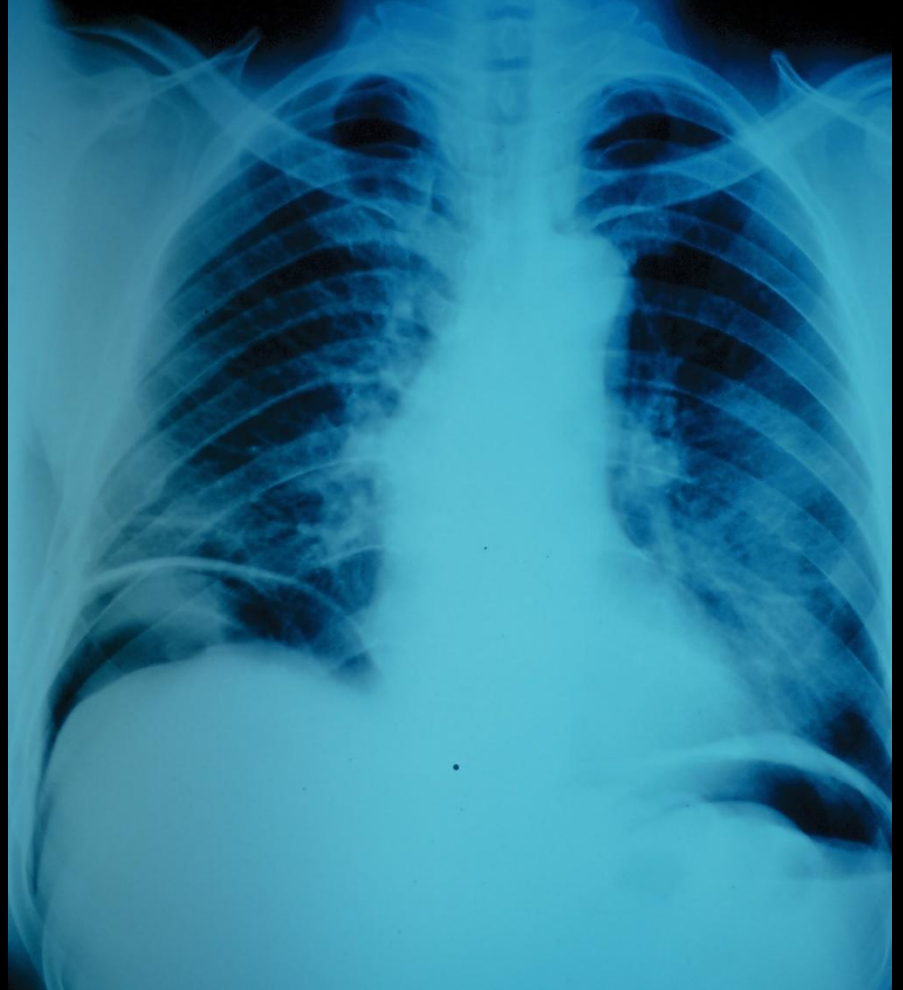
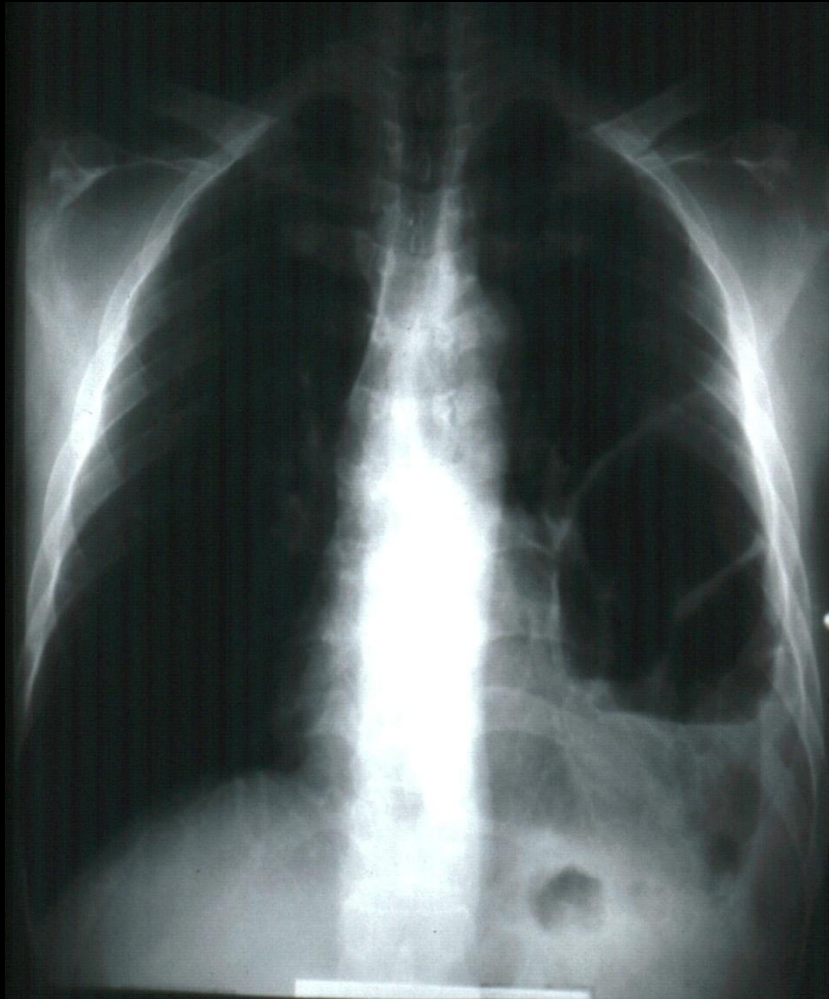

Lu

Elevated Diaphragm
– RUL collapse



Traumatic hemothorax and Subphrenic Air

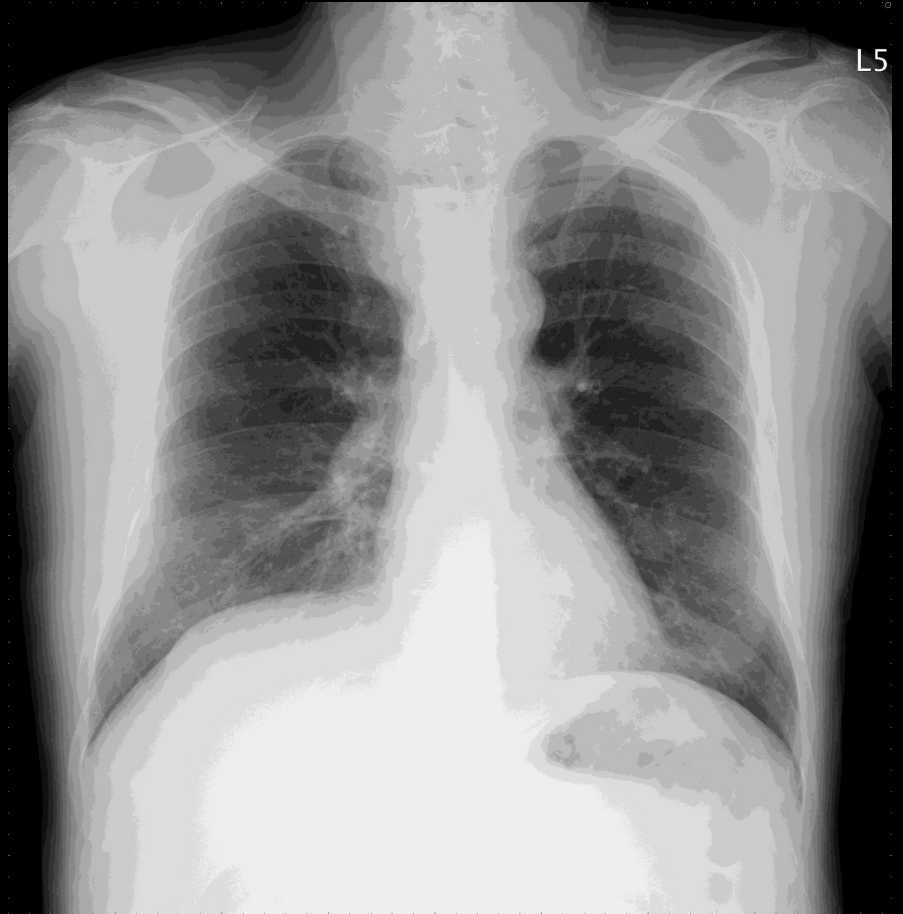
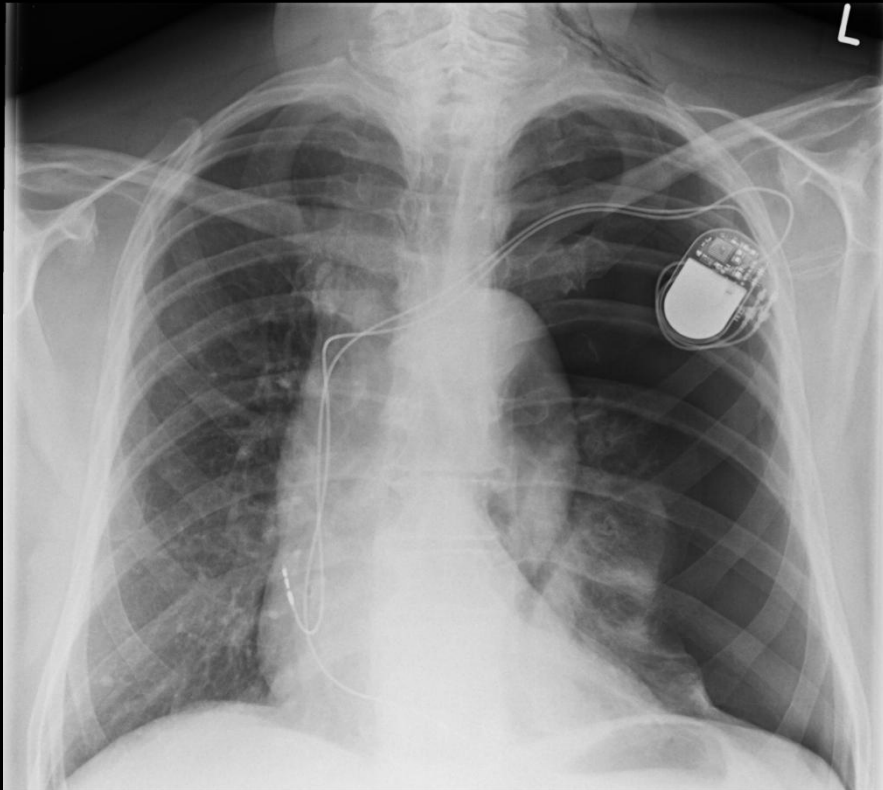


重點整理

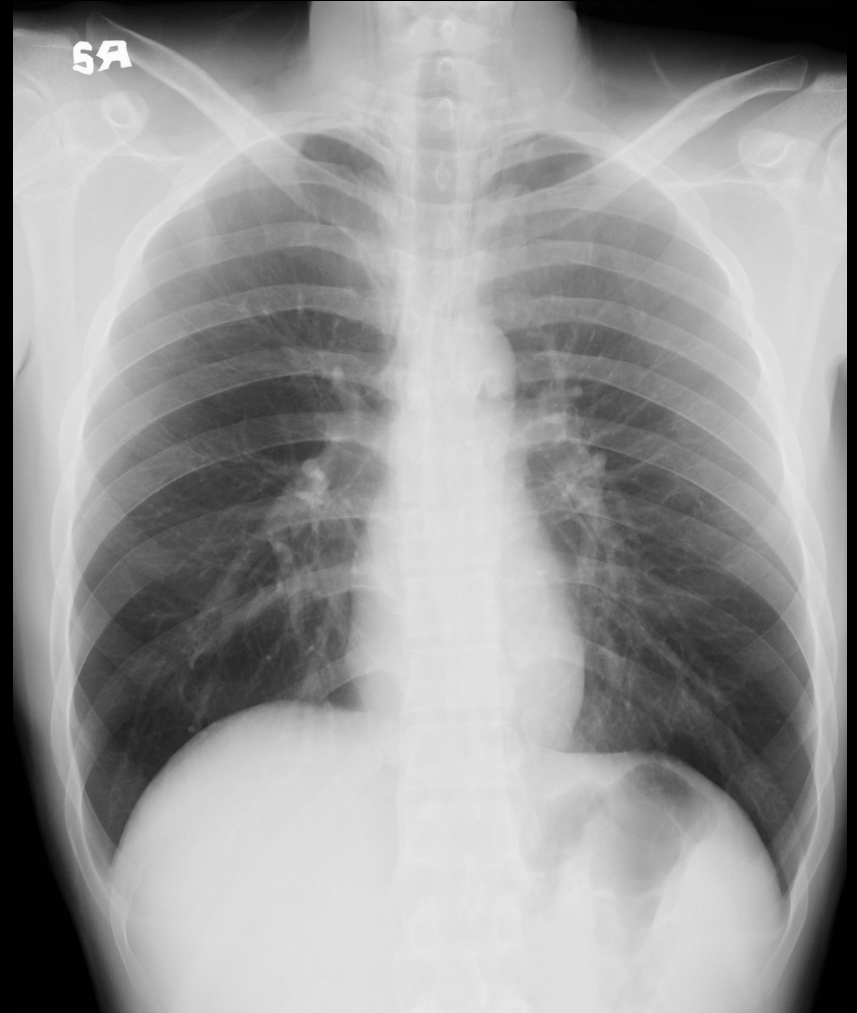
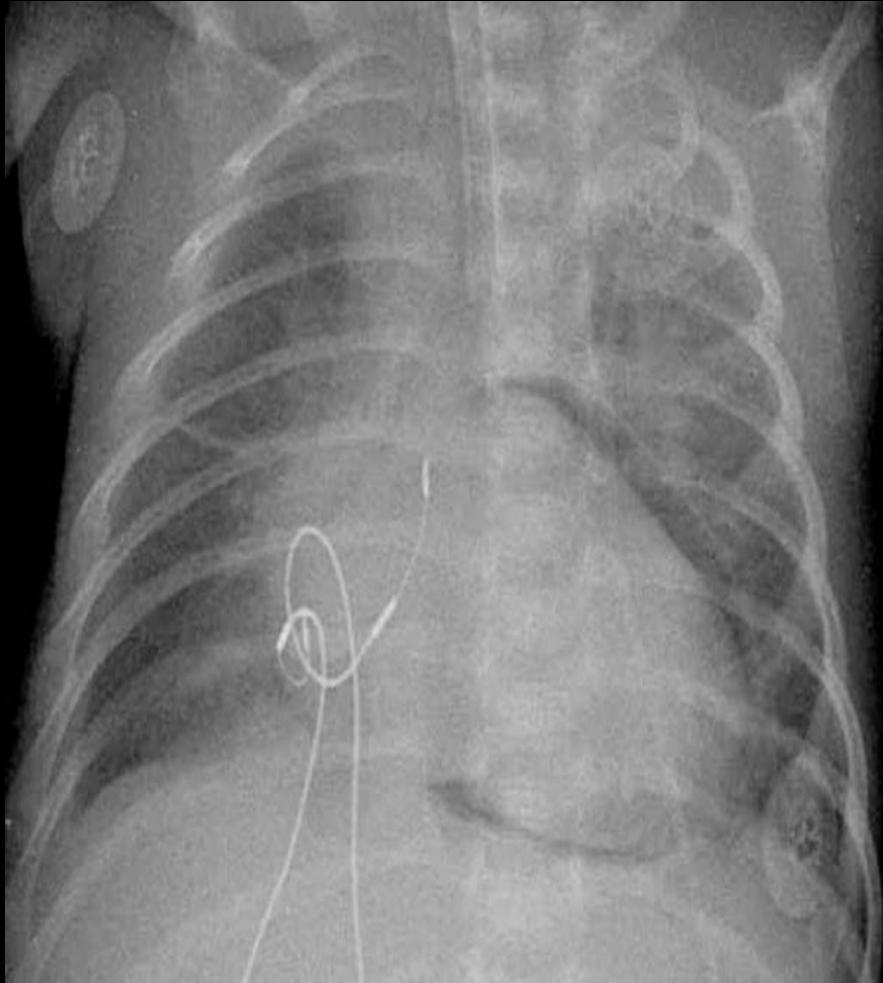
Management of Hilum, Mediastinum, Diaphragm, Pleural, Chest Wall

- 病史與檢驗：
- 種類：感染、外傷、腫瘤、先天。
- 定位：位置（前中後，肺內外）
- 電腦斷層、顯影劑
- 危險：氣道、血管（避免切片）、感染、外傷
(airway, pneumothroax; embolism, aorta, pericardium; acute mediastinitis, etc)
- 追蹤：

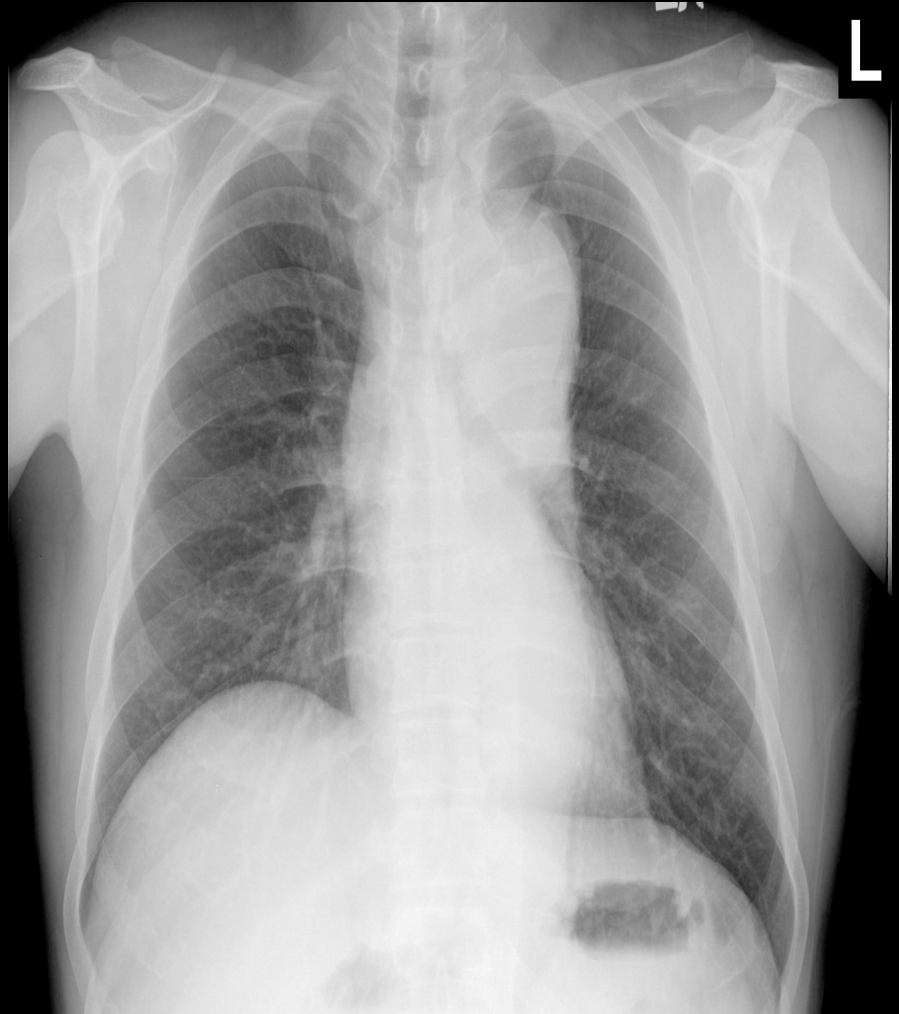
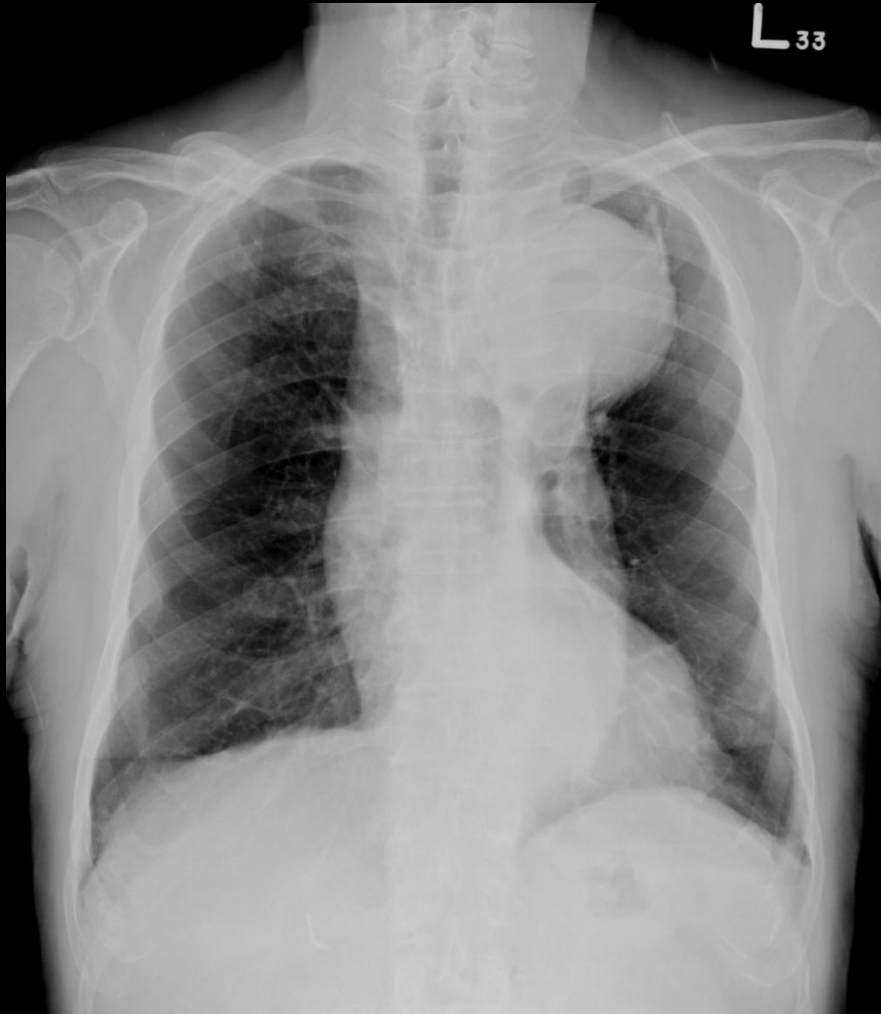High risk of hilum, mediastinum lesions 1



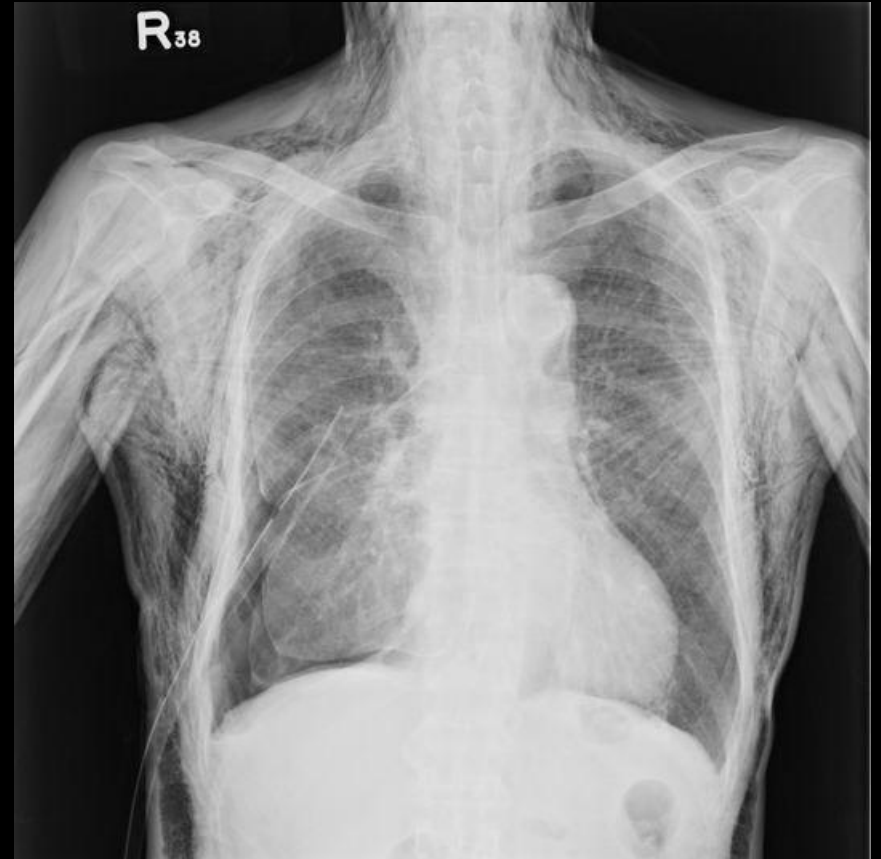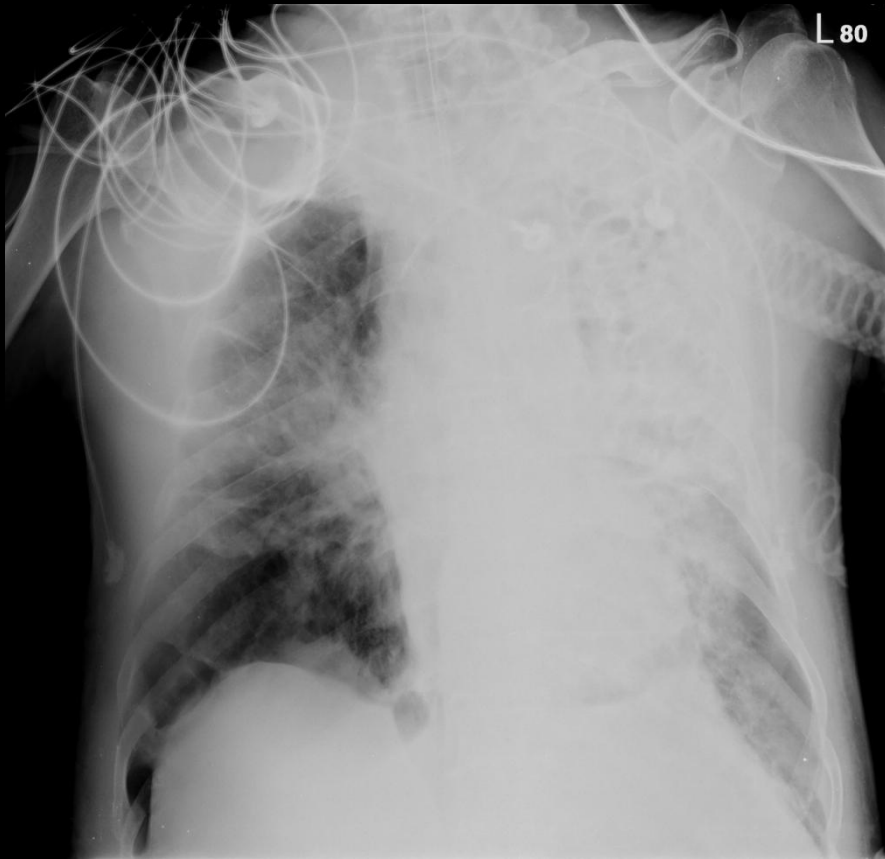
High risk of hilum, mediastinum lesions 2



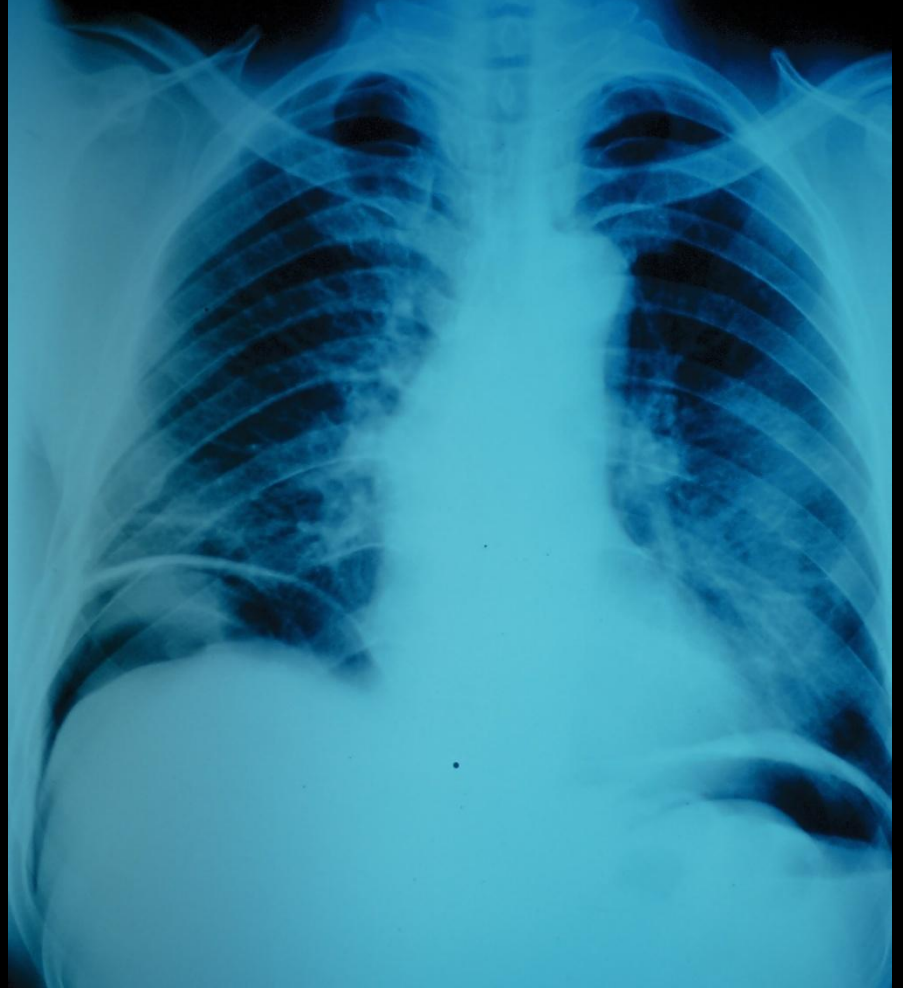
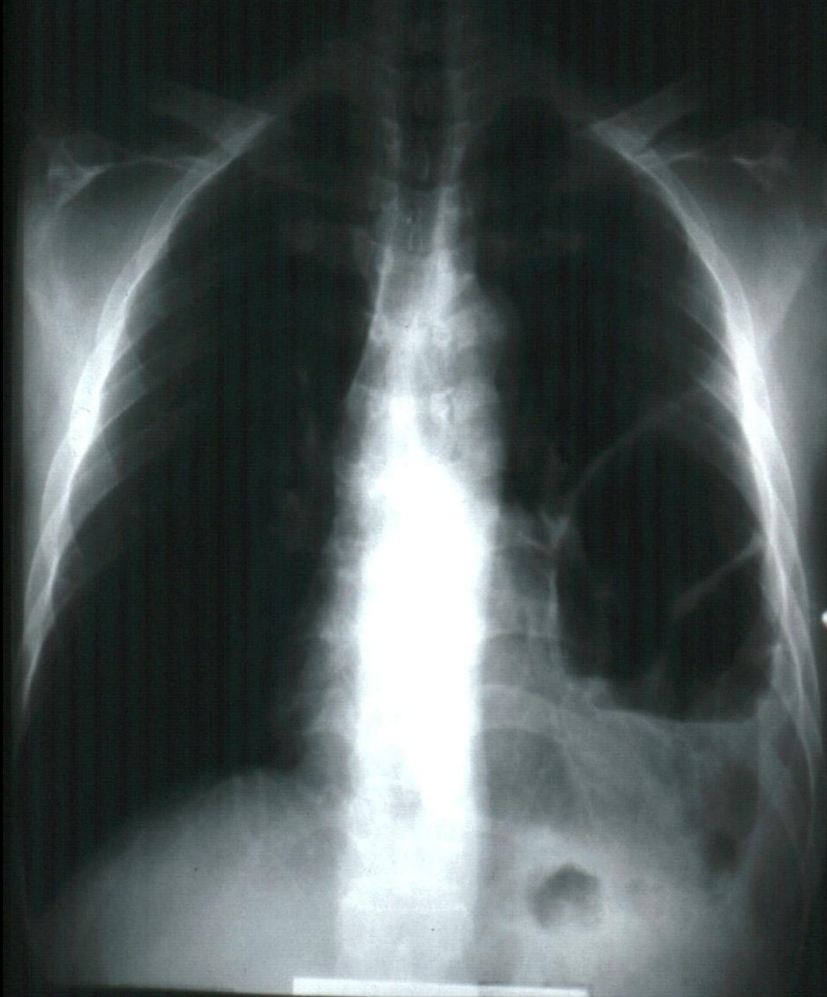High risk of hilum, mediastinum lesions 3



High risk of hilum, mediastinum lesions 4



High risk of hilum, mediastinum lesions 5





Thanks for your attention !

