

111年胸部影像判讀繼續教育課程

The Interpretation of Chest Radiograph

胸部X-ray影像判讀原則與常用徵象

臺北榮總胸腔部

江起陸

2022/5/1

感謝黃立果/羅柏鈞醫師投影片的傳承

胸部X光片判讀要領

- 片子本身
 - 病人基本資訊
 - 照相品質
 - 照相姿勢
- 相關知識
 - 了解正常解剖學構造及影像
 - 以 **pattern** 作為鑑別診斷的依據
 - 了解疾病的典型及非典型之影像表現
- 判讀技巧
 - **固定且系統性的判讀順序**，避免遺漏
 - 比較不同階段的影像，以病灶的時序變化作為鑑別診斷的依據
 - 利用不同照相姿勢
 - 搭配臨床資訊

照相原則

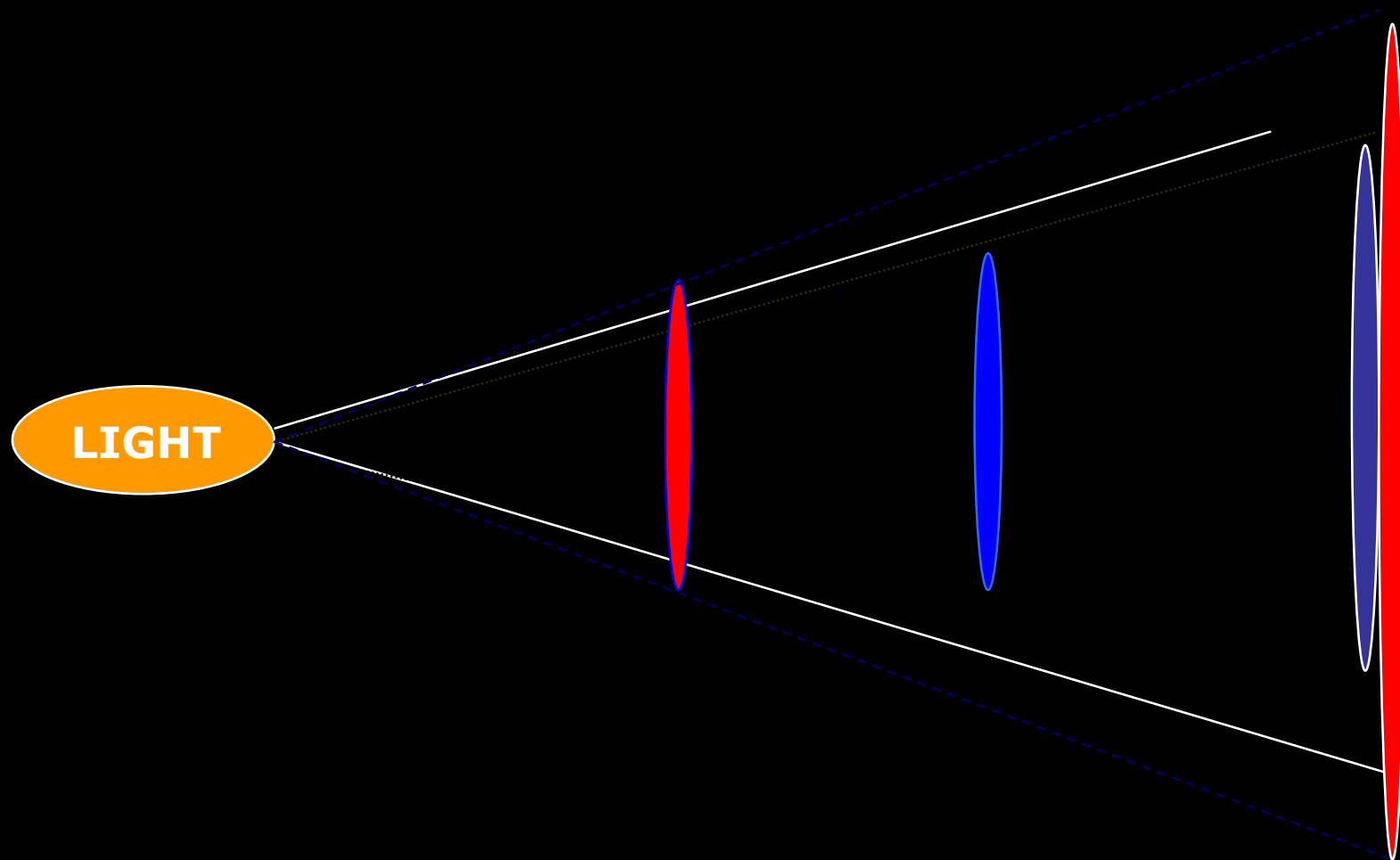
常見CXR的照相方式

■ Routine

- PA (standing) view
- L't lat view, R't lat view

■ Non-routine

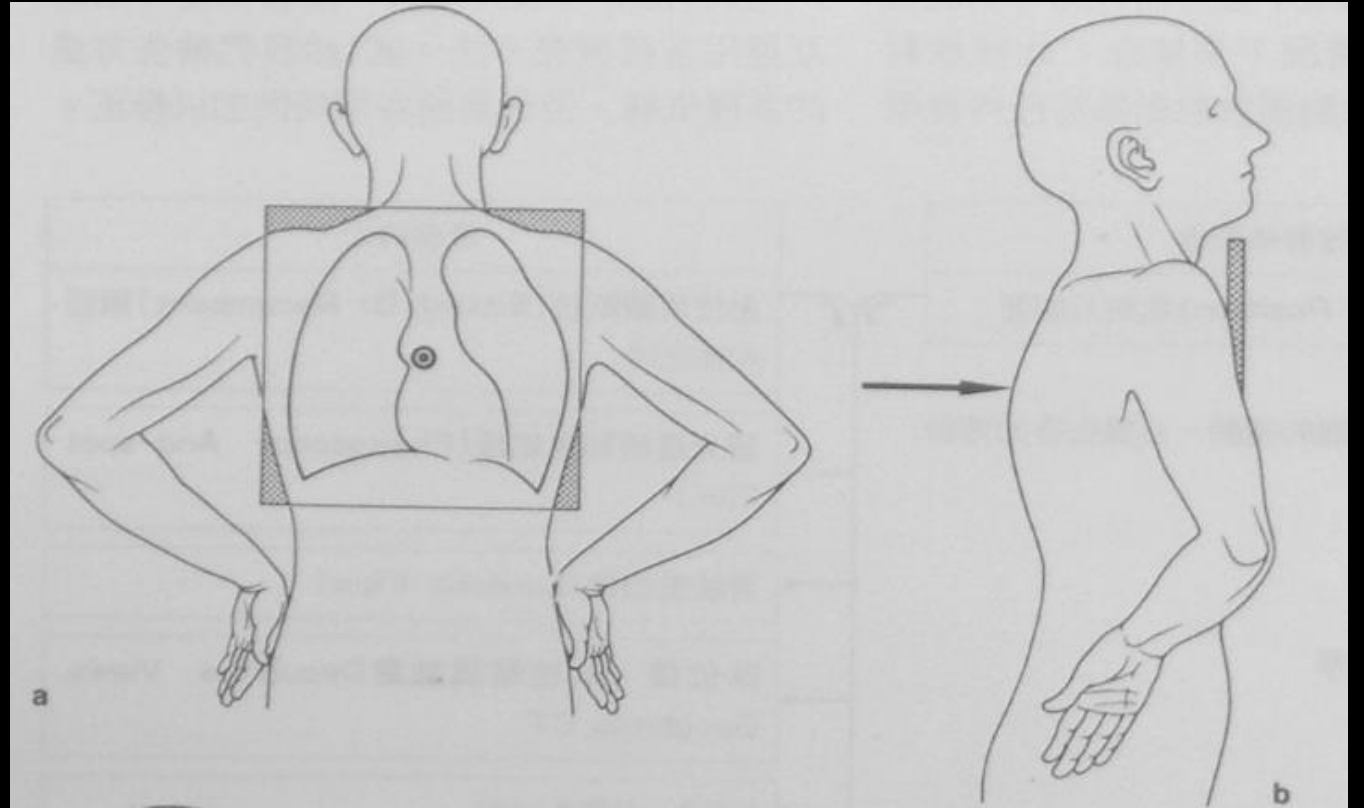
- AP (supine) view
- L't decubitus view, R't decubitus view
- Lordotic view



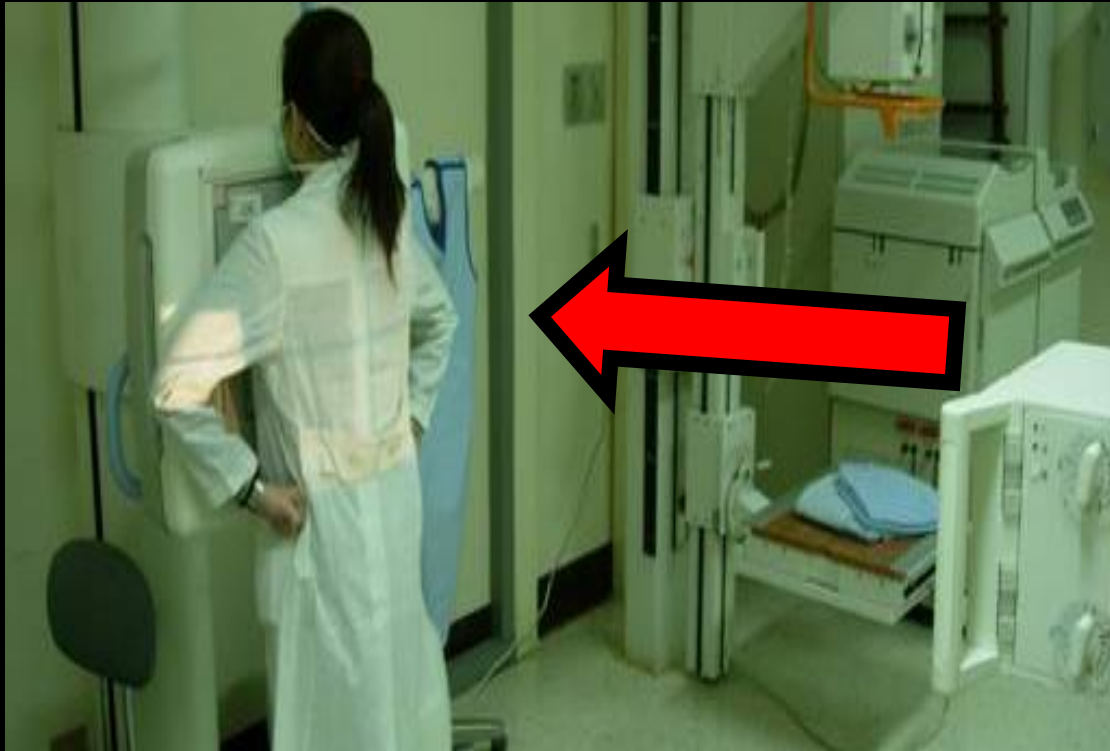物體離光源越近 投射陰影越大

Frontal view (PA view)

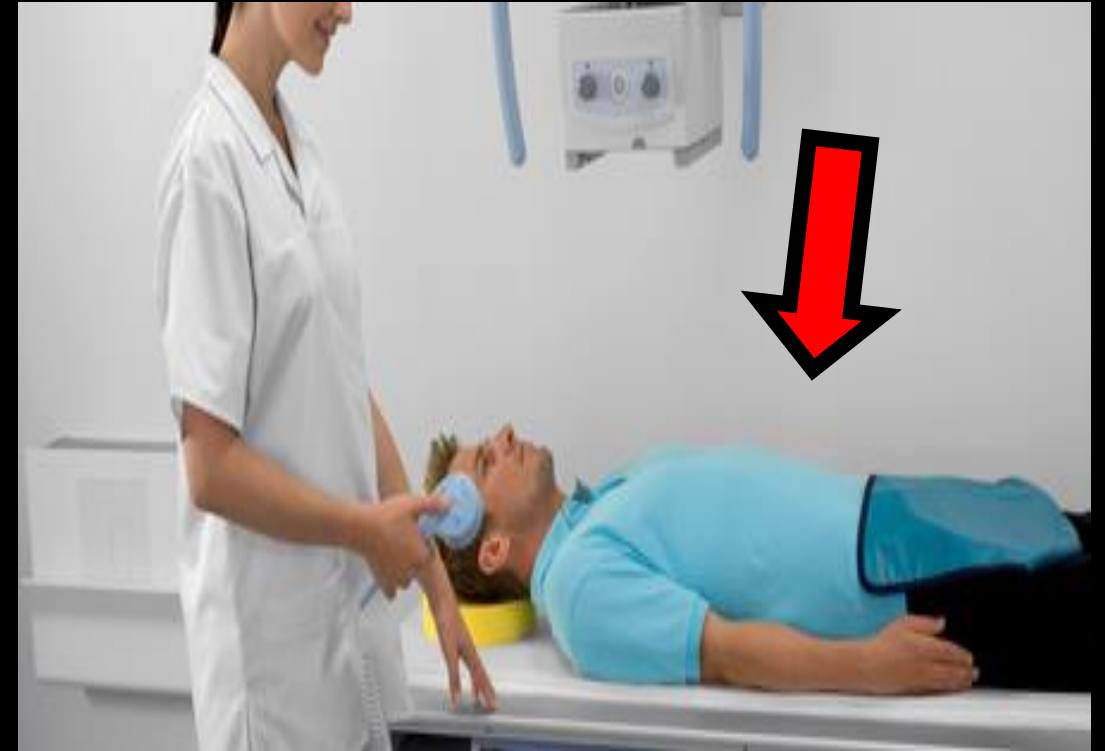- PA (post-ant.)
- 距離射源6英尺
- 胸部抵住置片箱
- 手背放在腰部
- 手肘盡可能向前
壓把肩胛骨移開
肺野區
- 吸飽氣，閉住氣



Frontal posterior-anterior
(PA) view

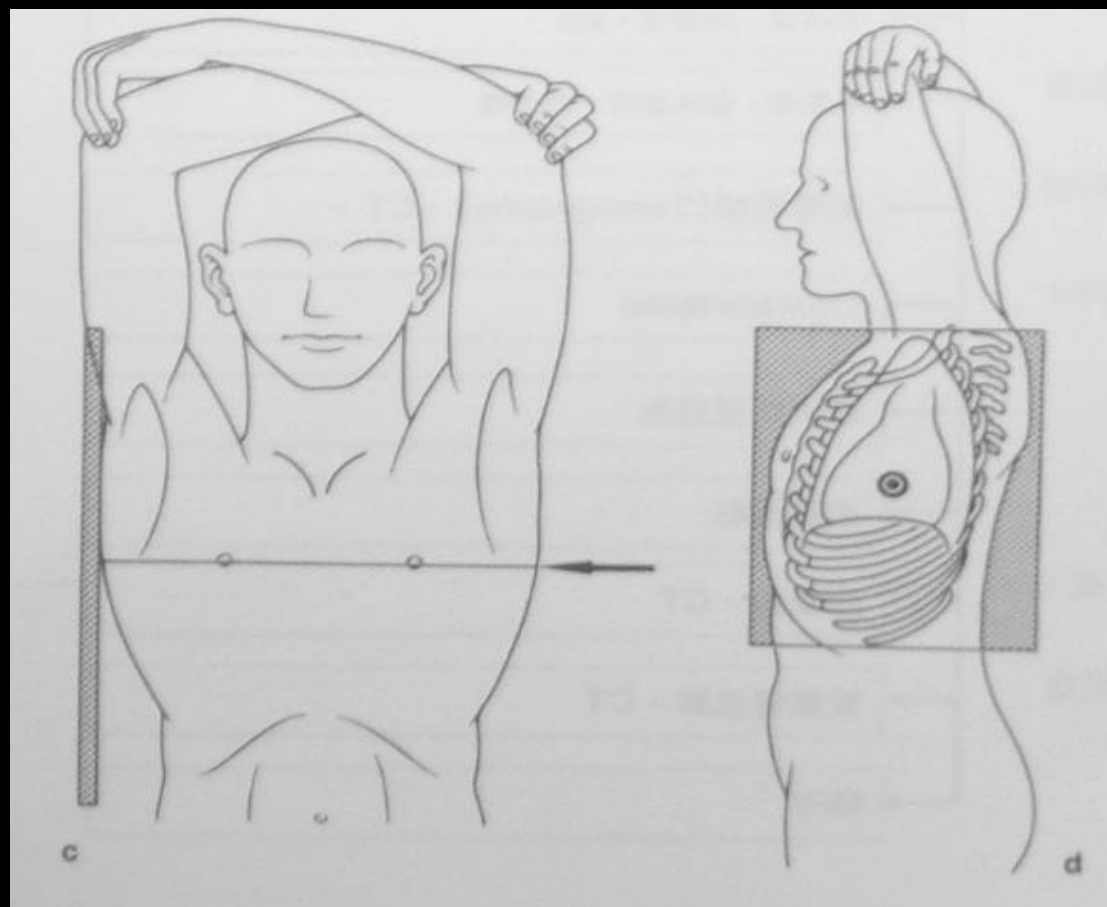


Frontal anterior-posterior
(AP) view (supine)



Lateral view

- 舉高雙臂
- 於深吸氣時攝影
- X-ray dosage為PA view的**2~3倍左右**
- 看病灶位置選擇，如果lesion在左邊，則安排left lateral view.

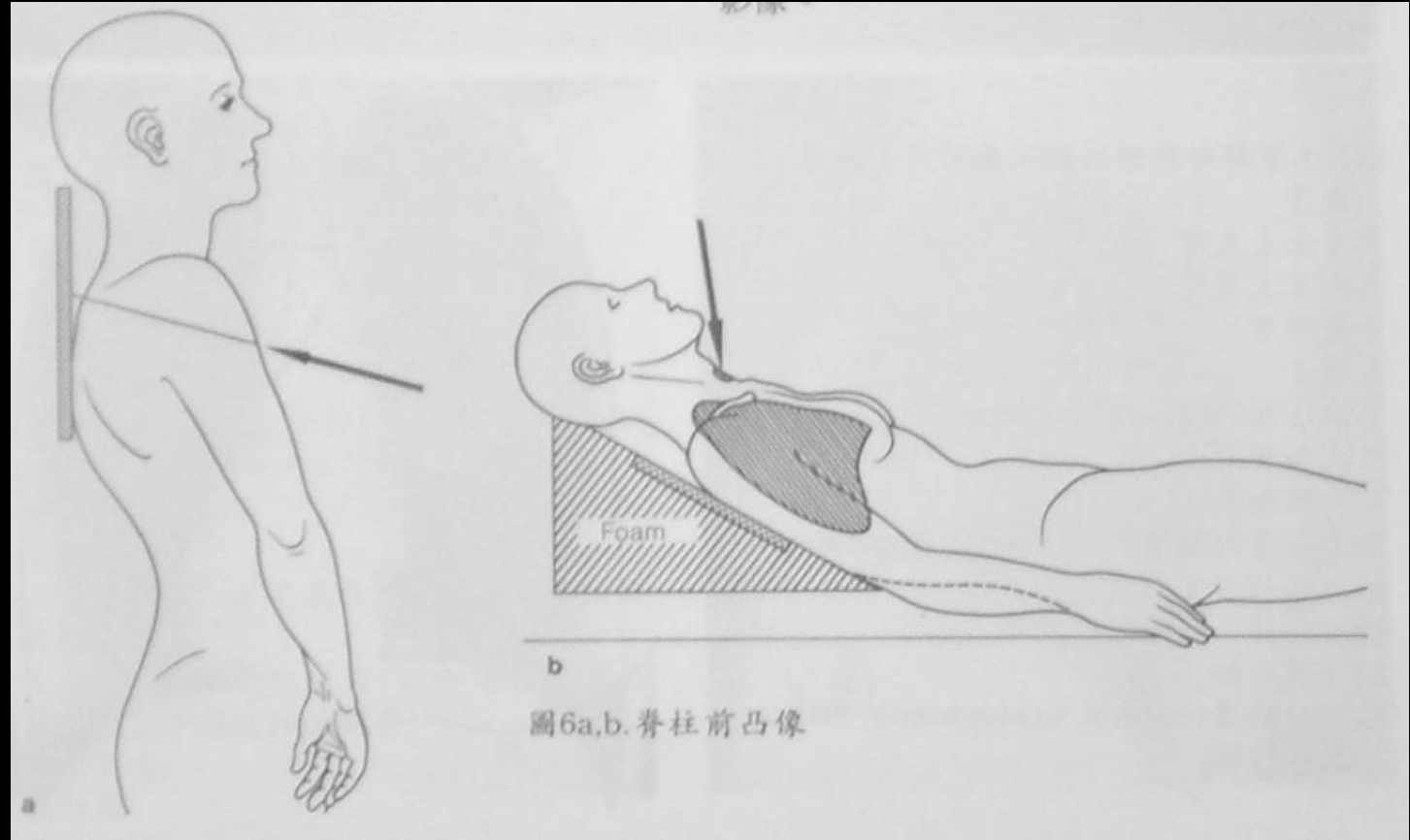


Left lateral view



Lordotic view

- 傾斜上半身約30度，使肩部靠近置片箱
- 用來確認在正面照容易被肋骨遮蔽區域的病灶
 - 肺尖
 - 右中葉
 - 左肺舌葉

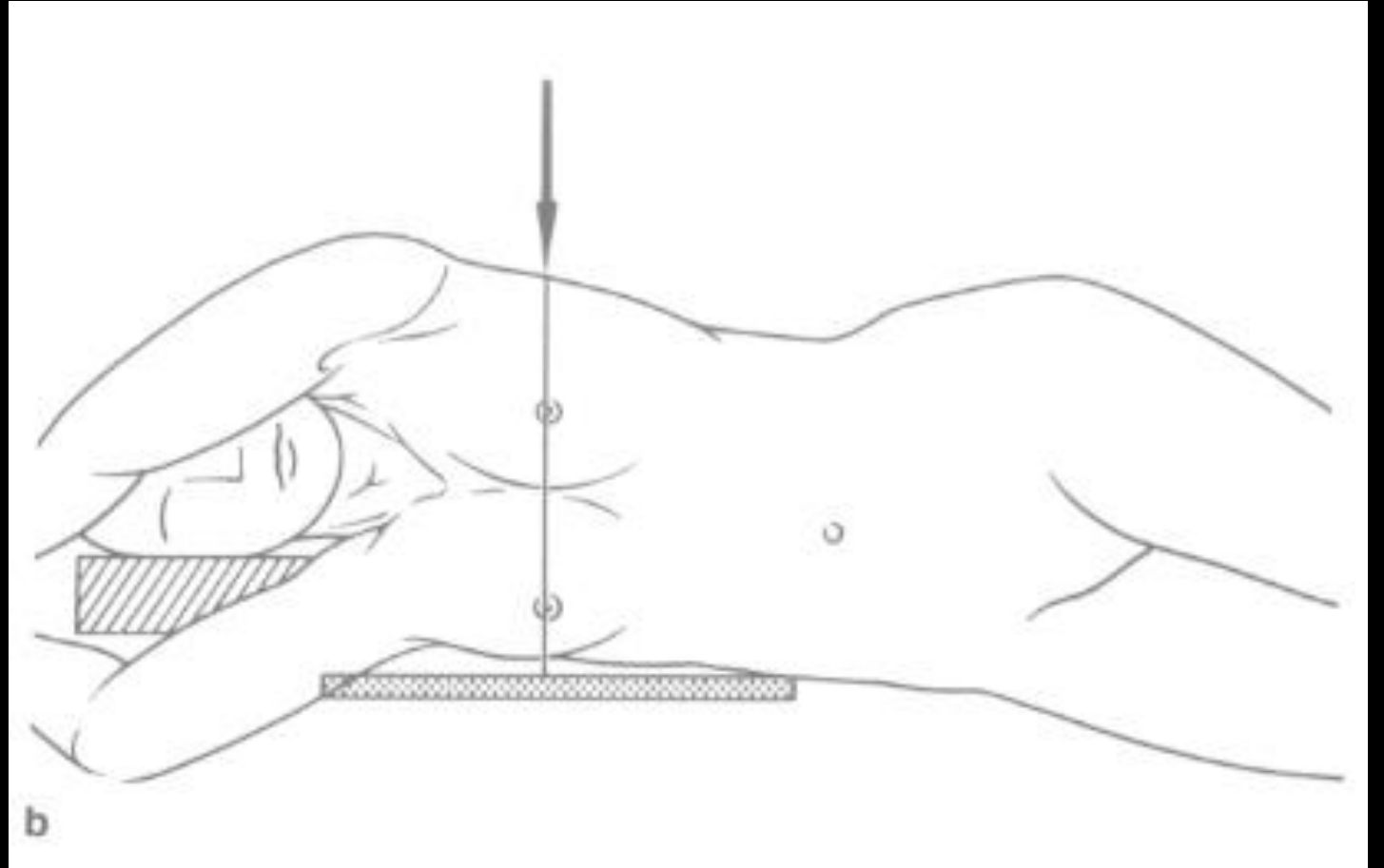


Lordotic view



Decubitus View

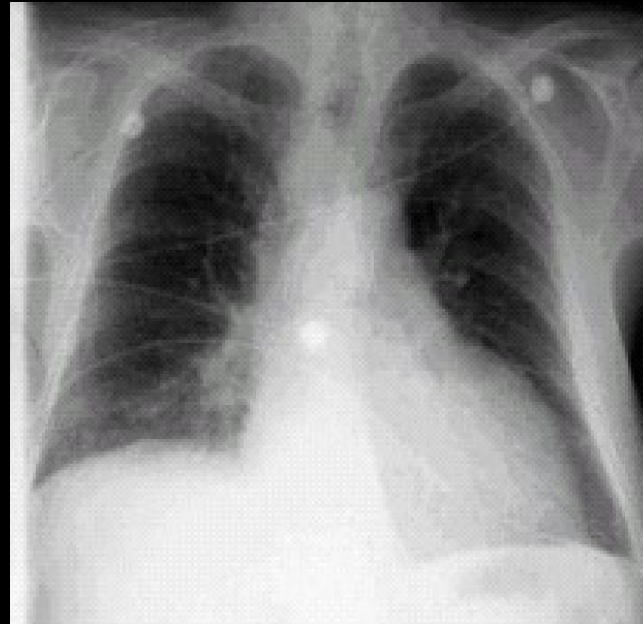
- DDX for **costophrenic (CP) angle blunting**
- ✓ Pleural effusion.
- ✓ Pleural thickening.
- Detect **pneumothorax**
- Detect **ball-in-hole sign**
- ✓ Mycetoma.



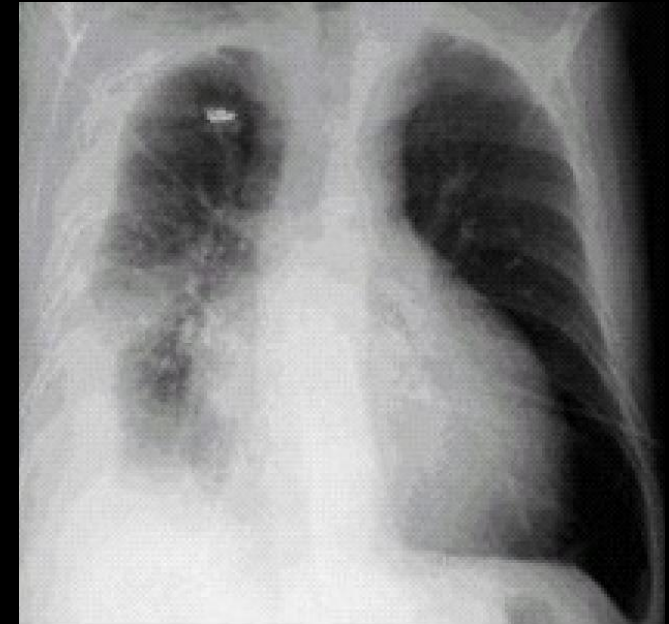
Decubitus view: which side down?

- 通常是患側要朝下
 - 看的是air-fluid level
- 如果CP angle blunting的程度輕微，可考慮健側朝下
 - 看的是CP angle是否重新露出來

Right subphrenic pleural effusion



Frontal PA view

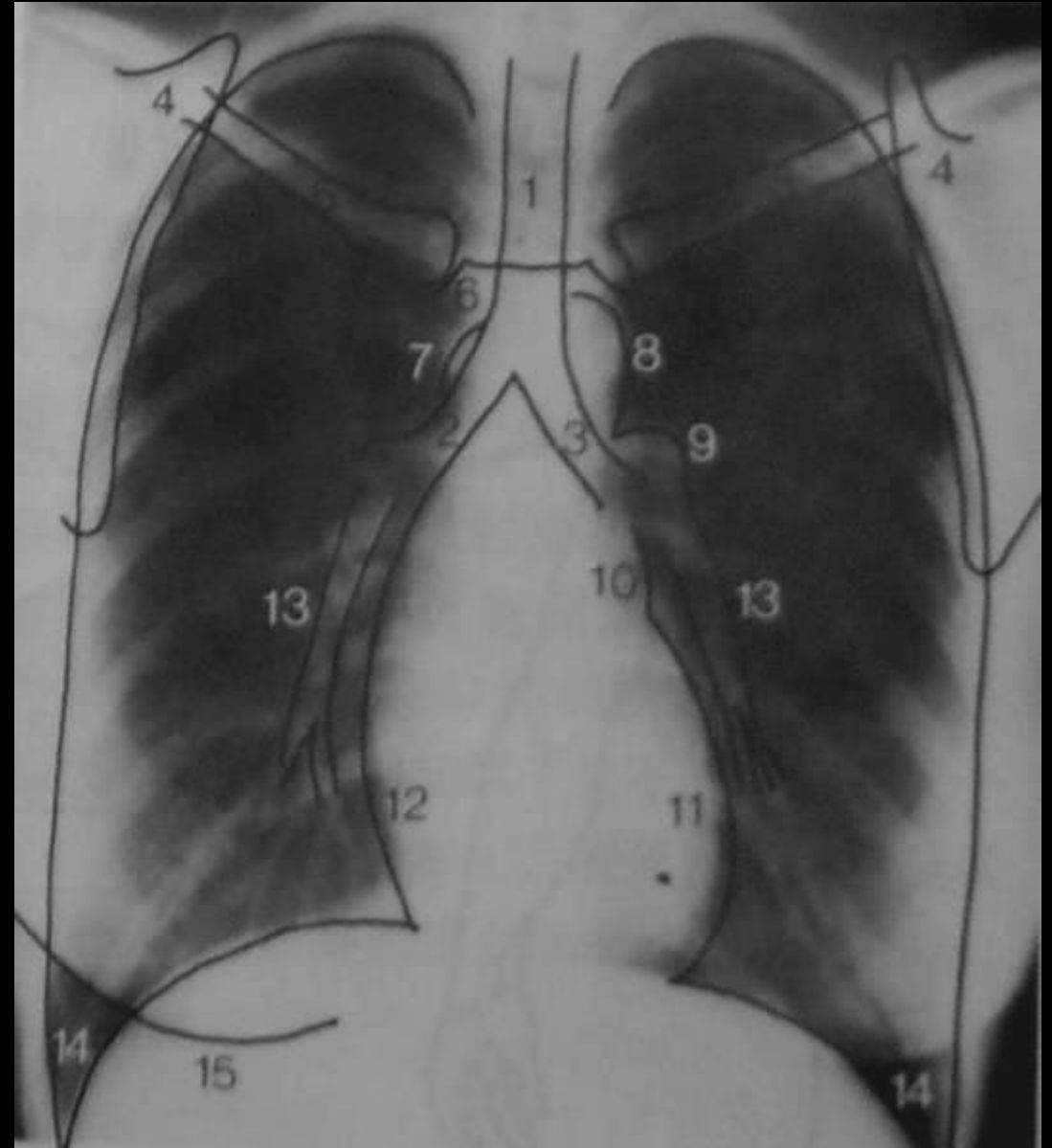


Right decubitus view

解剖構造

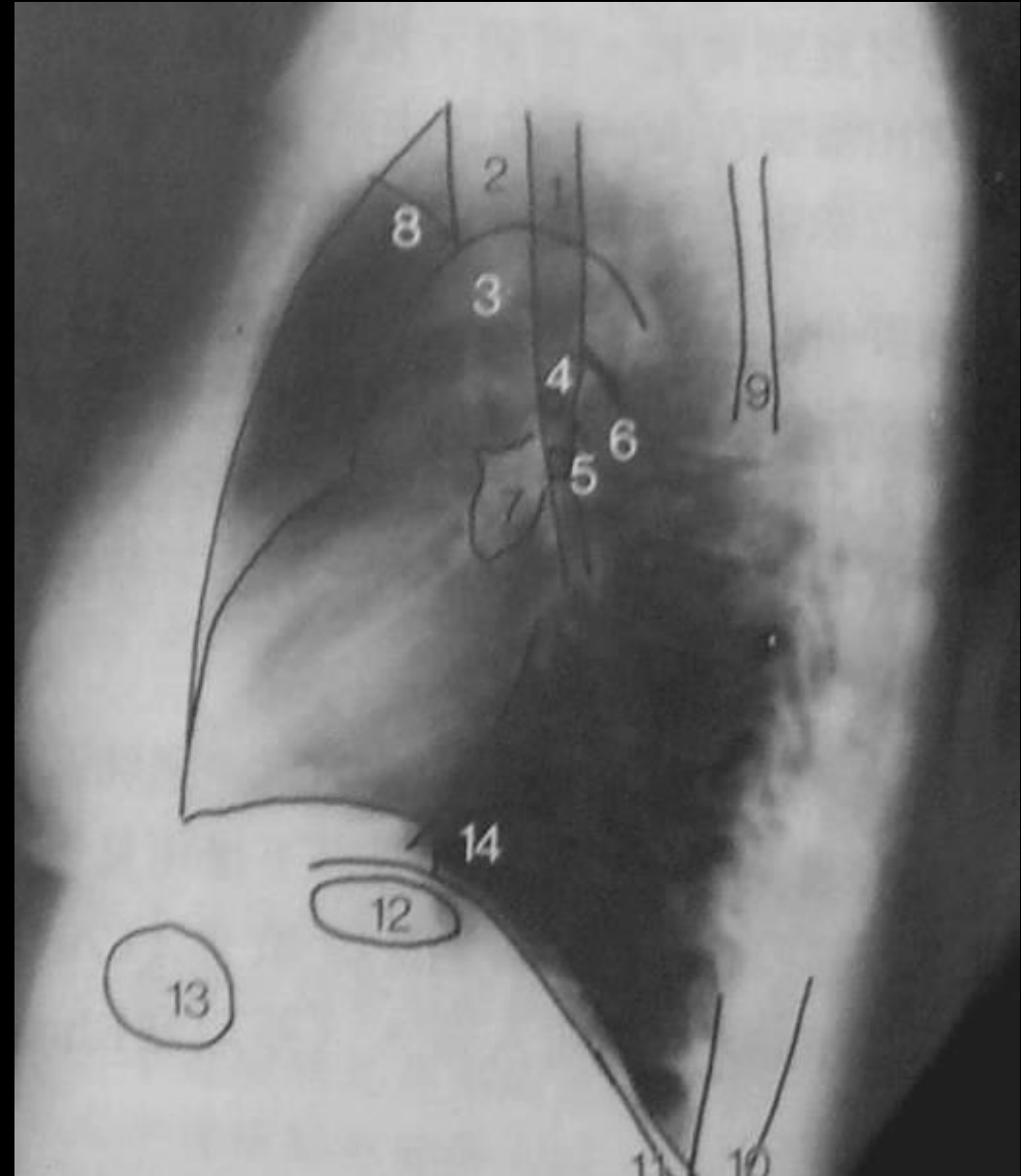
Frontal View

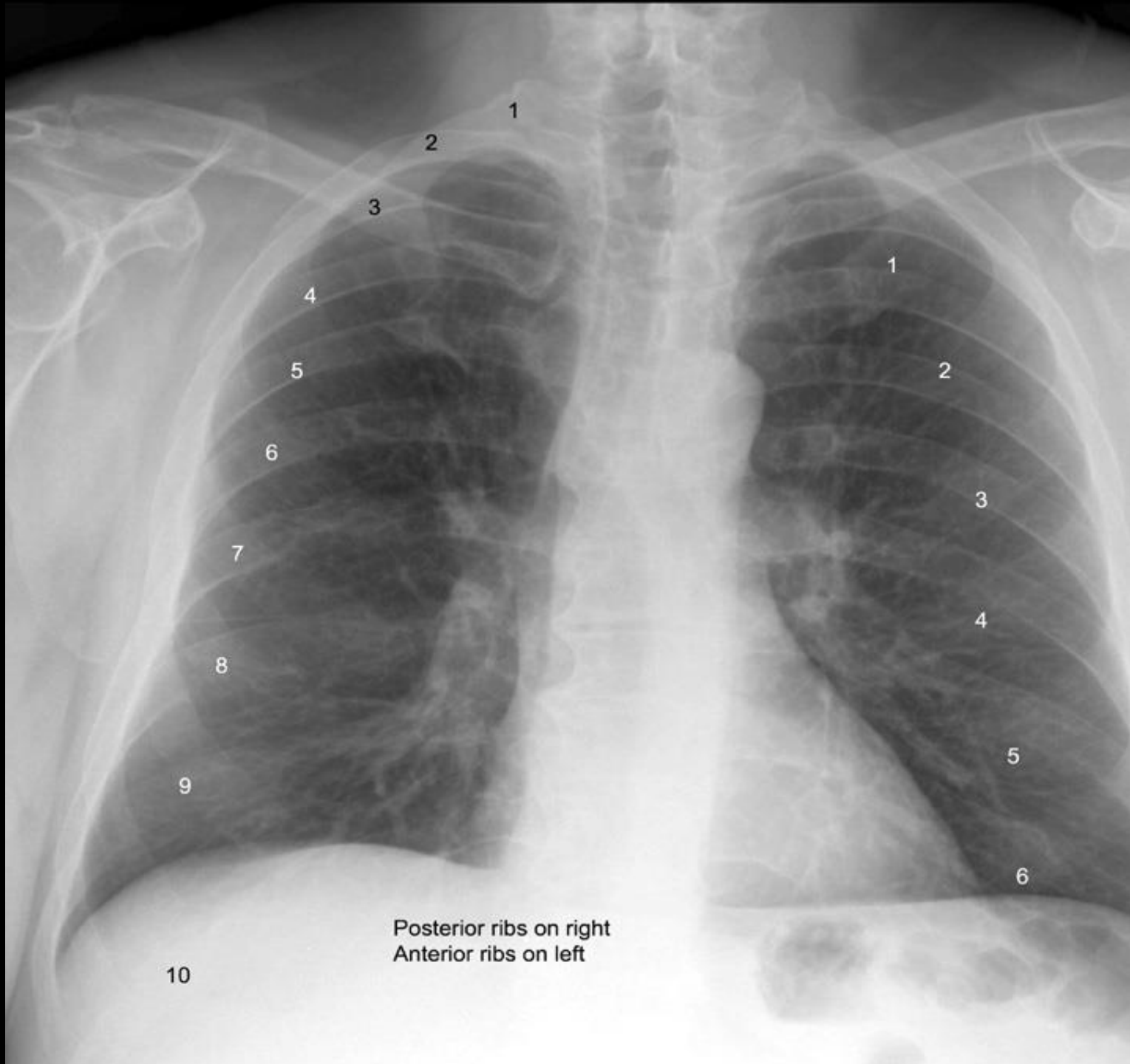
1. Trachea
2. Right main bronchus
3. Left main bronchus
4. Scapula
5. Clavicle
6. Manubrium Sterni
7. Azygous vein
8. Aortic arch
9. Left pulmonary artery
10. Left atrial appendage
11. Left heart border
12. Right heart border
13. Interlobar pulmonary artery
14. Costophrenic angle
15. Breast shadow



Lateral View

1. Trachea
2. Pretracheal vascular bundle
3. Aortic arch
4. RUL bronchus orifice
5. LUL bronchus orifice
6. Left pulmonary artery
7. Right pulmonary artery in pretracheal oval
8. Axilla
9. Scapula
10. L't C-P angle
11. R't C-P angle
12. Gastric bubble
13. Transverse colon
14. Inferior vena cava

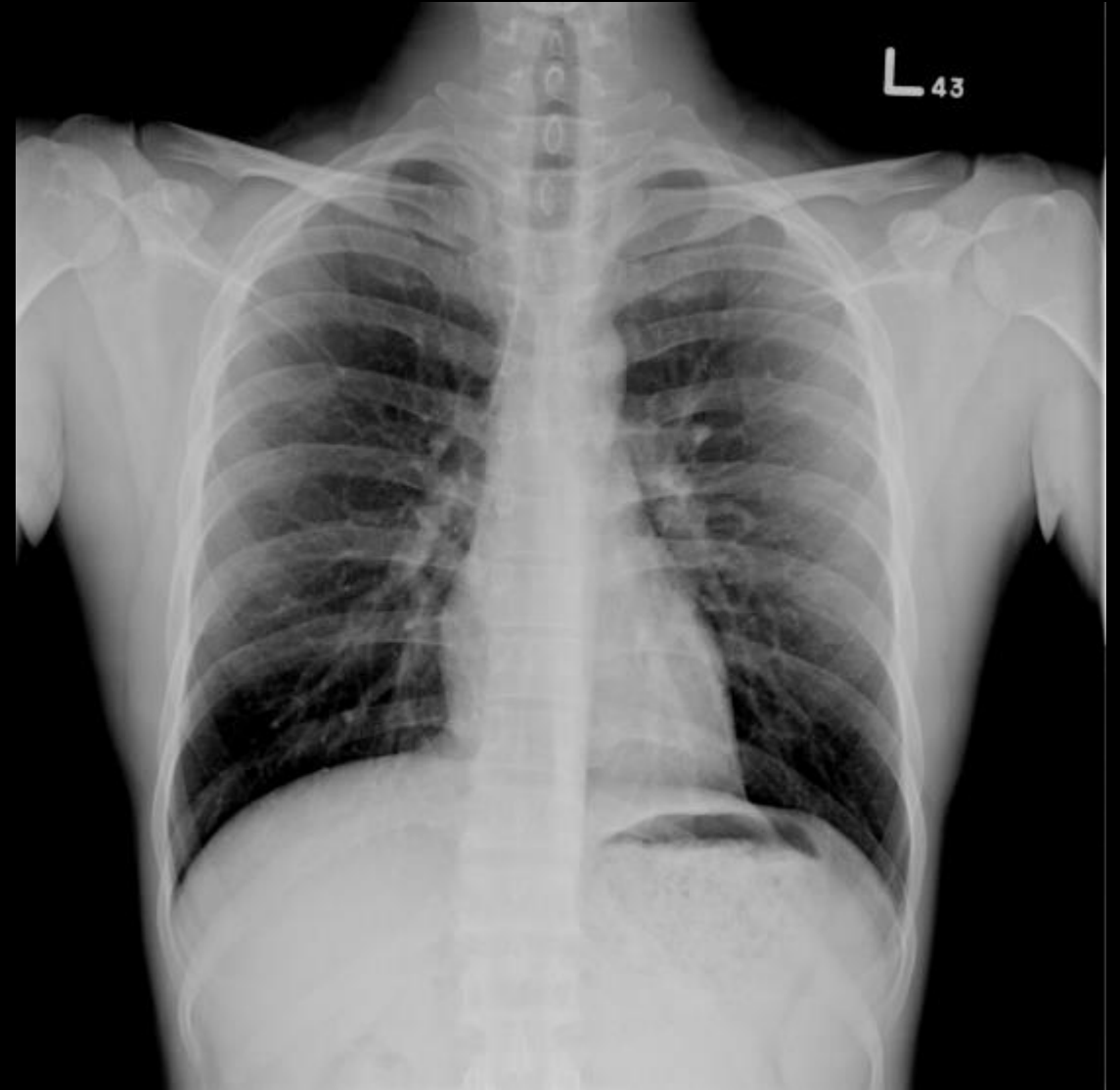



閱片前重點

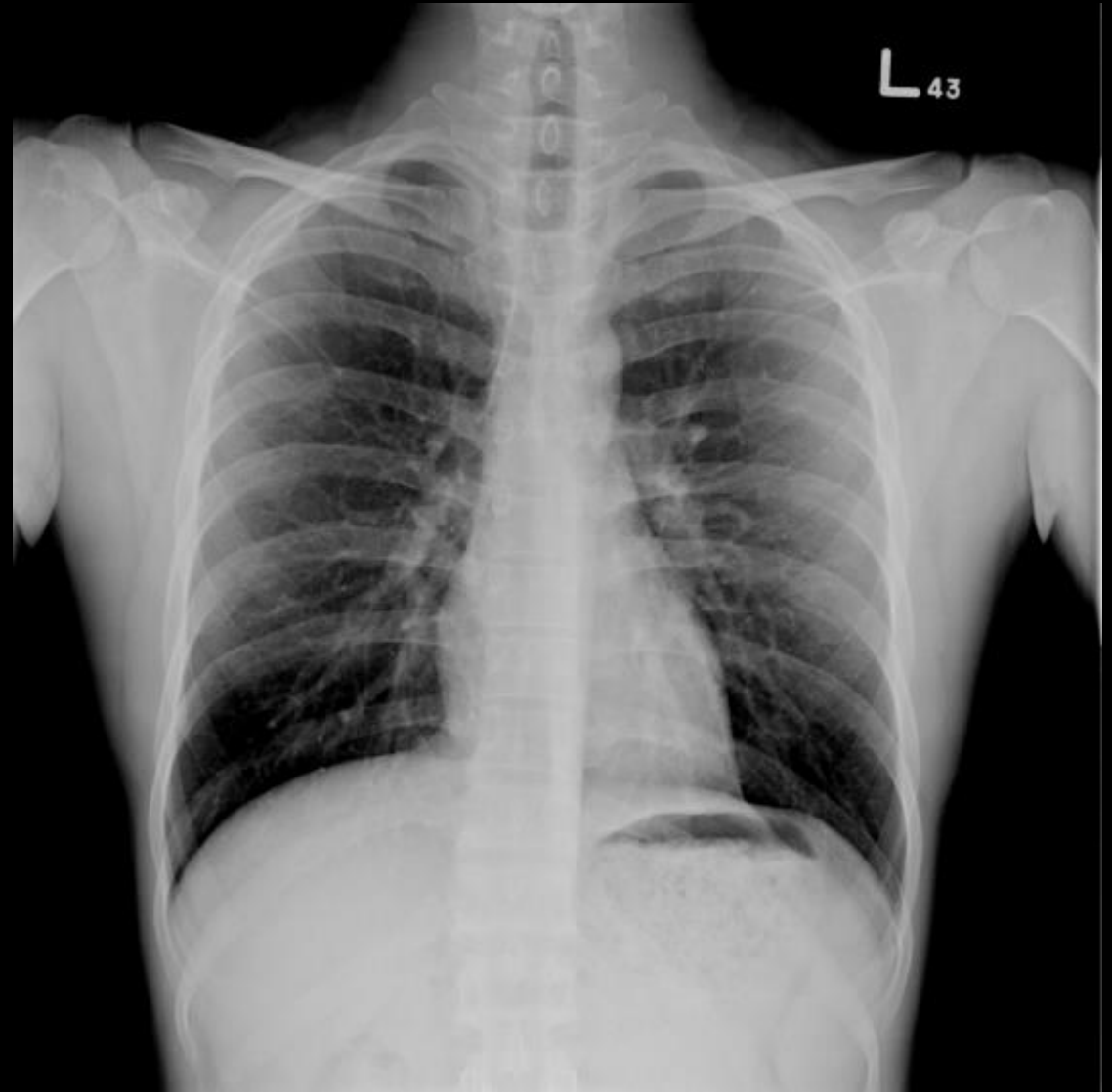照相品質好不好

- 1. 片子夠大: 應該涵蓋
 - Neck: 以免loss trachea 病變
 - 胸廓: 以免loss soft tissue/ bony lesions
 - Diaphragm: sub-diaphragm lesions, 如liver, gastric bubble
 - Bil CP angle: 以免loss少量P.E.
- 2. 吸氣充足:
 - 正常PA view : diaphragm中心點與肋骨交會(前6後10)
- 3. 曝光適當

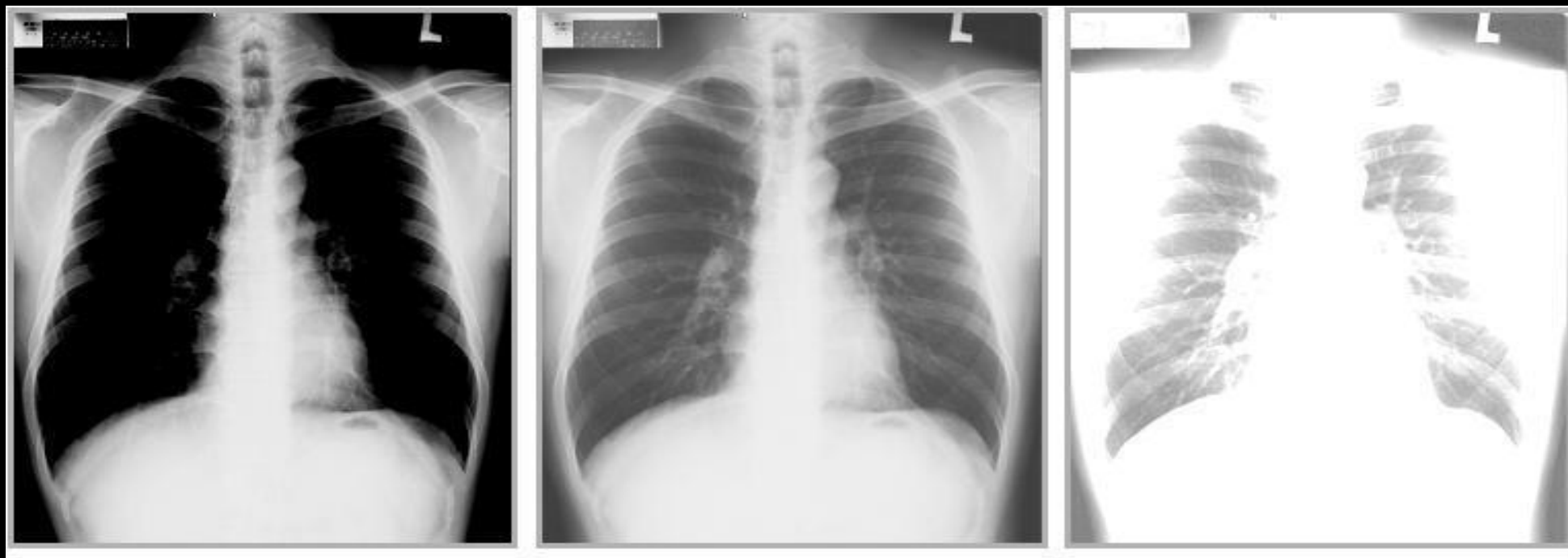

如何判斷曝光好不好？

- Trachea與carina隱約可見
- 下段vertebra清晰可見
- 脊柱間盤隱約可見
- 心臟後與橫膈下方的肺紋可識
- 兩側肺紋至外三分之一清晰可見



曝光良好的CXR

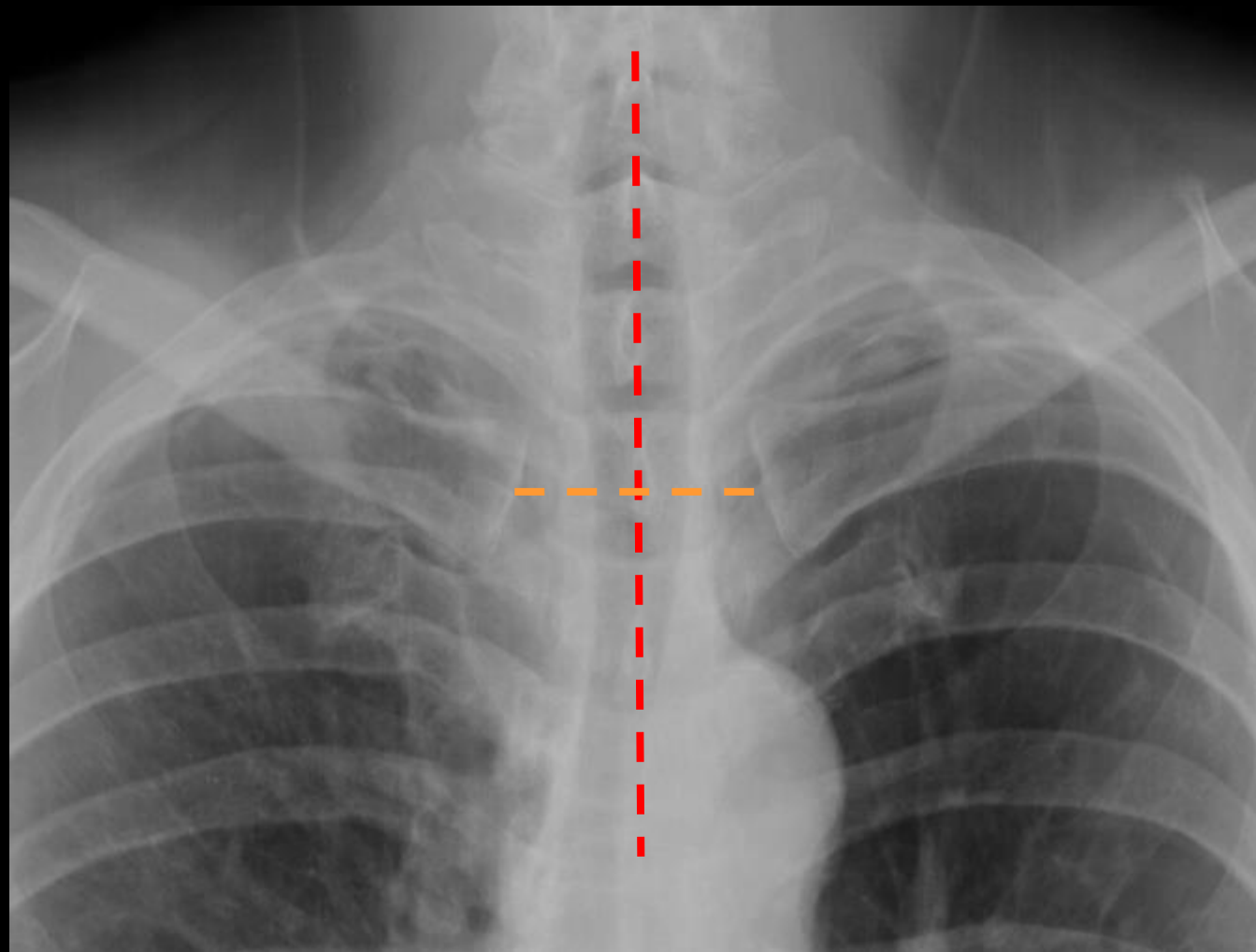


- 曝光太強:過黑，會miss tiny lesions
- 曝光適當
- 曝光太弱:過白，會miss 縱隔腔內、心臟後的病變

照像姿勢好不好(正不正)

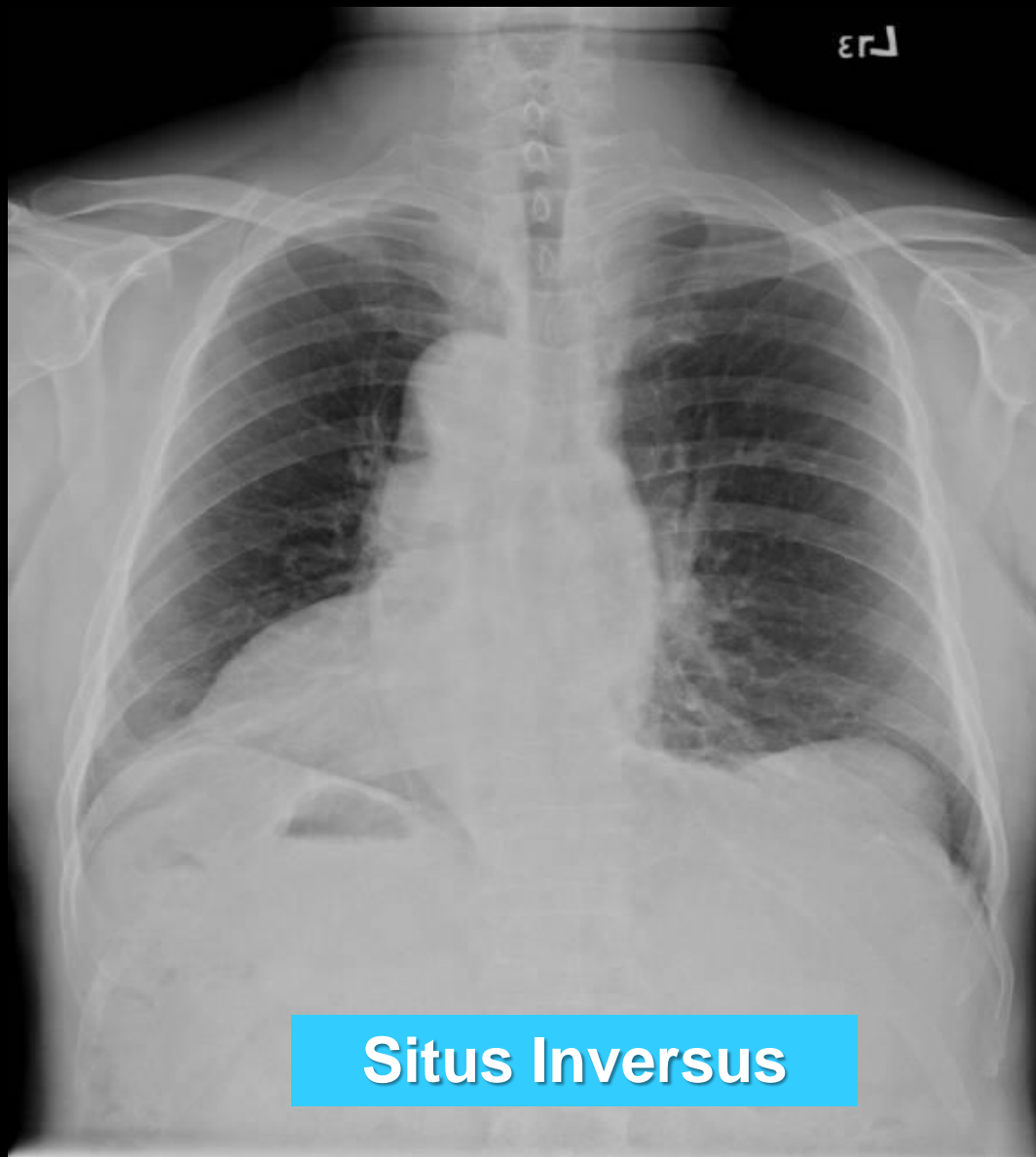
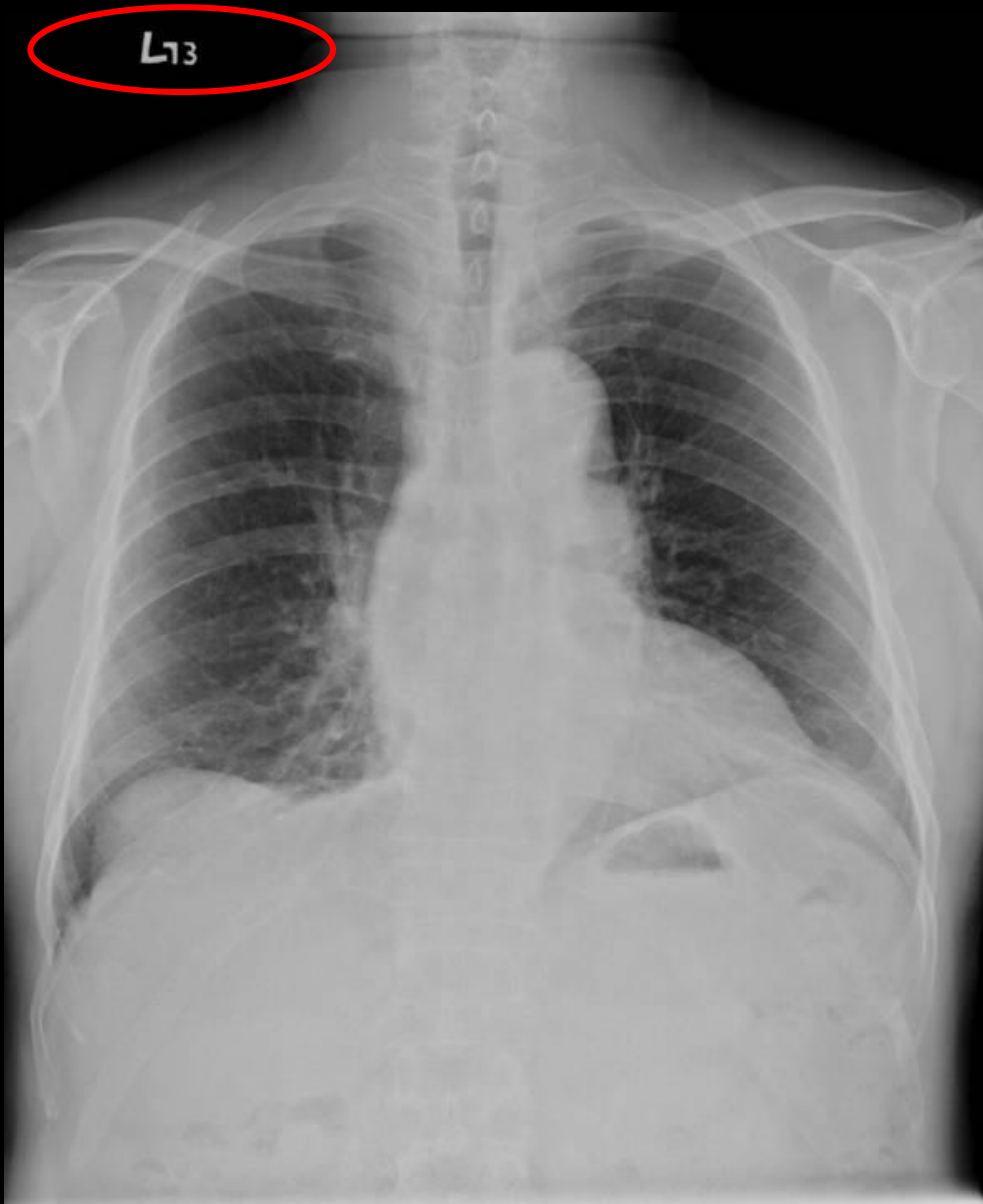觀察重點：

- **Spinal process** 是否在兩鎖骨的中線
- **氣管** 是否居中(較不一定,因氣管可能受 **mediastinum** 的影響)



開始判讀前的基本資訊

- 確認病人的姓名、病歷號及申請單號碼
- 確認左或右的字牌
- 做全般性的觀察(general screening)



General Screening

■ 照相的體位(standing or lying)

■ 觀察重點：

- Scapular有沒有打開：看**tip of scapula**

- Clavicle走向：站著照**clavicle**比較平，躺著照**clavicle**會變斜上揚

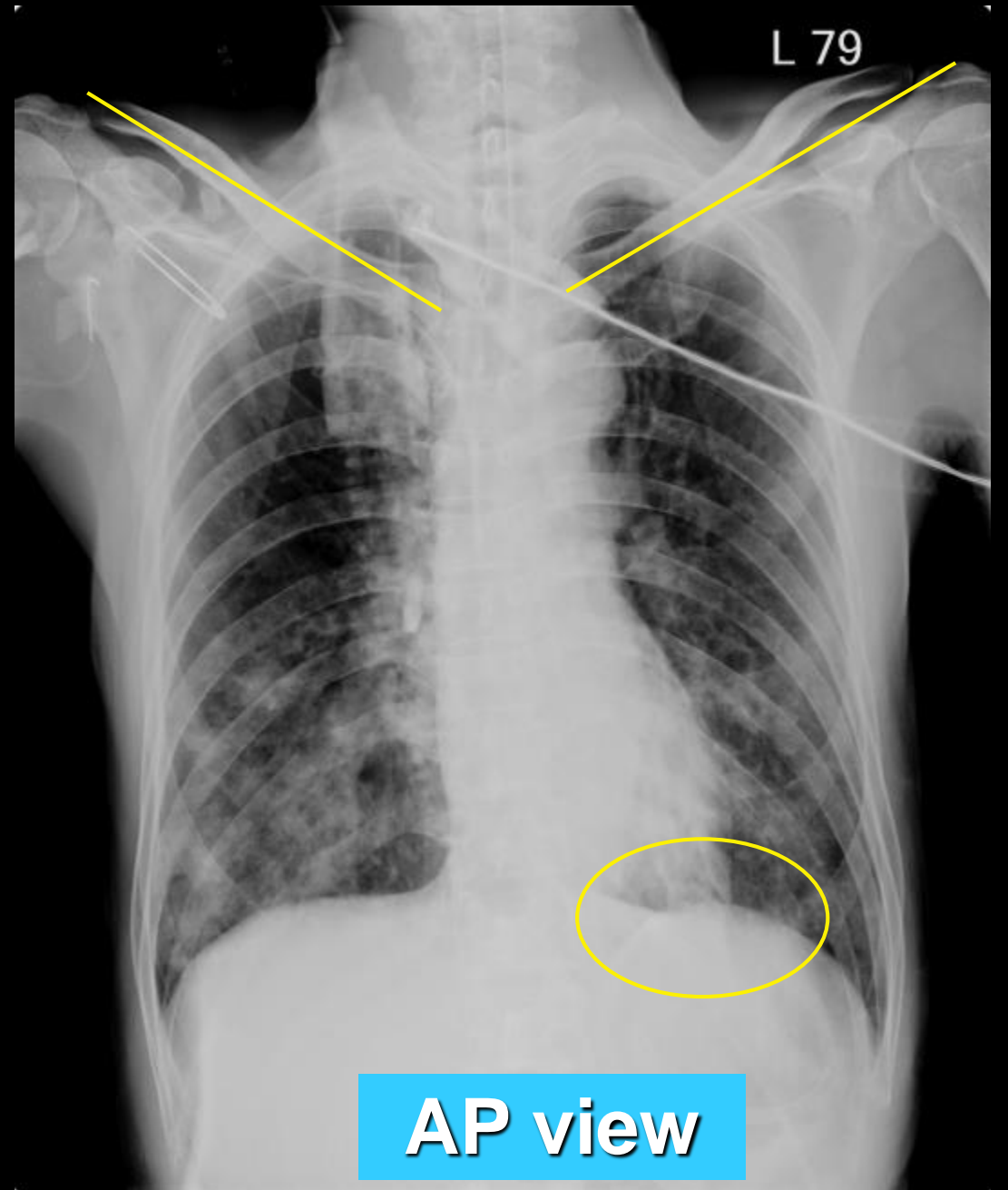
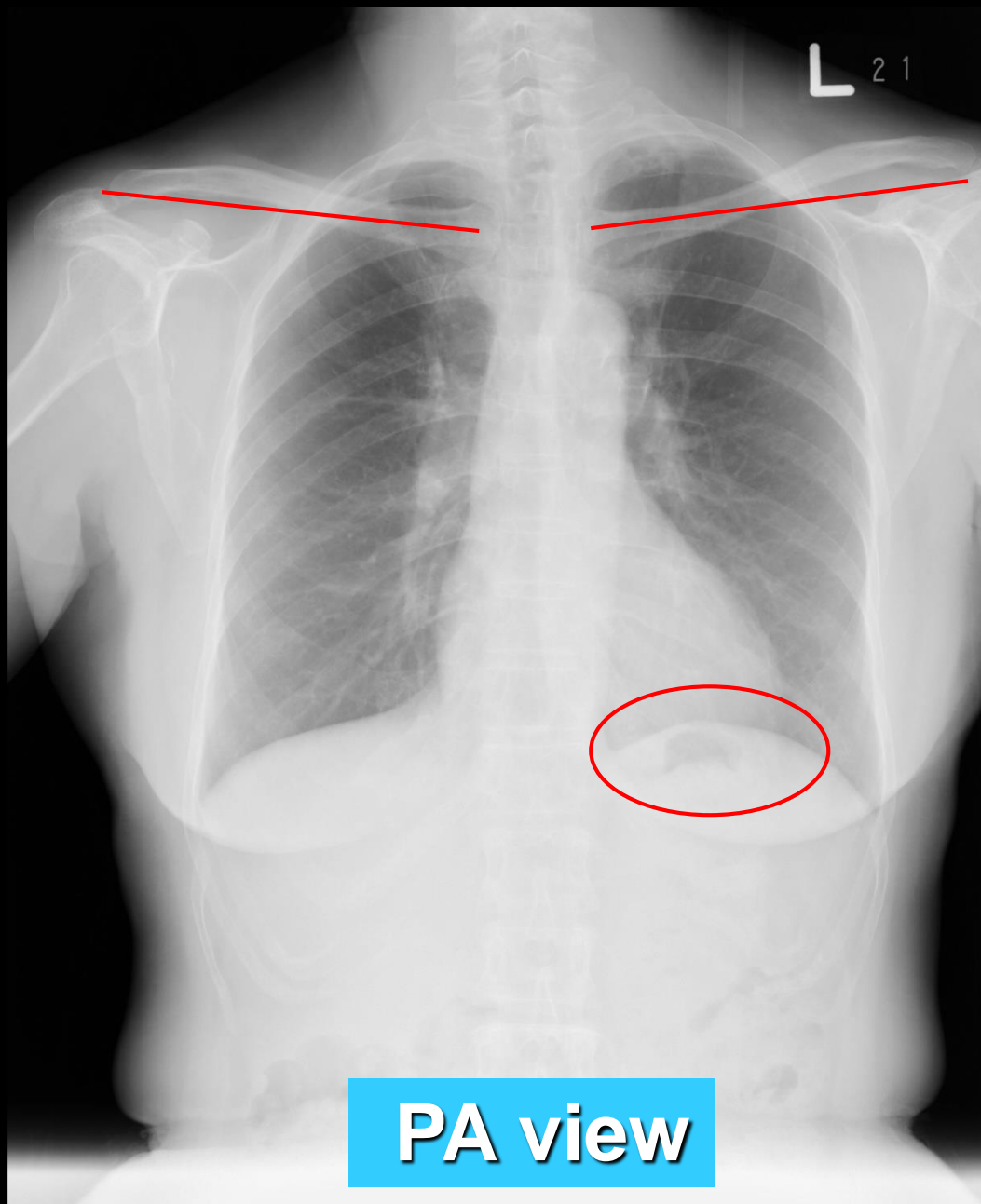
- Gastric-bubble內是否有**air-fluid level**

- 通常躺著照相，表示病情較為嚴重。

■ 年齡

- 第一根肋軟骨鈣化: **30-40 y/o**

- Tortuosity of aorta & calcification of aortic knob: **50-60 y/o**




閱片順序

Alphabetical approach

- **A**irway: tracheobronchial tree
- **B**one: thoracic skeleton
- **C**ardiac: heart and mediastinum
- **D**iaphragm: diaphragm and costophrenic angle
- **E**xtrapulmonary: soft tissue, neck, upper abdomen, etc
- **F**ield: lung field
- **G**astric: gastric bubble
- **H**ilum: hilum and pulmonary vessels


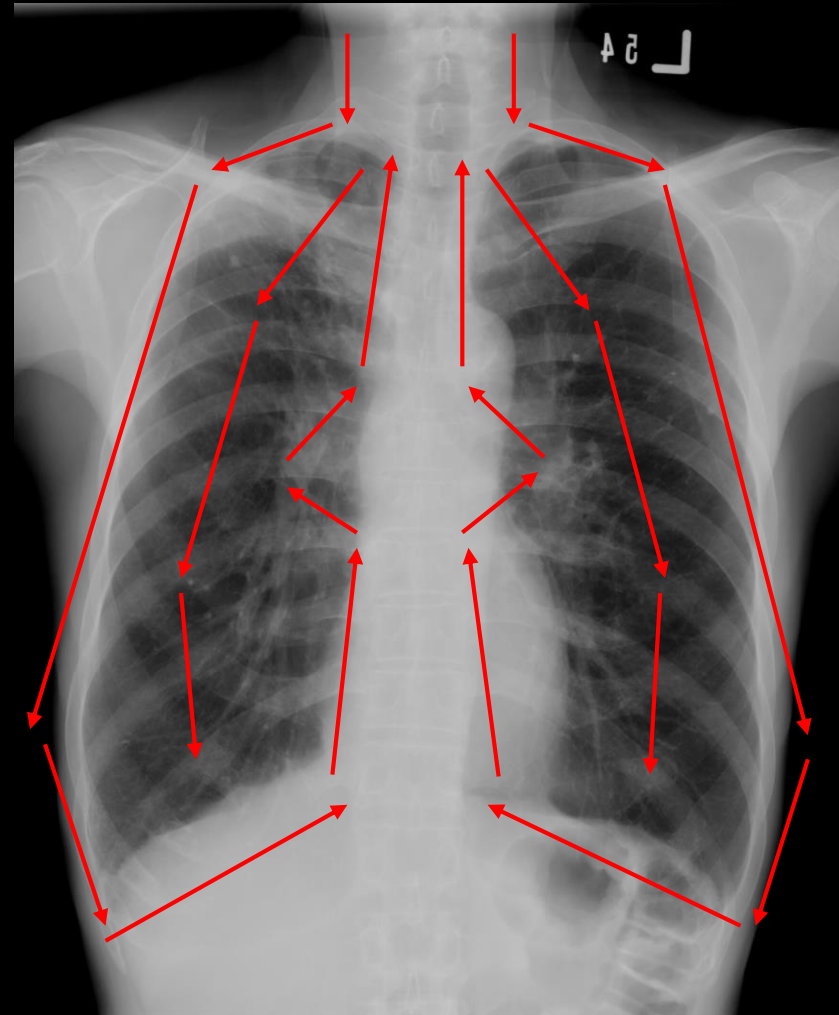
Felson's approach: Are There Many Lung Lesions

- Thorax
 - Bone: 完整性、密度
 - Soft tissue: 乳房、皮下氣腫、腫塊
- Abdomen
 - Diaphragm: 形狀、高度、CP angle、橫膈下病灶
 - Liver: 肝腫大、膿瘍
 - Gastric bubble: 有無、位置、距橫膈膜距離
- Lung x 2
 - 左右肺區比較
- Mediastinum
 - Widening, shift, abnormal air, mass.
 - Tracheobronchial tree: 狹窄、阻塞
 - Esophagus: 異常的氣柱
 - Heart: 大小、形狀
 - Hilum: 大小、形狀、濃度、位置
- Lung
 - Pleura: 變厚、長水、氣胸、腫塊
 - Lung: 肺紋、濃淡變化



A suggested approach (蛙式讀片法)

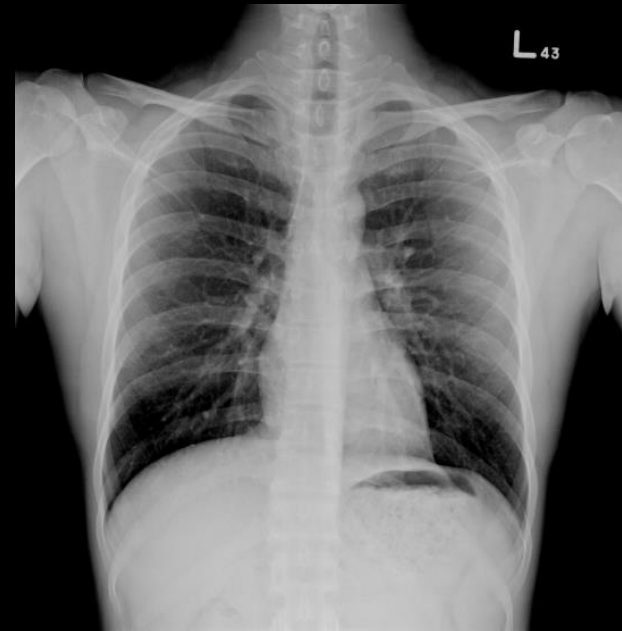- Type and quality of the radiograph
- Chest wall: soft tissues and bone
- Diaphragm and pleural boundaries
- Mediastinum
- Lung parenchyma
- Foreign material



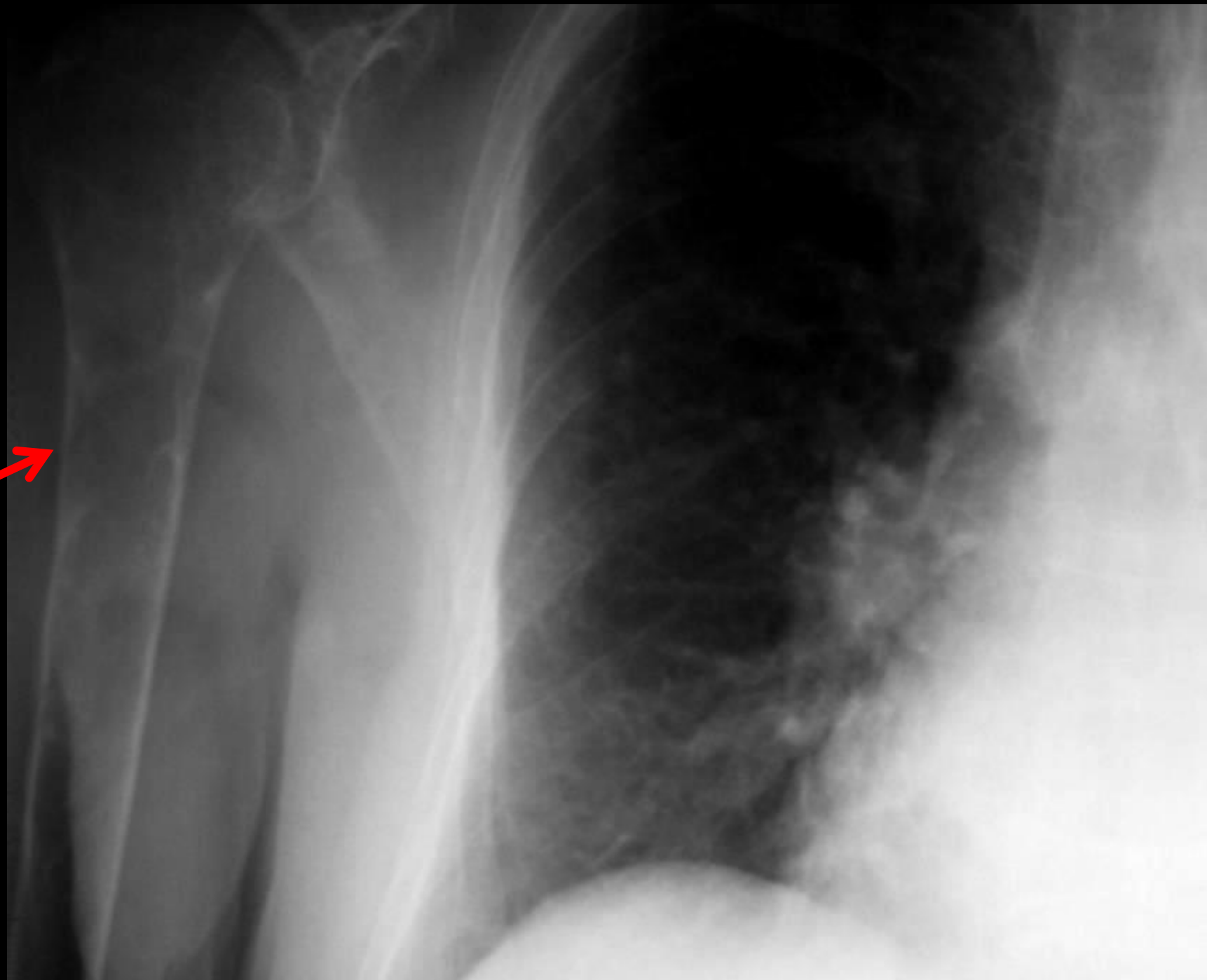

分區重點

胸廓：Bone (Frontal View)

- General appearance
 - Scoliosis, kyphosis, kyphoscoliosis
- Osteoblastic change
 - Prostate ca.
 - Breast ca.
- Osteolytic change
 - Metastasis, multiple myeloma
 - Osteoporosis



**Myeloma –
Osteolytic
Lesions**



胸廓：Bone (Frontal View)

■ Rib

■ 在lateral view中區別左右側的rib：

■ Big rib sign

■ Vertical displacement sign

■ Extra – Cervical rib

■ Upper margin – Metastasis

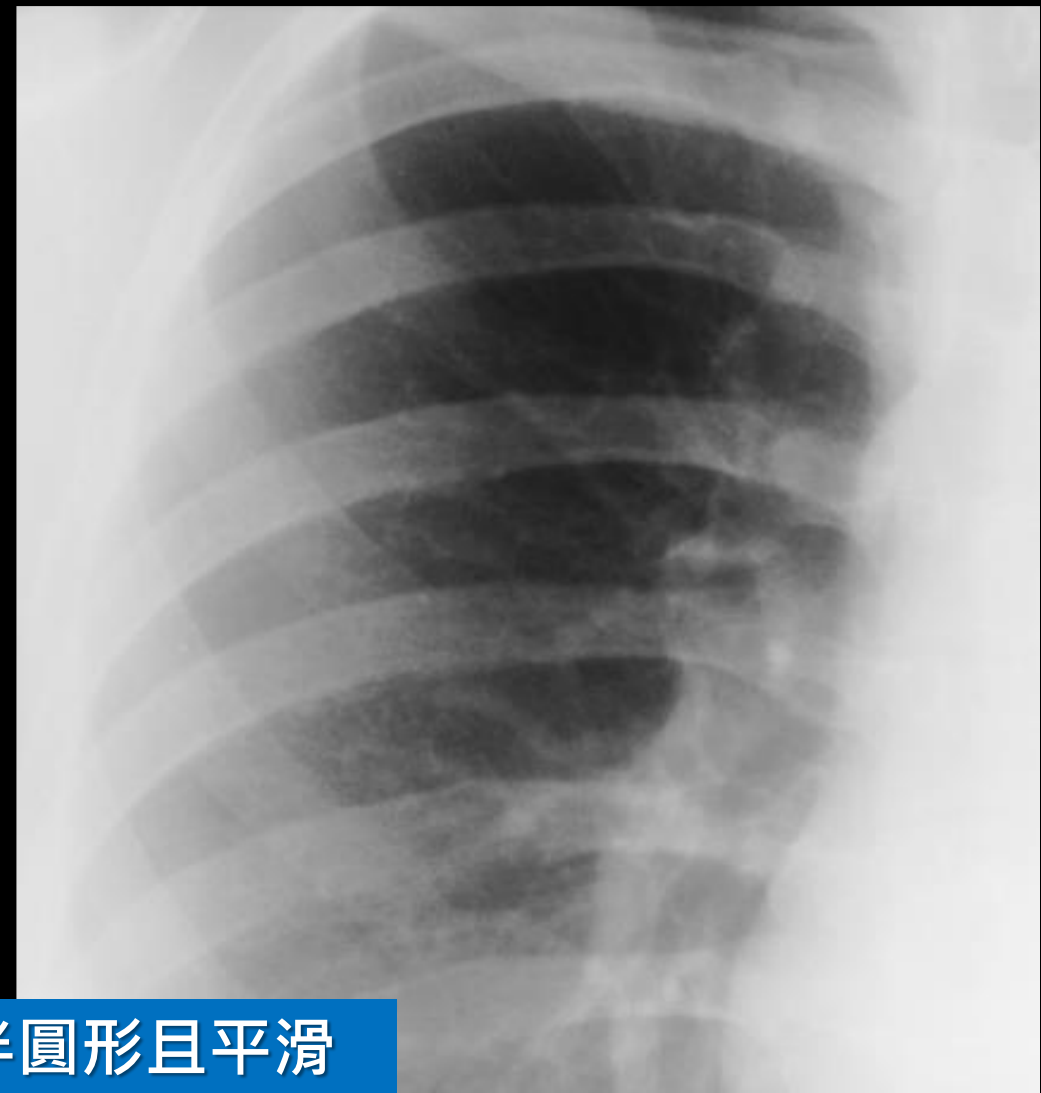
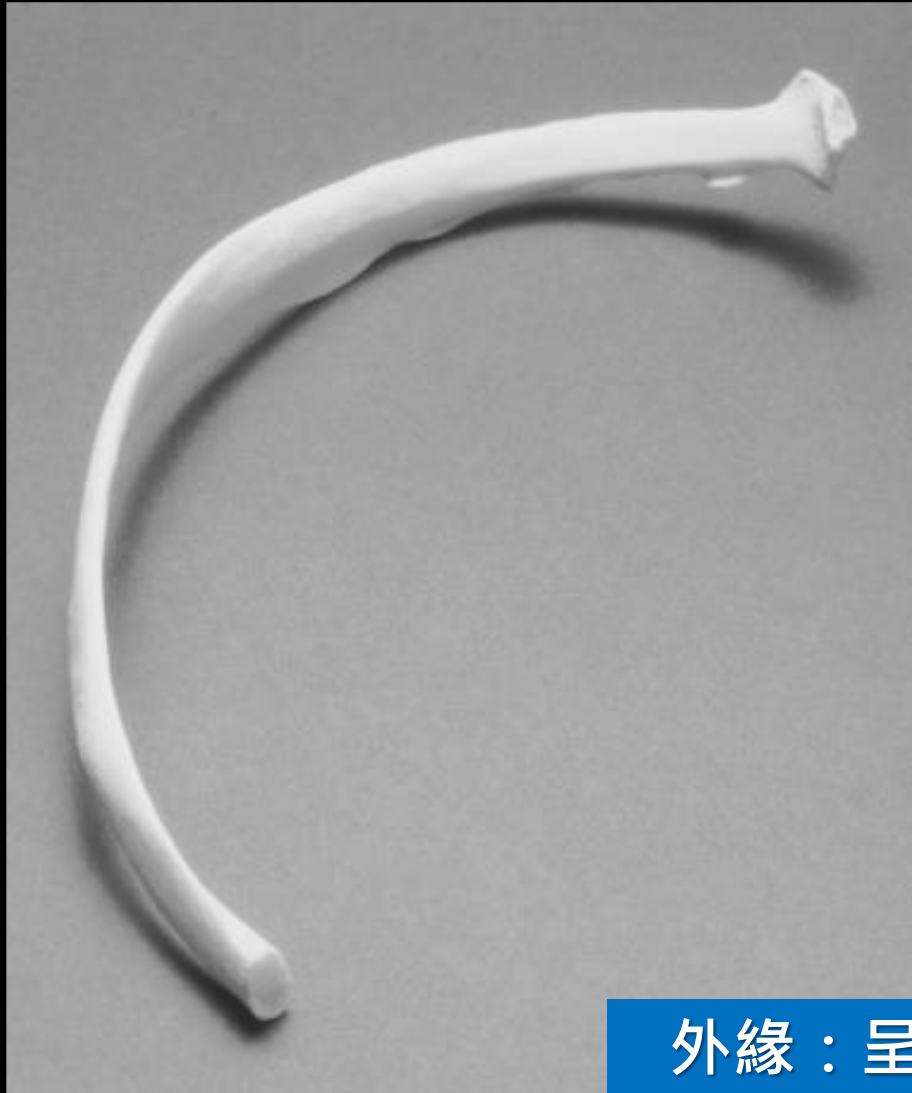■ Lower margin – Notching: Coarctation of aorta

■ Expansion – Healing of fracture, tumor

■ Diffuse enlargement – Extramedullary hematopoiesis

遠離底片那一側的rib cage因為放大的效果看起來會比靠近底片側的來得粗一些

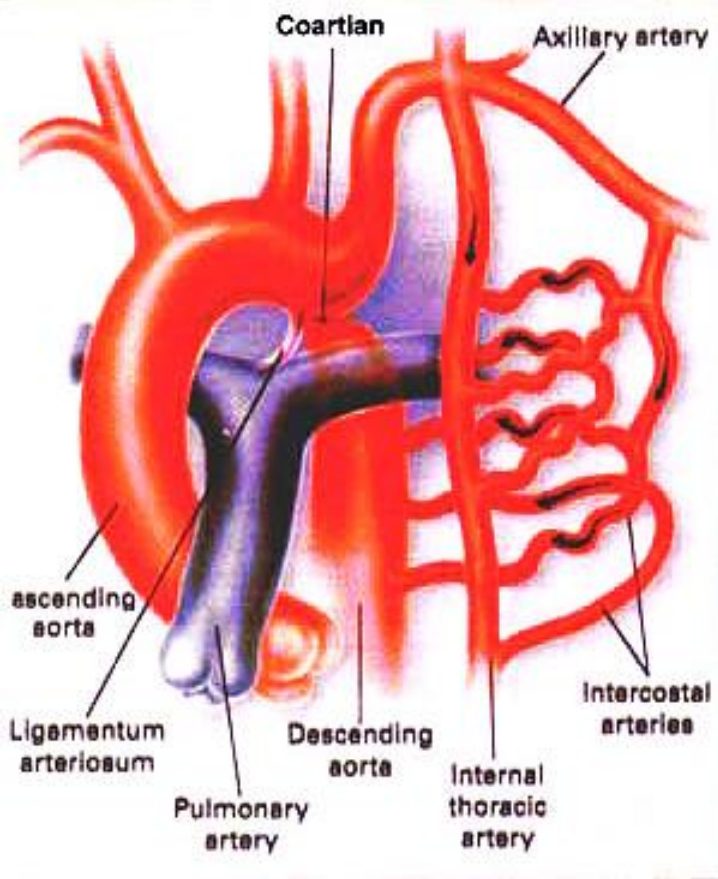
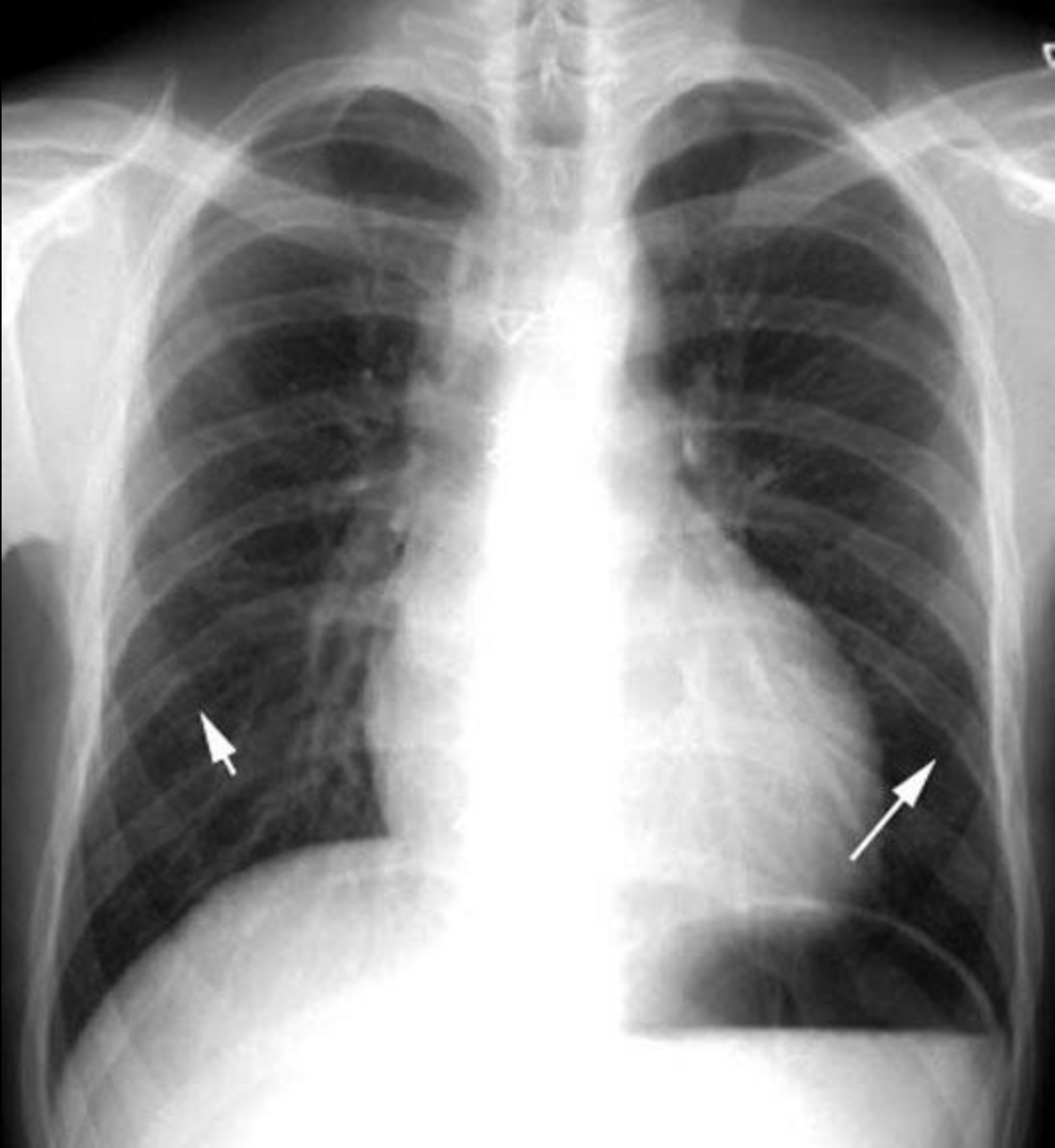
Normal Ribs



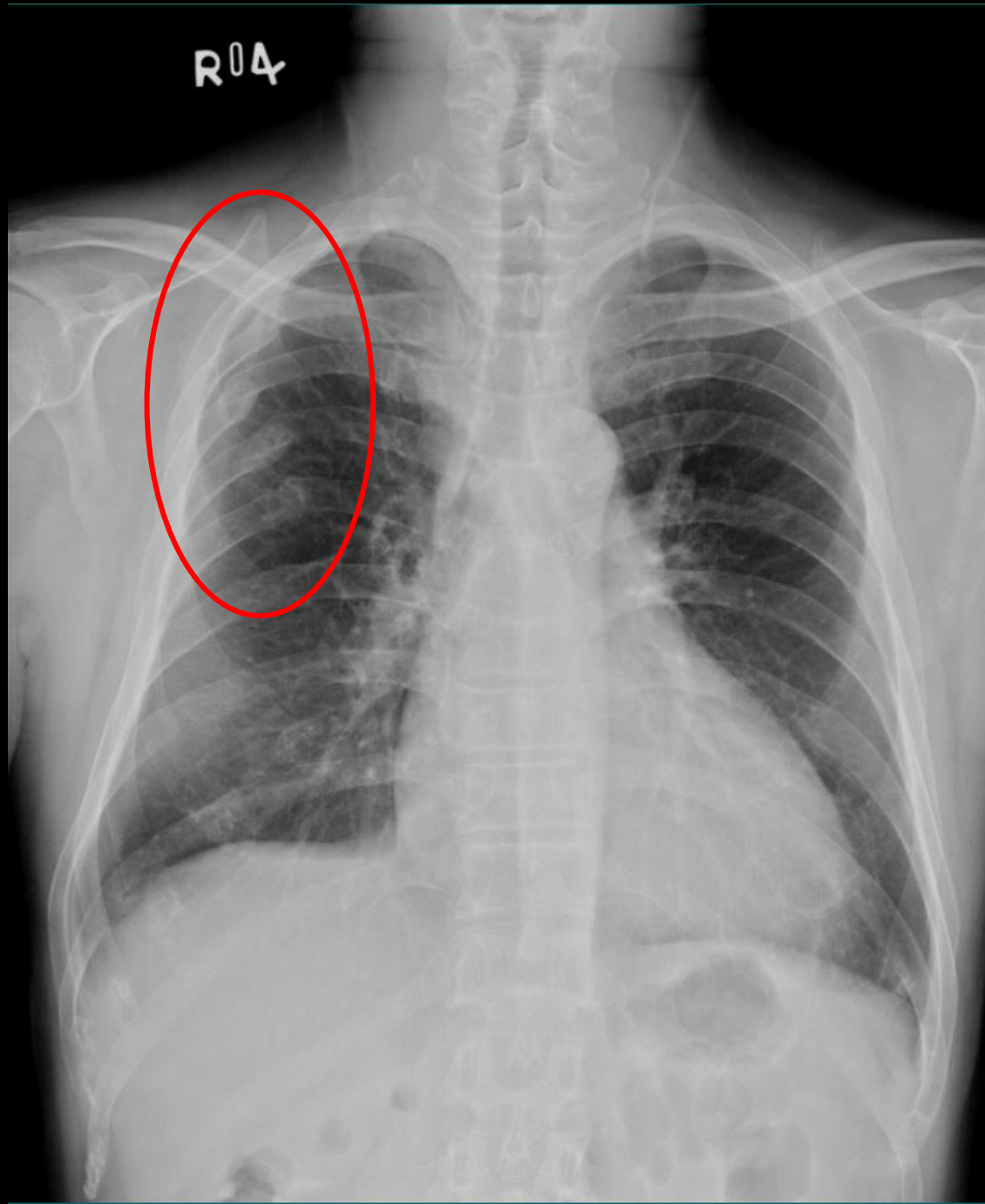
外緣：呈半圓形且平滑

Rib notch

Coarctation of Aorta

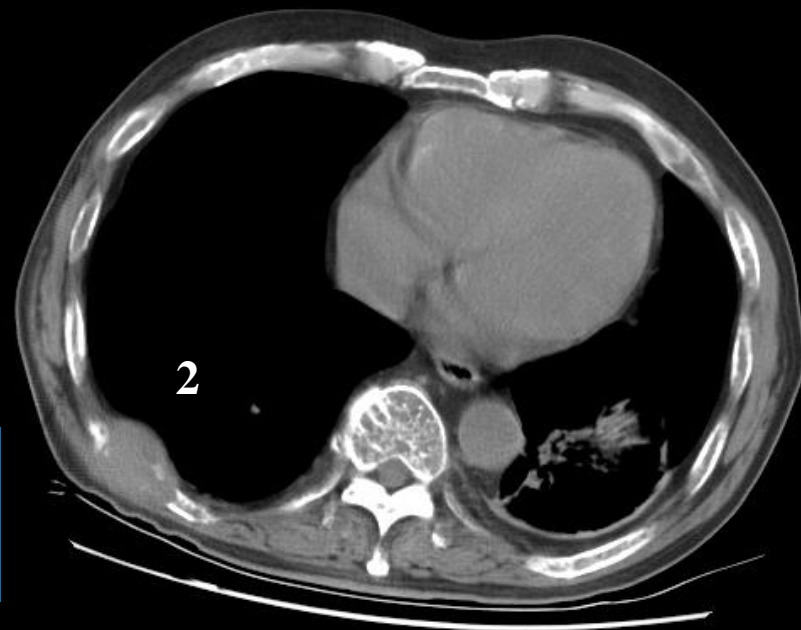
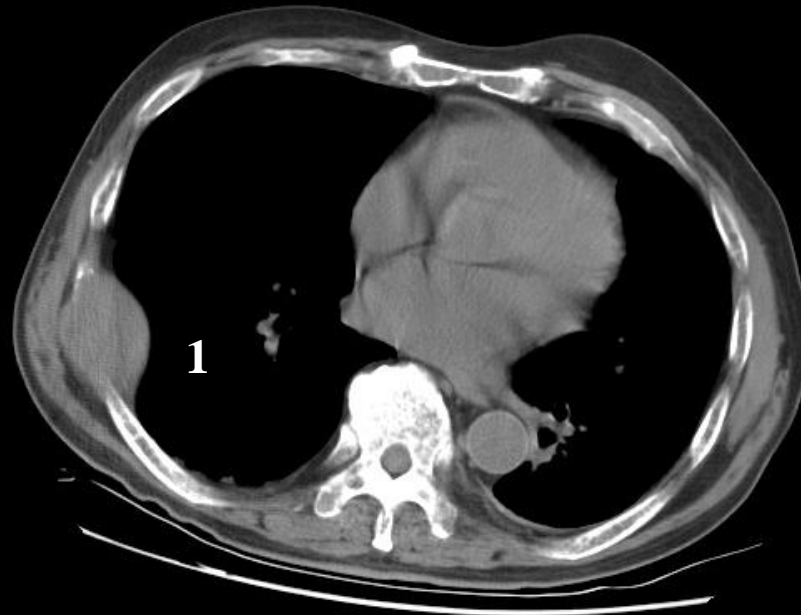
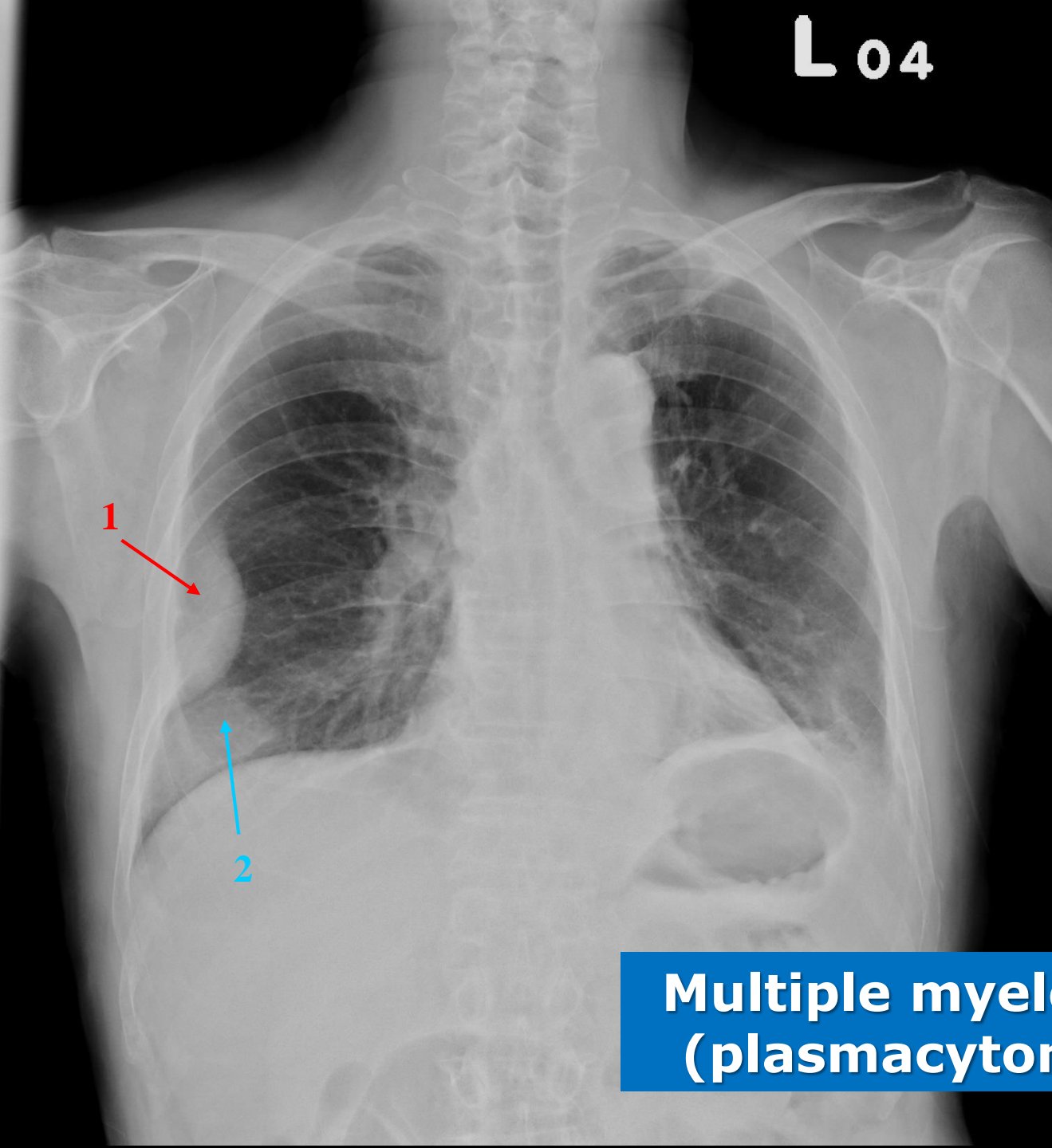


R04

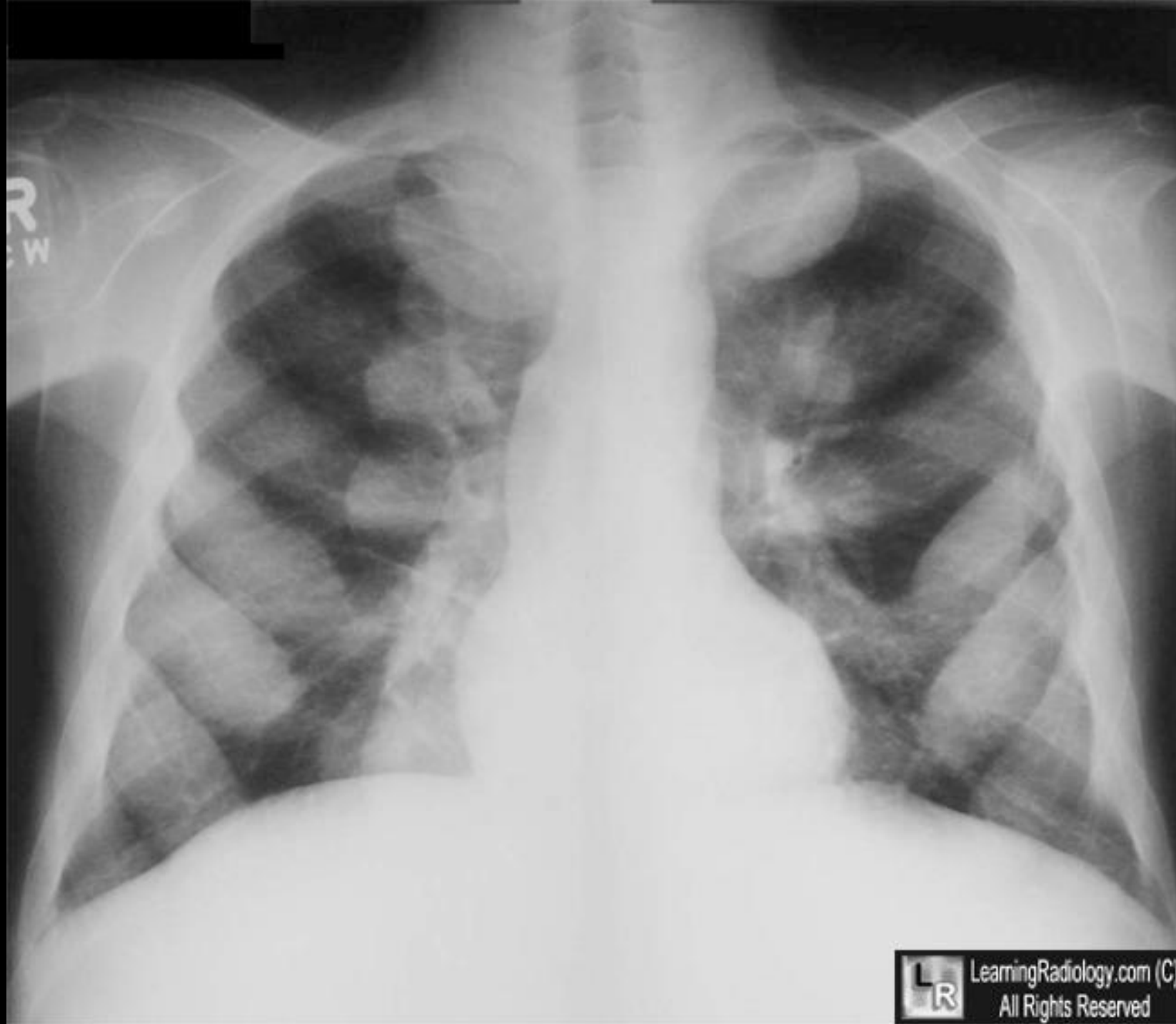

**Rib Fracture,
healing**

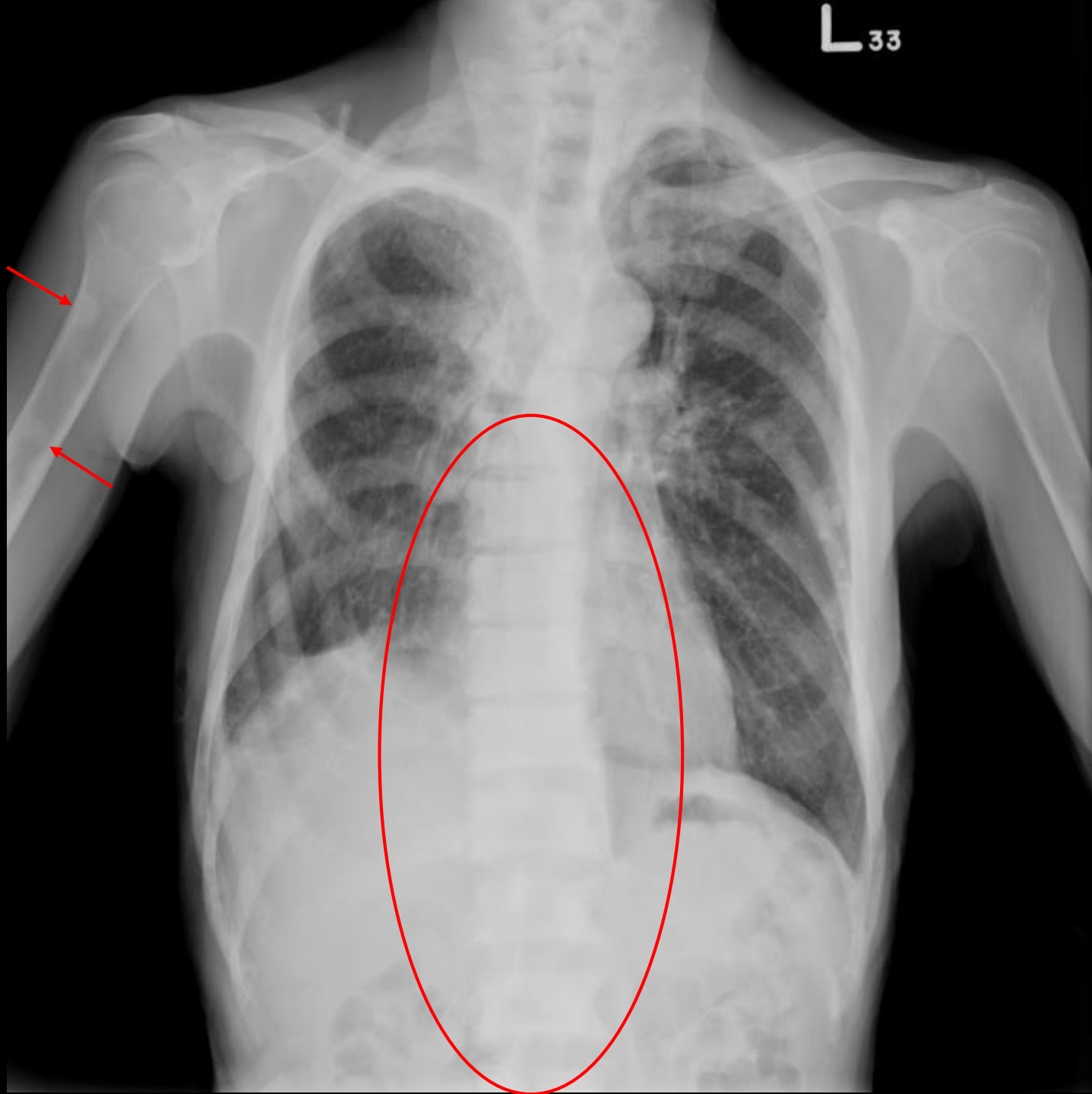
L 04



**Multiple myeloma
(plasmacytoma)**



Thalassemia
Extramedullary
hematopoiesis



**Prostate cancer with
osteoblastic lesions**

胸廓：Bone (Frontal View)

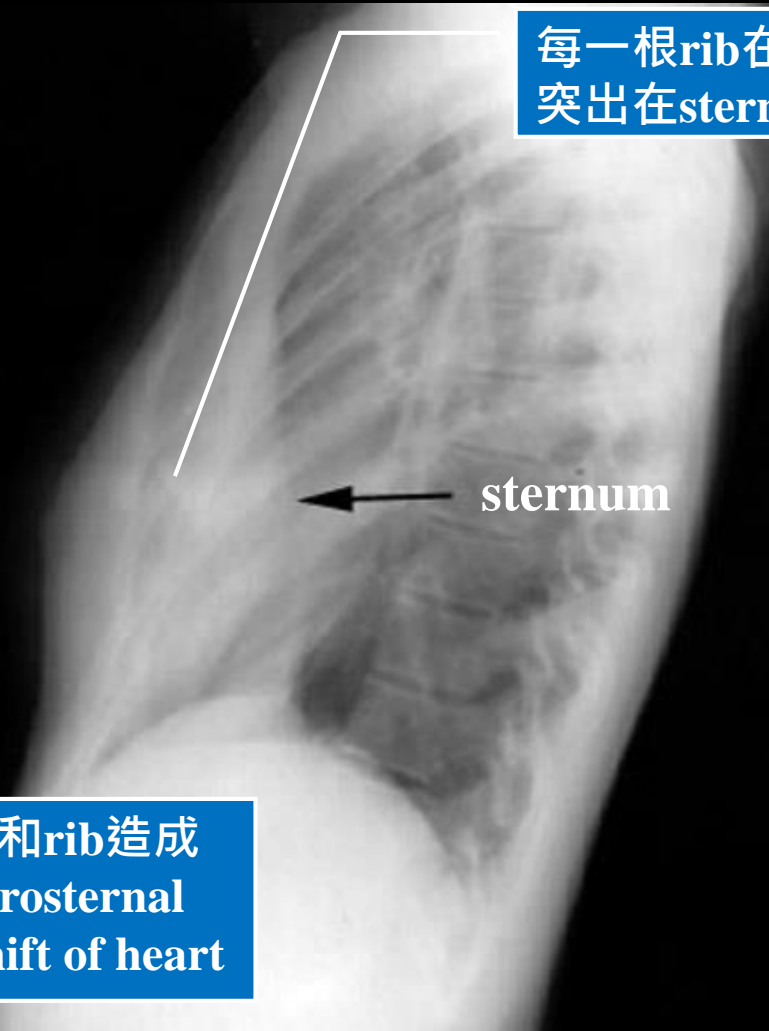
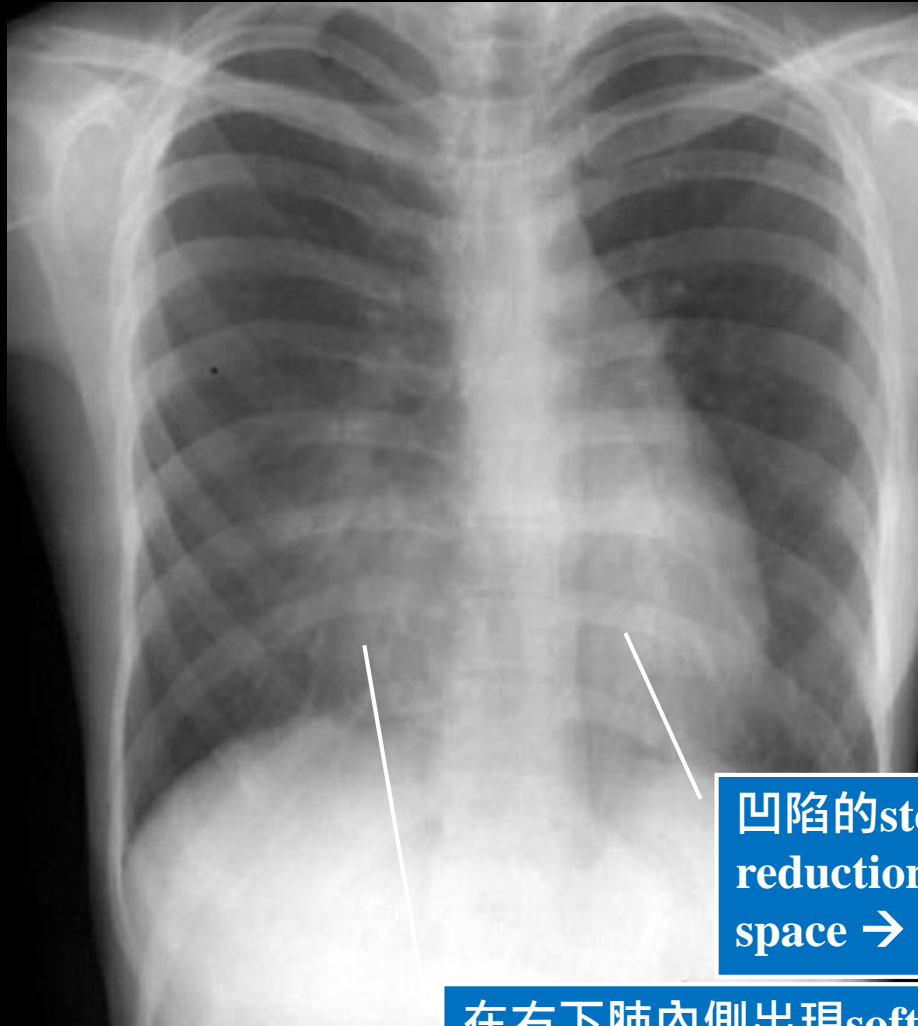
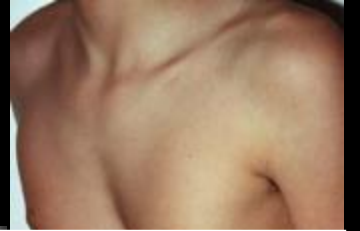■ Sternum

- Pectus excavatum (Funnel chest)
- Pectus carinatum (Pigeon chest)

■ Spine: **the lower, the more radiolucent of density**

- Compression fracture/osteoporosis
- Bamboo spine
- TB spine
- Metastasis (osteoblastic, osteolytic)

Pectus Excavatum (漏斗胸)

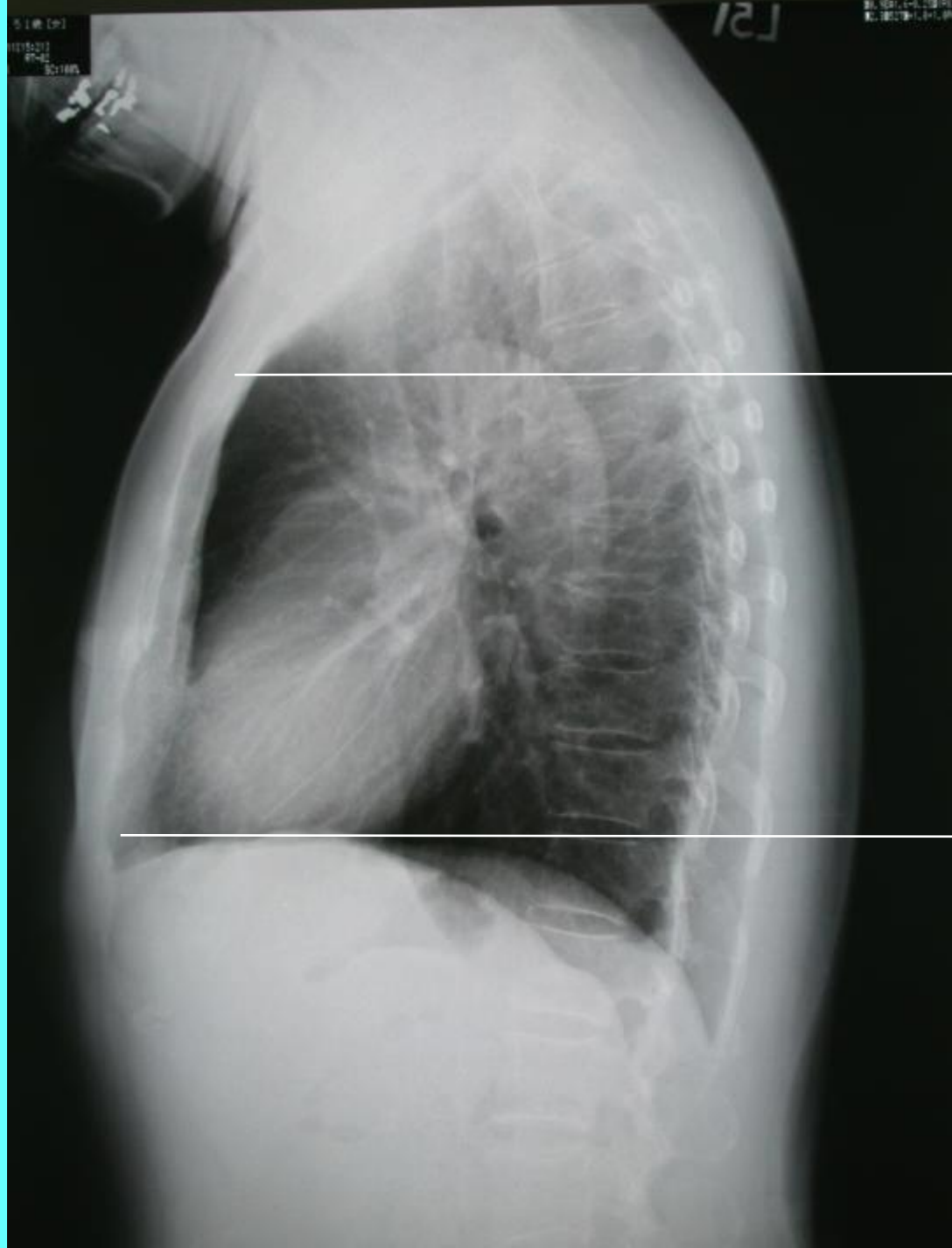

每一根rib在lateral view都突出在sternum的前面

凹陷的sternum和rib造成 reduction of retrosternal space → Left shift of heart

在右下肺內側出現soft-tissue density，使得右邊 heart border不清楚

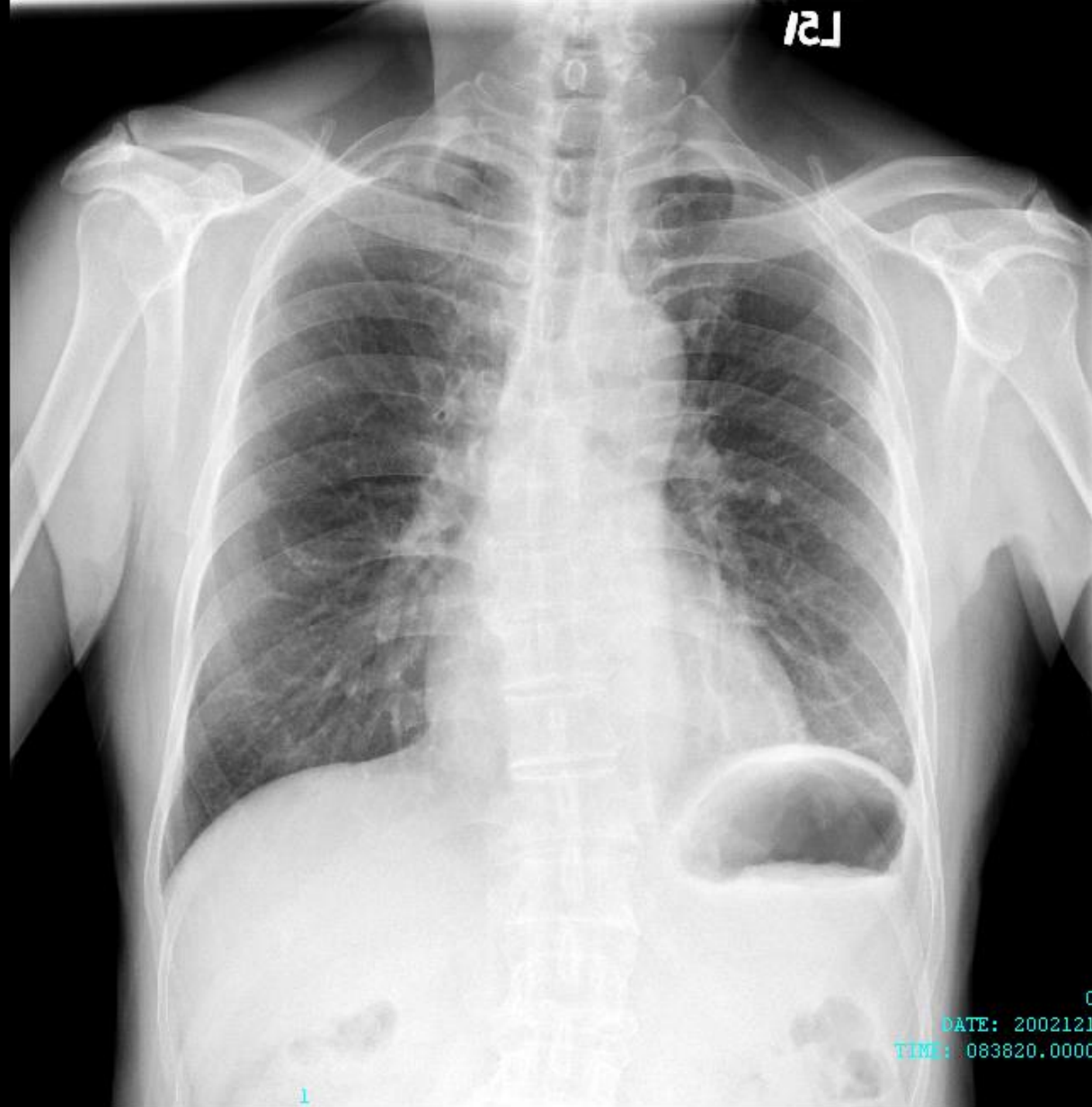
肋骨前緣：downward angulation(像數字“7”), which run almost parallel to each other.



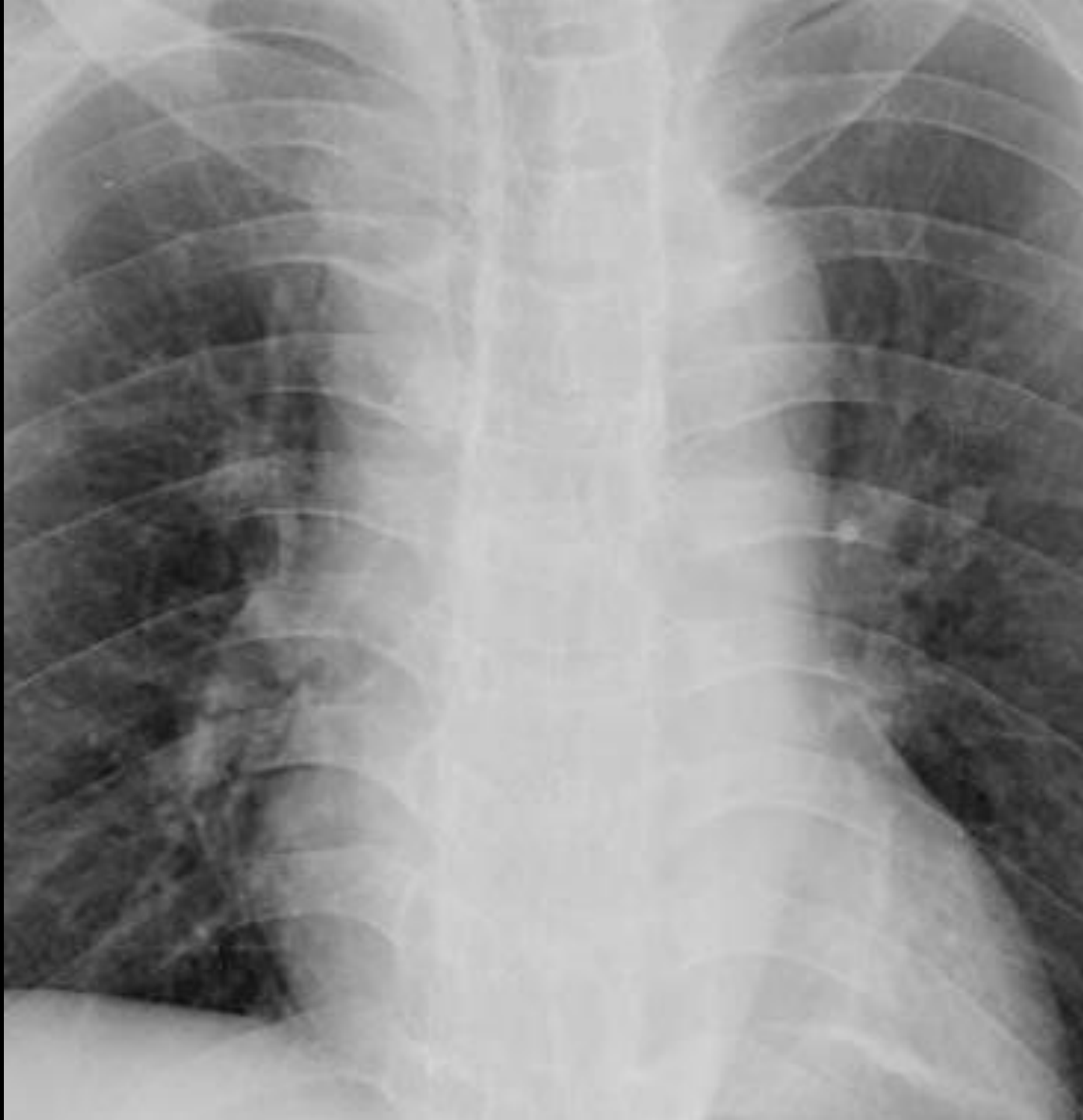T4

脊椎骨影像由上往
下逐漸變黑

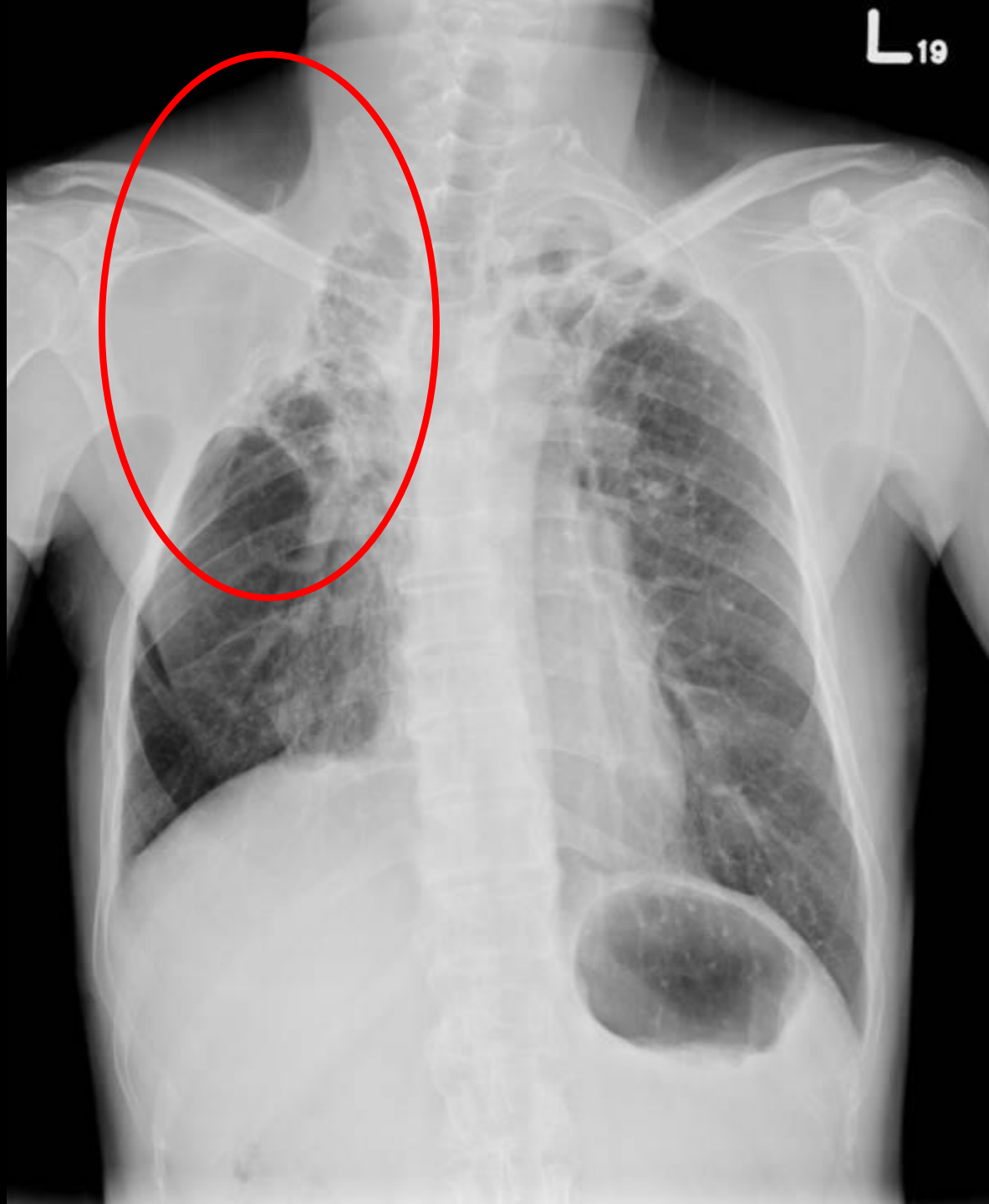T11



Scoliosis



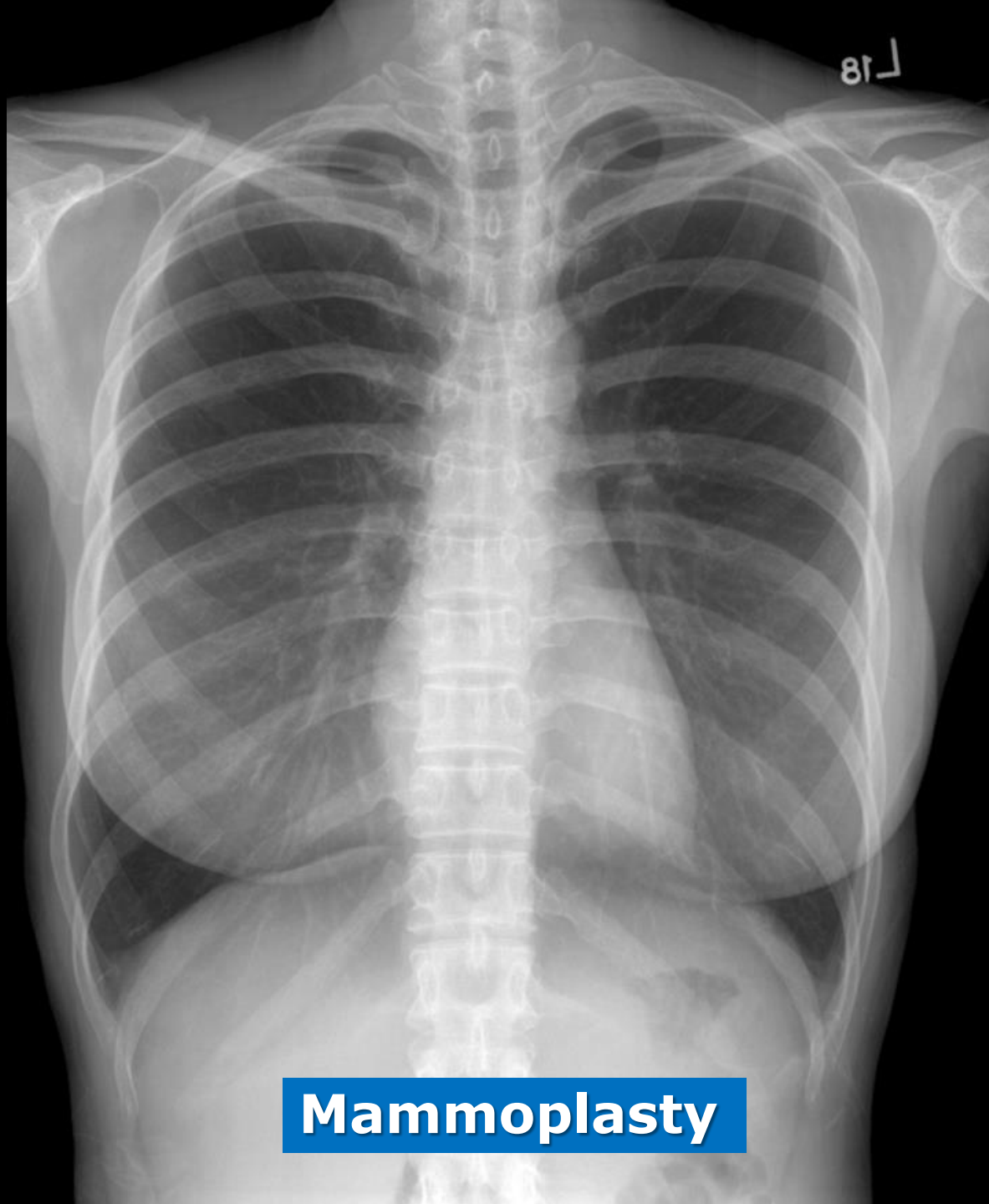
**AS with
bamboo spine**



Thoracoplasty

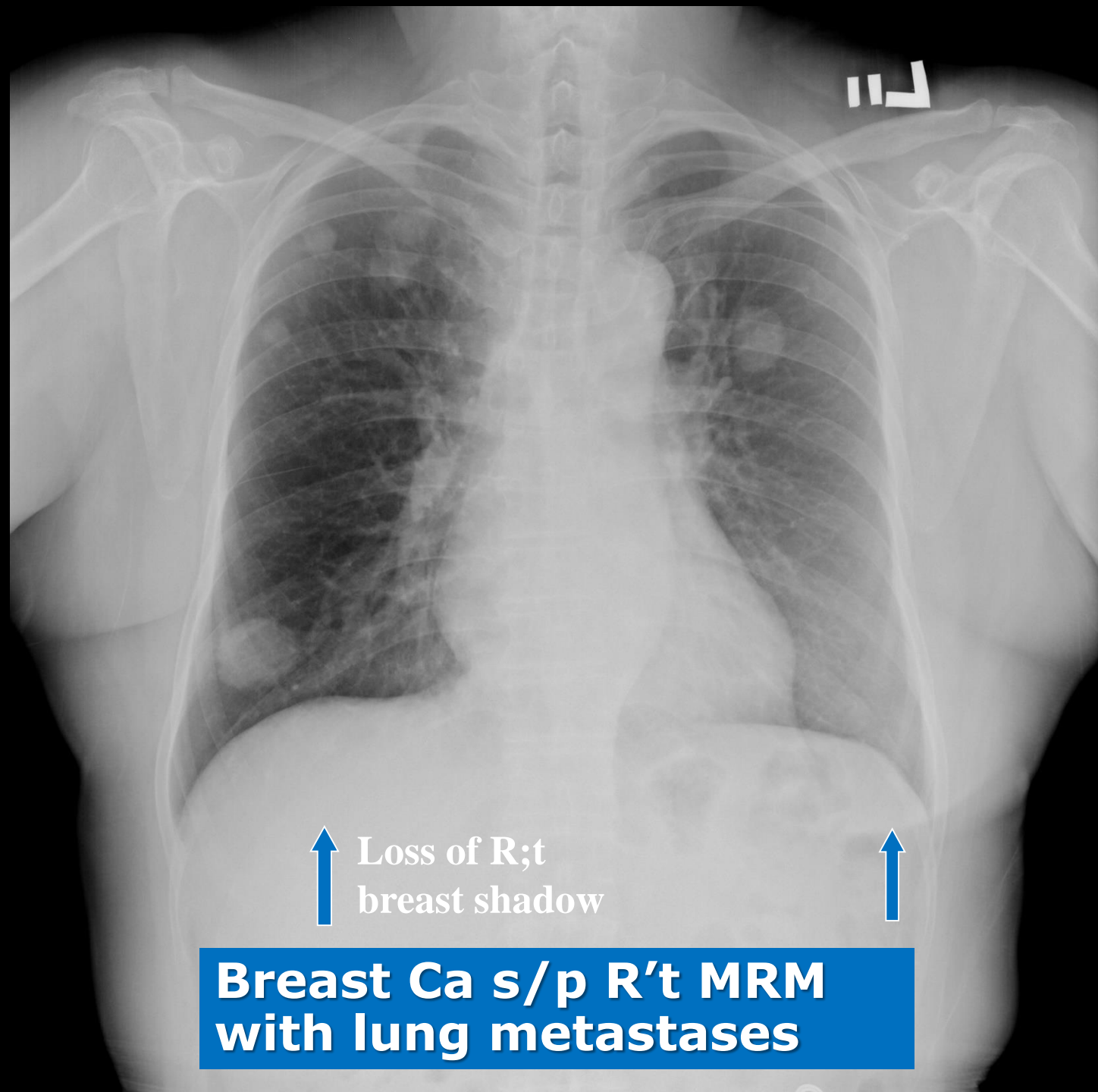
胸廓：Bone (Frontal View)

- Breast shadow
- Subcutaneous emphysema
- Subcutaneous abscess/cellulitis
- Neck mass/soft tissue mass
- Gastric bubble
 - Upper border > 2cm -- Subpulmonic effusion
 - Intra-gastric mass -- Gastric ca.
 - Extra-gastric mass -- Spleen or kidney
 - Absence -- Hiatal hernia, achalasia



Mammoplasty

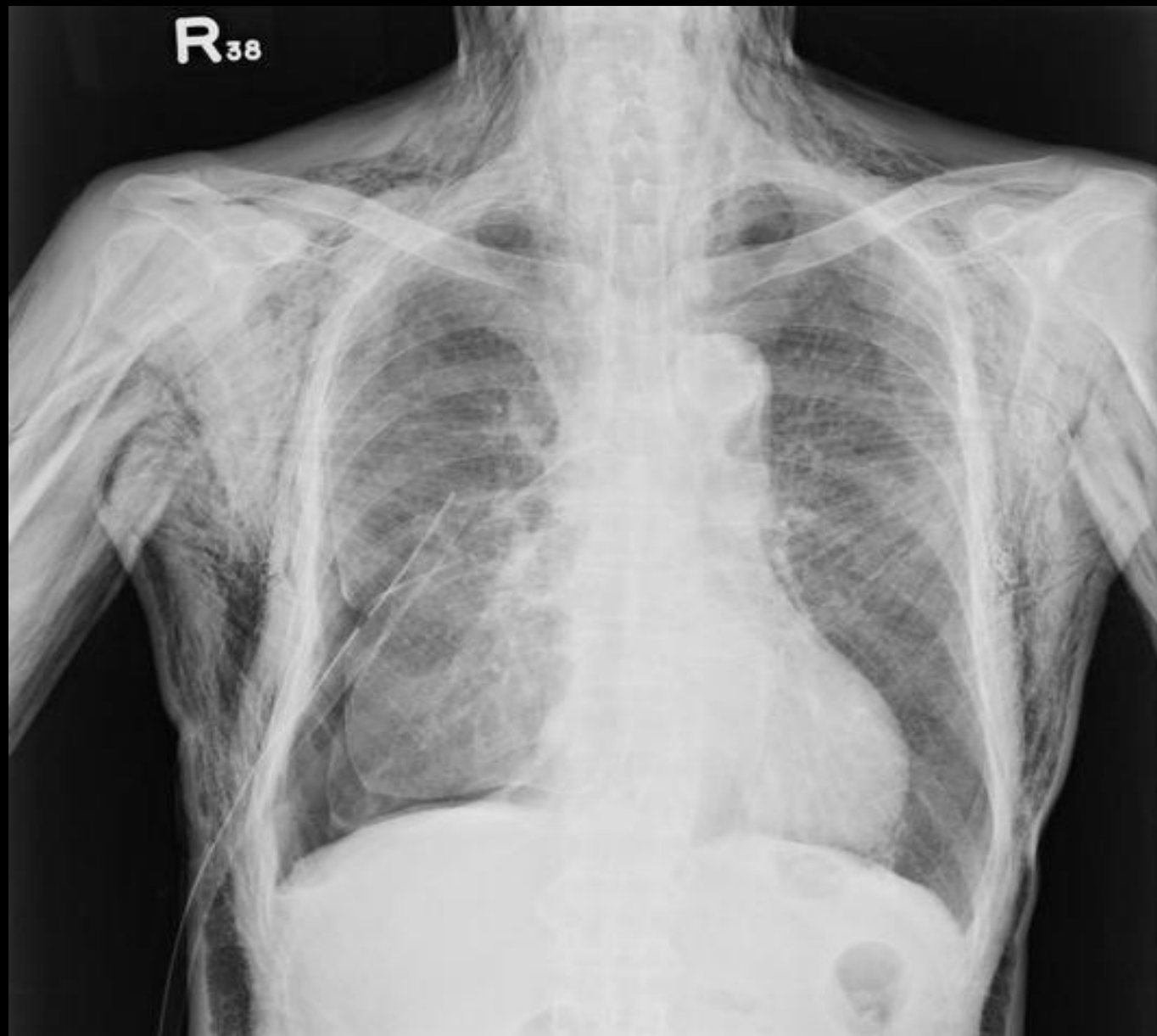從上到下密度一成不變，沒有愈來愈白



↑ Loss of R;t
breast shadow



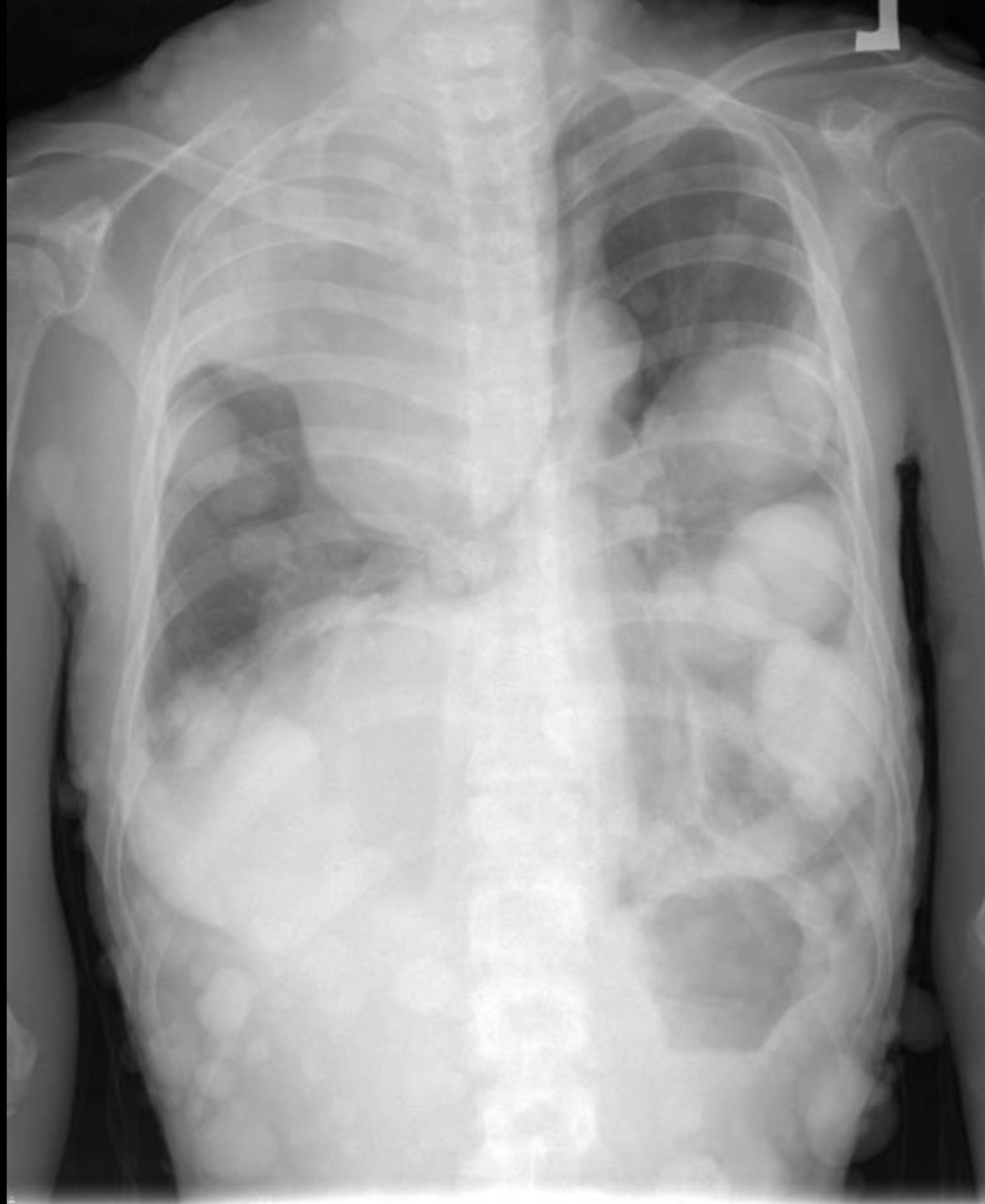**Breast Ca s/p R't MRM
with lung metastases**



Subcutaneous emphysema

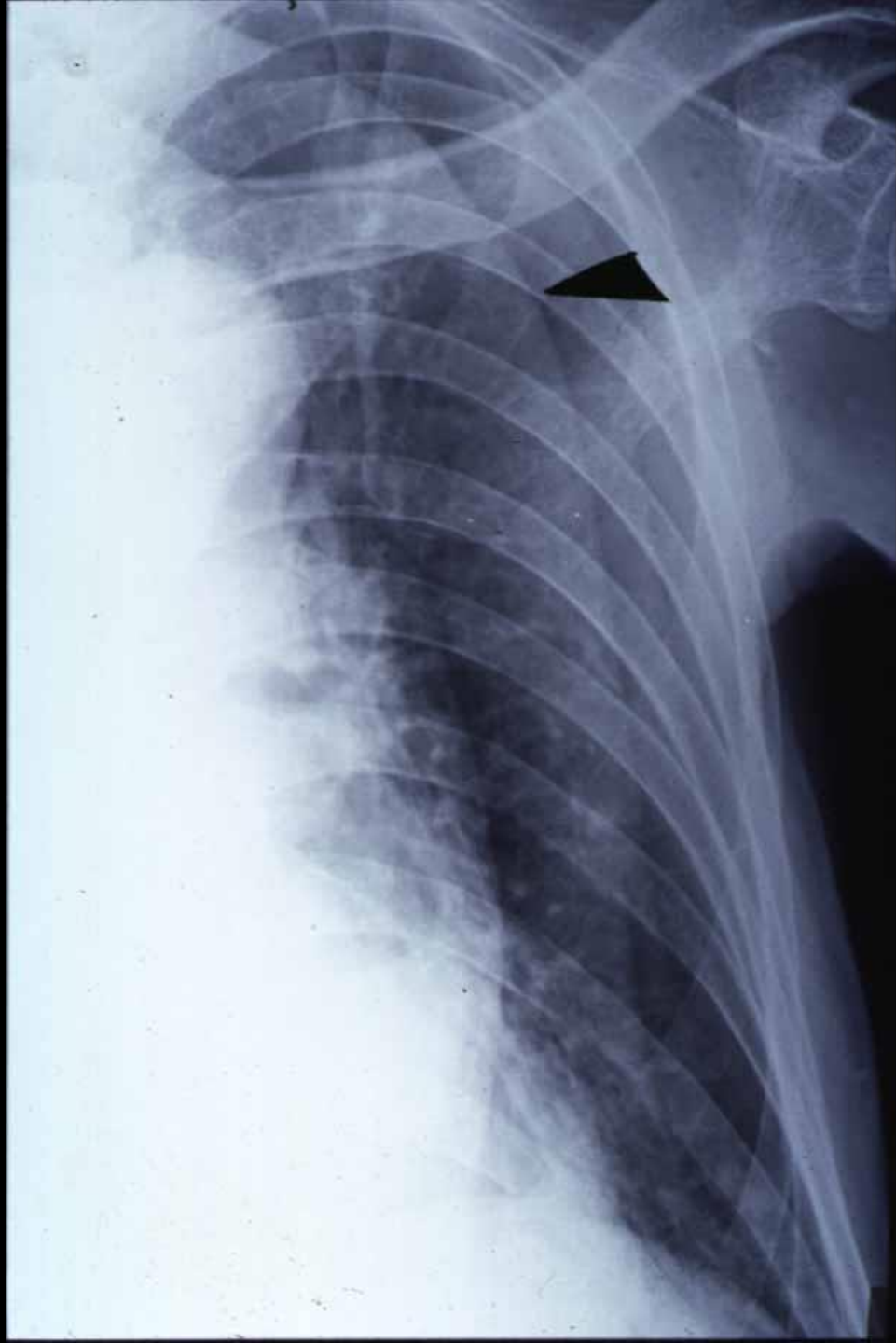
胸廓之軟組織：

**Neurofibromatosis
with lung
involvement**



Pleura


- Pleural lines
- Pleura-based mass
- Costophrenic angle blunting - effusion, thickening
- Pleural thickening - fibrosis, calcification



Skin fold

- 可以一直trace到lung field以外
- 線條以外的lung field內可以看到lung marking

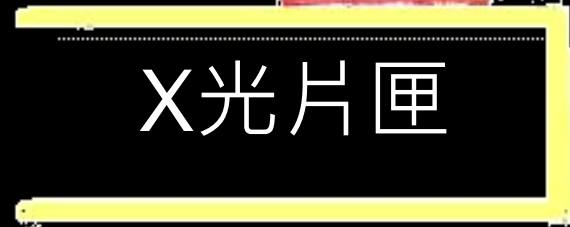X光

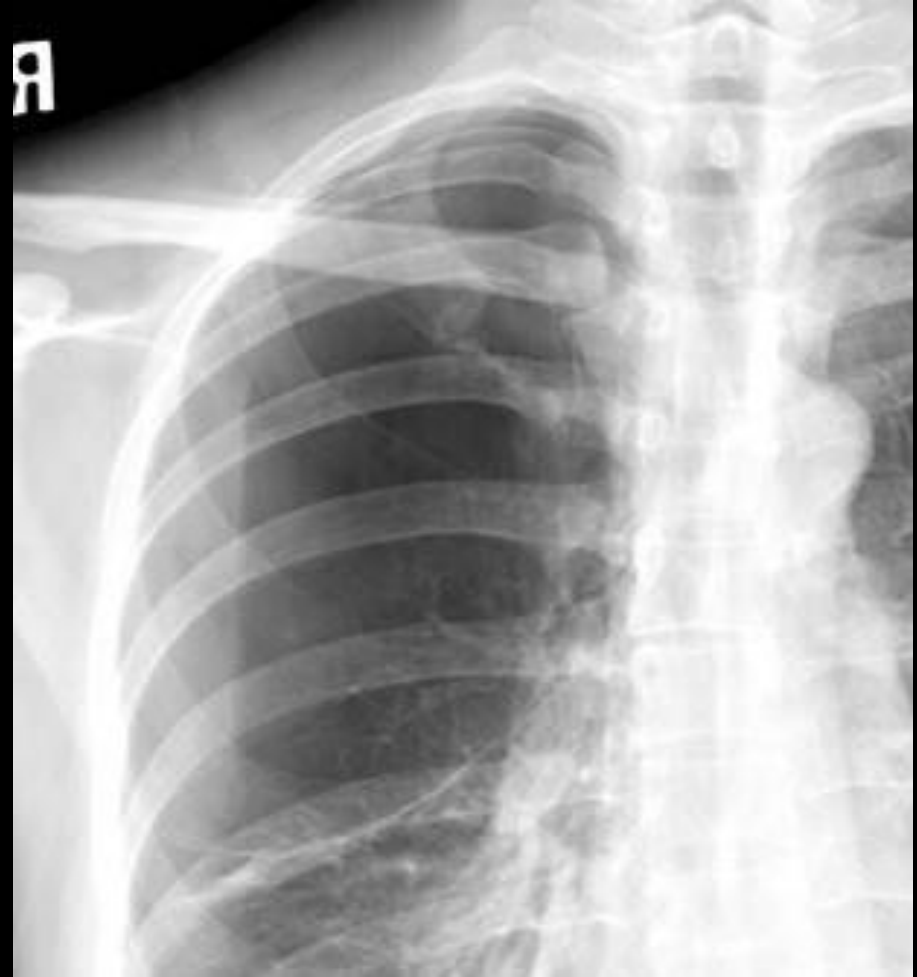
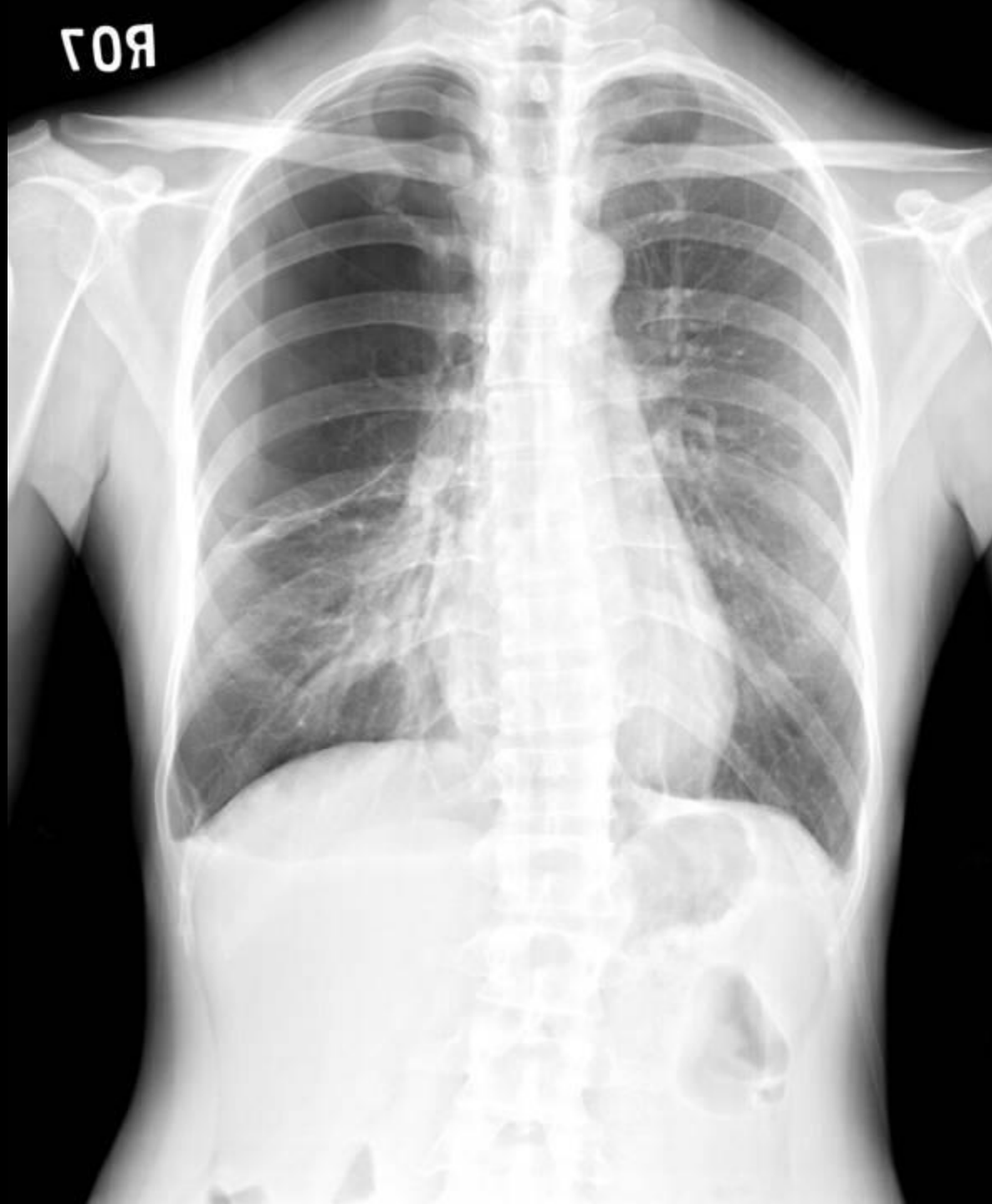

皮膚



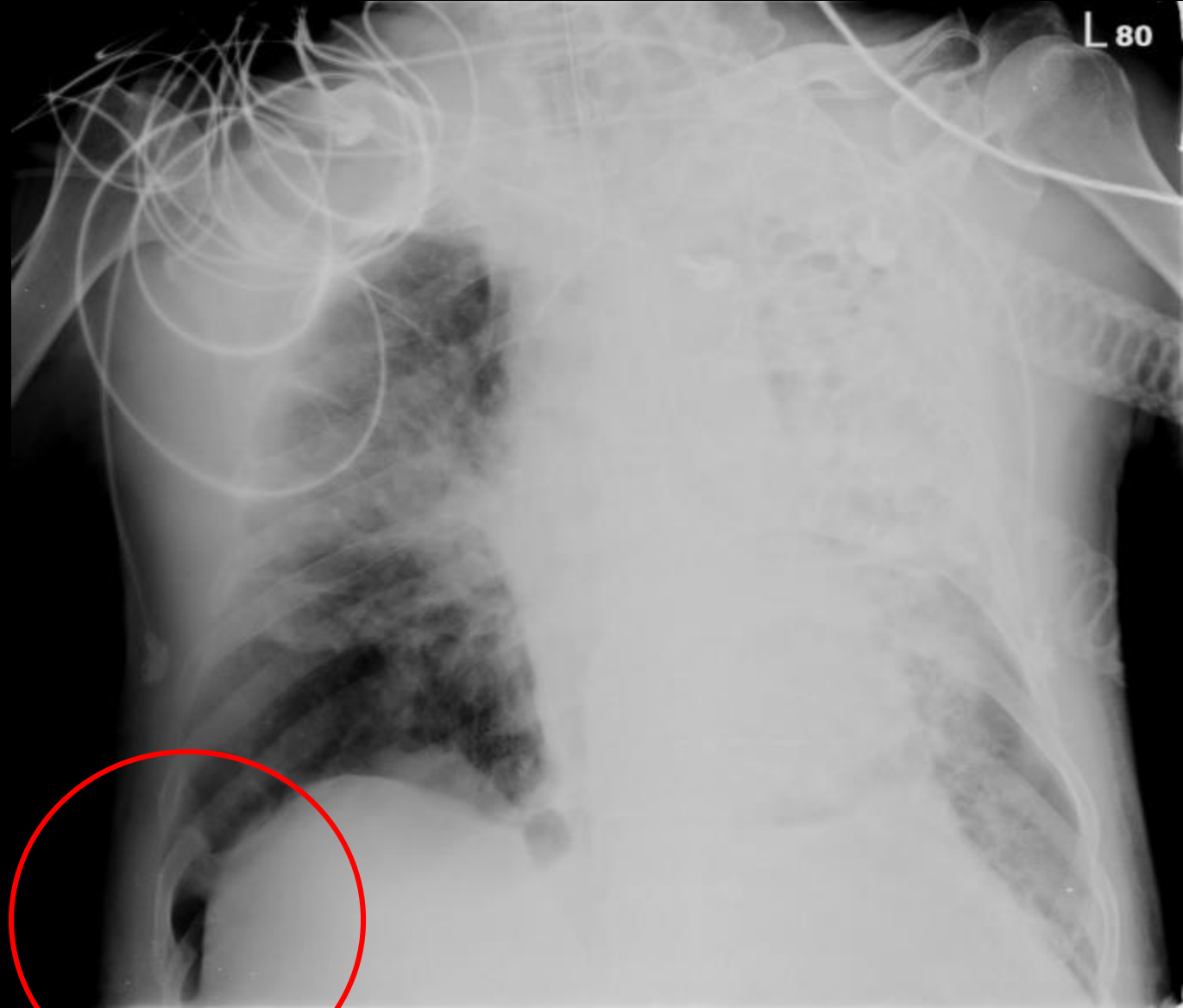
X光片匣





Pneumothorax

Pneumothorax- deep sulcus sign



橫膈、橫膈下影像

■位置：前高後低, 右高左低, 內高外低

■右橫膈: 10~11 post. rib;

左橫膈: 略低 **0.5-1 vertebral body**(約1-2cm)

■最高點在內1/3處

■左側橫膈高於右側橫膈：異常

■肺部因素：L't lung volume reduction

■橫膈因素：diaphragmatic hernia, subpulmonic effusion

■腹腔內因素：lesion把L't diaphragm往上頂

橫膈、橫膈下影像

■胃氣：

- 距左橫膈 $< 1\text{cm}$; $> 2\text{cm}$ 要懷疑subpulmonic effusion
- 胃內有沒有東西 (gastric Ca)
- Gastric air不見：hiatal hernia, achalasia, 躺著照

■Liver：

- Liver abscess: air-fluid level within liver density
- 利用腸氣(colon gas)可判斷肝脾大小

■Subphrenic gas：PPU, subphrenic abscess, interposed colon

■ 橫膈前高後低

■ 如何辨認左右橫膈:

右: 1. 被胃部空氣跨越者

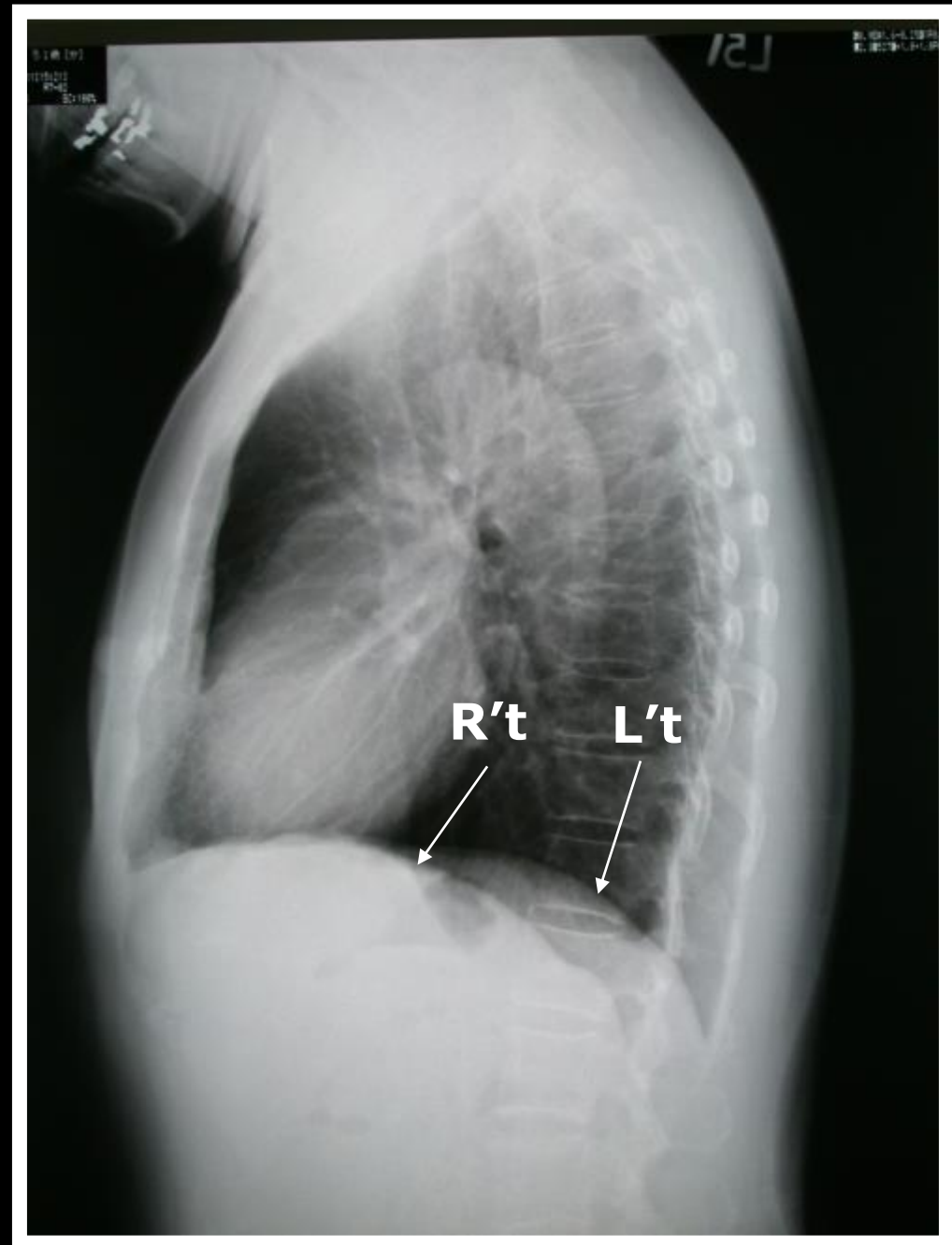
2. 和下腔靜脈相連者

3. 前端橫膈仍清楚可見

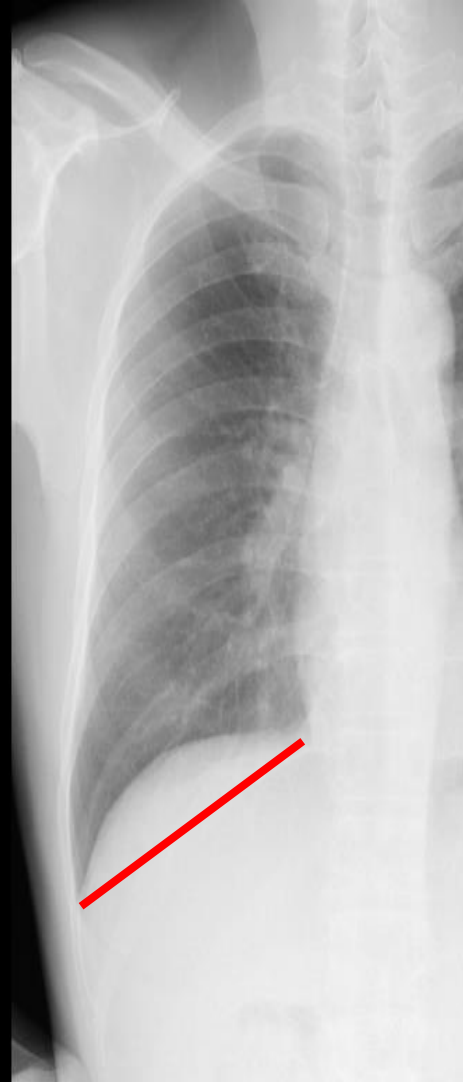
4. 在L't lateral view中與較粗肋骨相連者(big rib sign)

左: 1. 前端融入心臟影像

(silhouette)

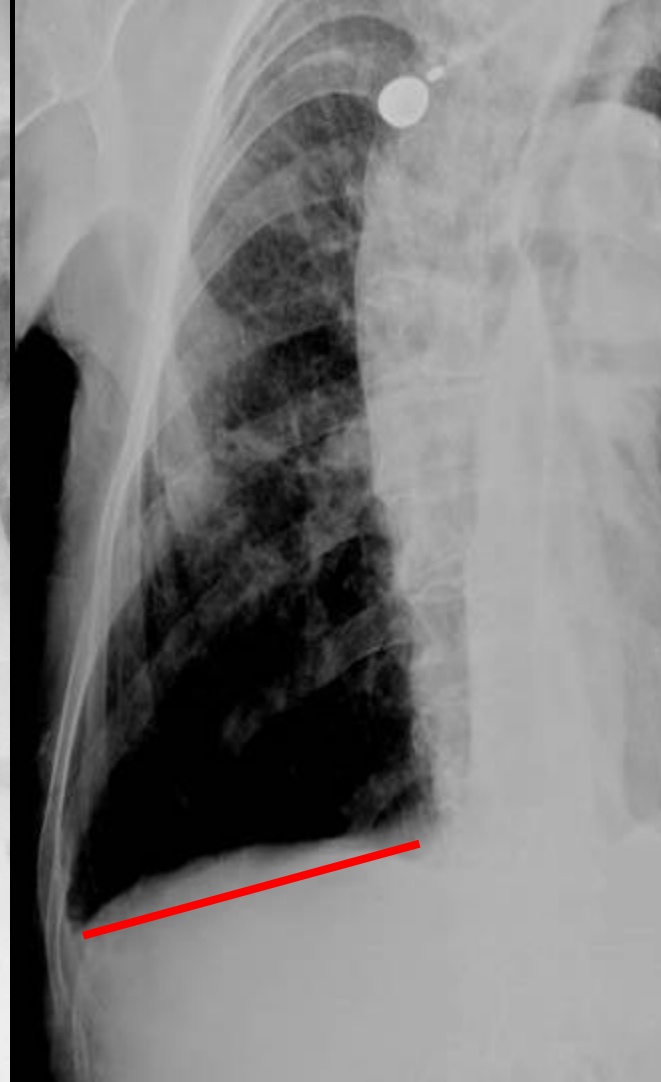


Normal > 1.5cm



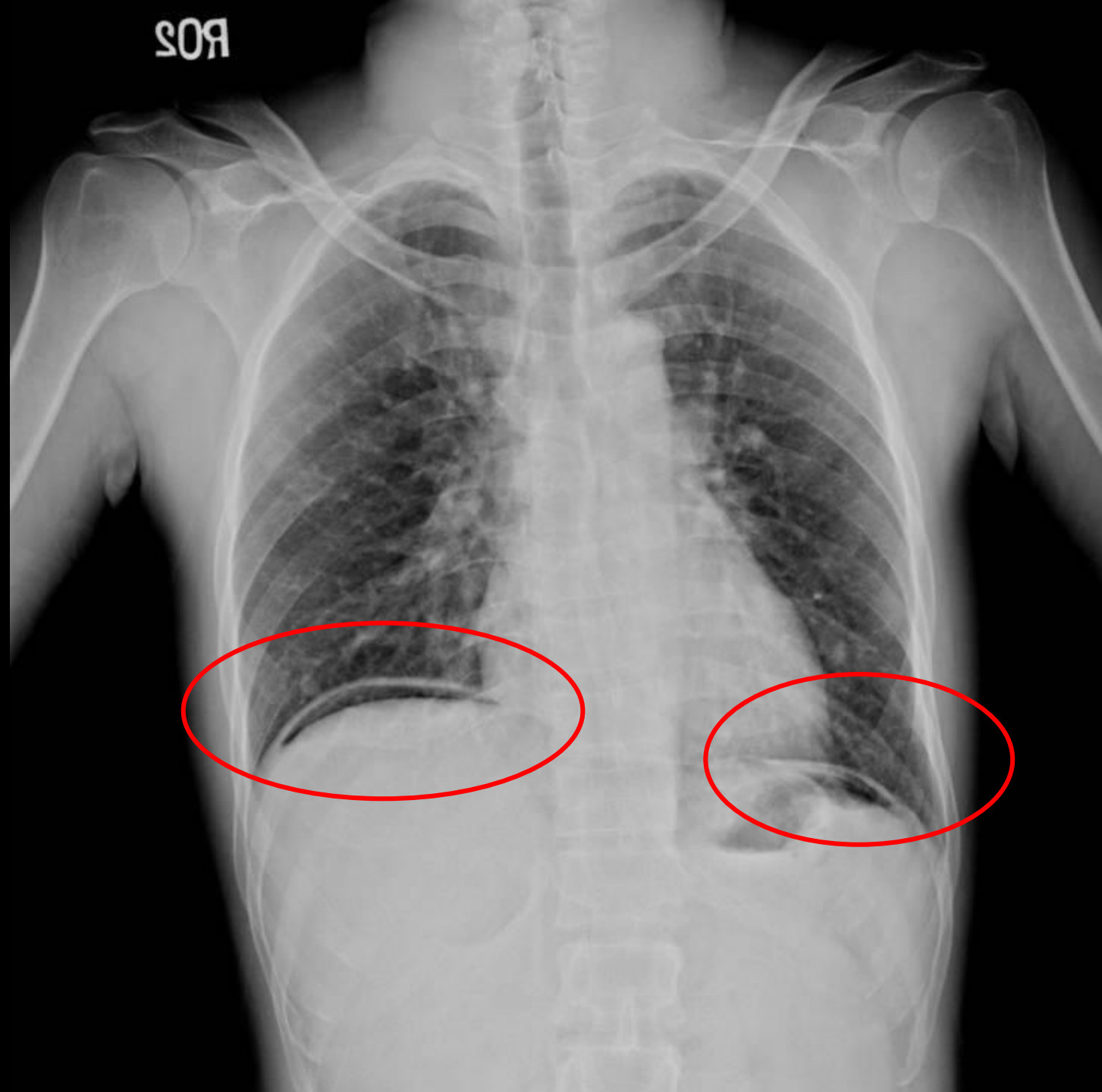駝峰狀

Normal



扁平狀

COPD



Pneumoperitoneum

Mediastinum 縱隔

■ 心臟

Heart shadow

Cardiothoracic Index

■ 大血管

Aorta

Pulmonary arteries

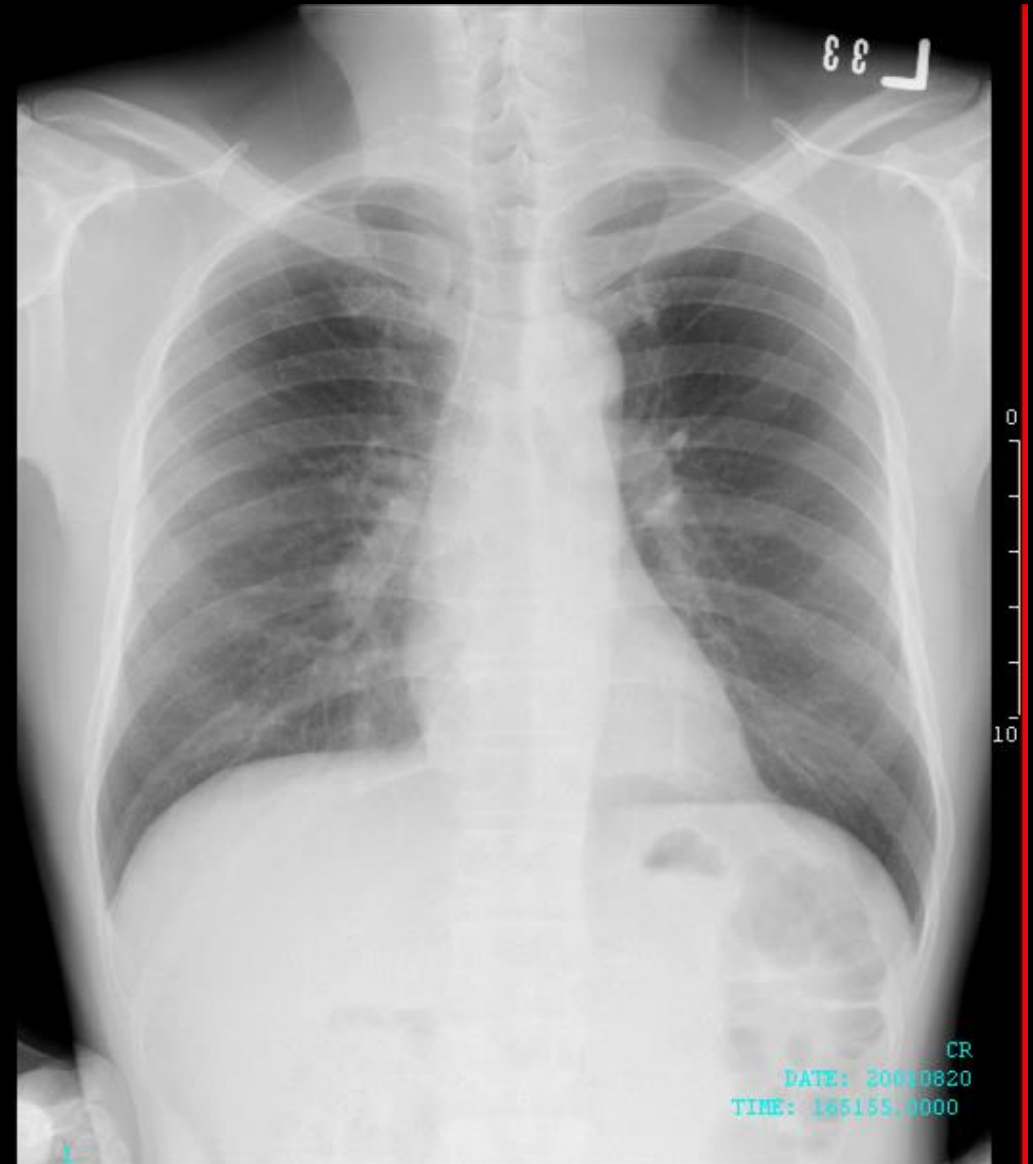
■ 大氣道

Endotracheal/endobronchial

Subcarinal angle 75°

■ 食道

■ 肺門



Mediastinum 縱膈

懷疑縱膈病灶-務必看側位照

上、前、中、後縱膈

心臟

大血管

Aorta

Pulmonary arteries

大氣道

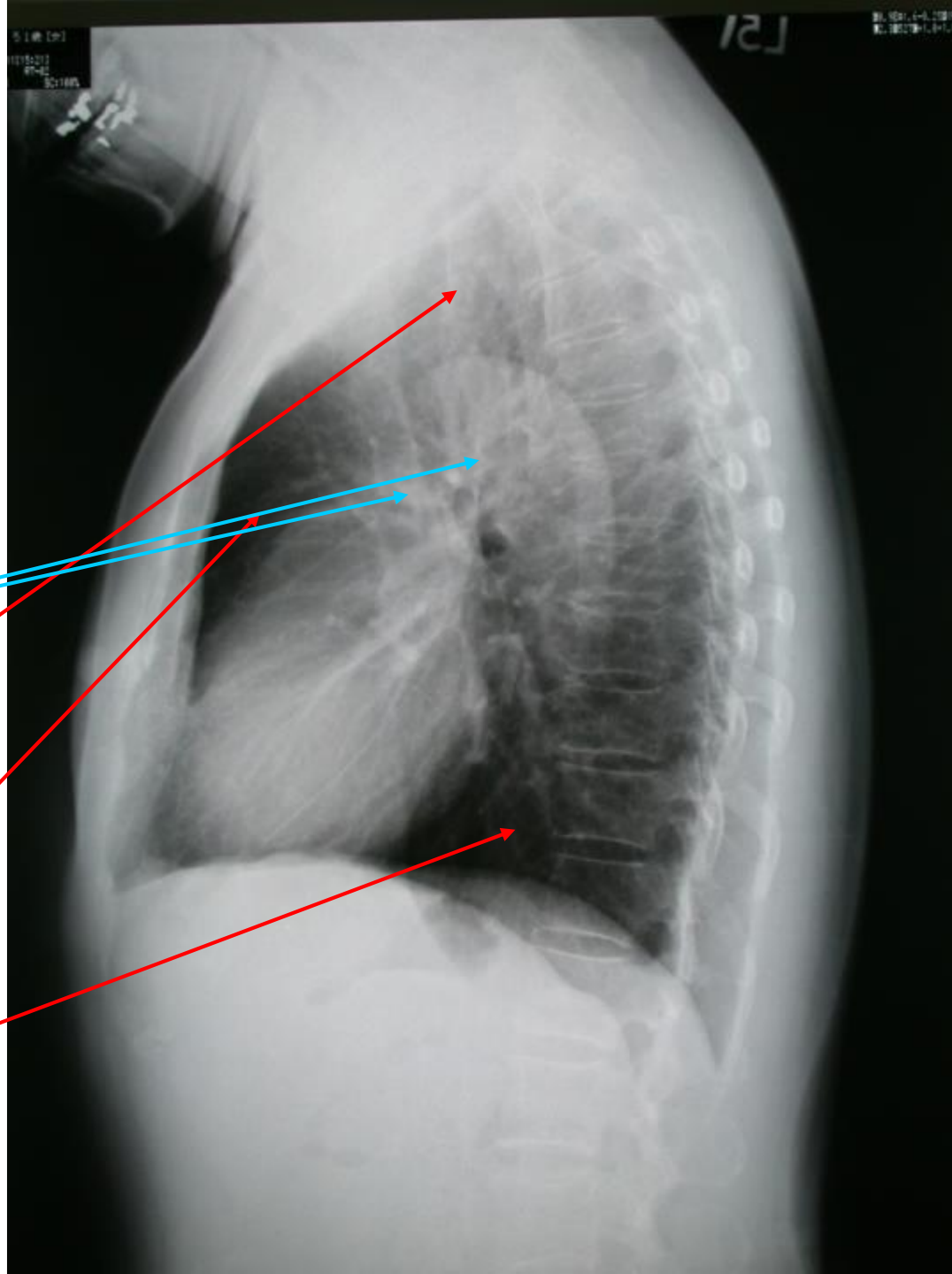
Posterior tracheal stripe

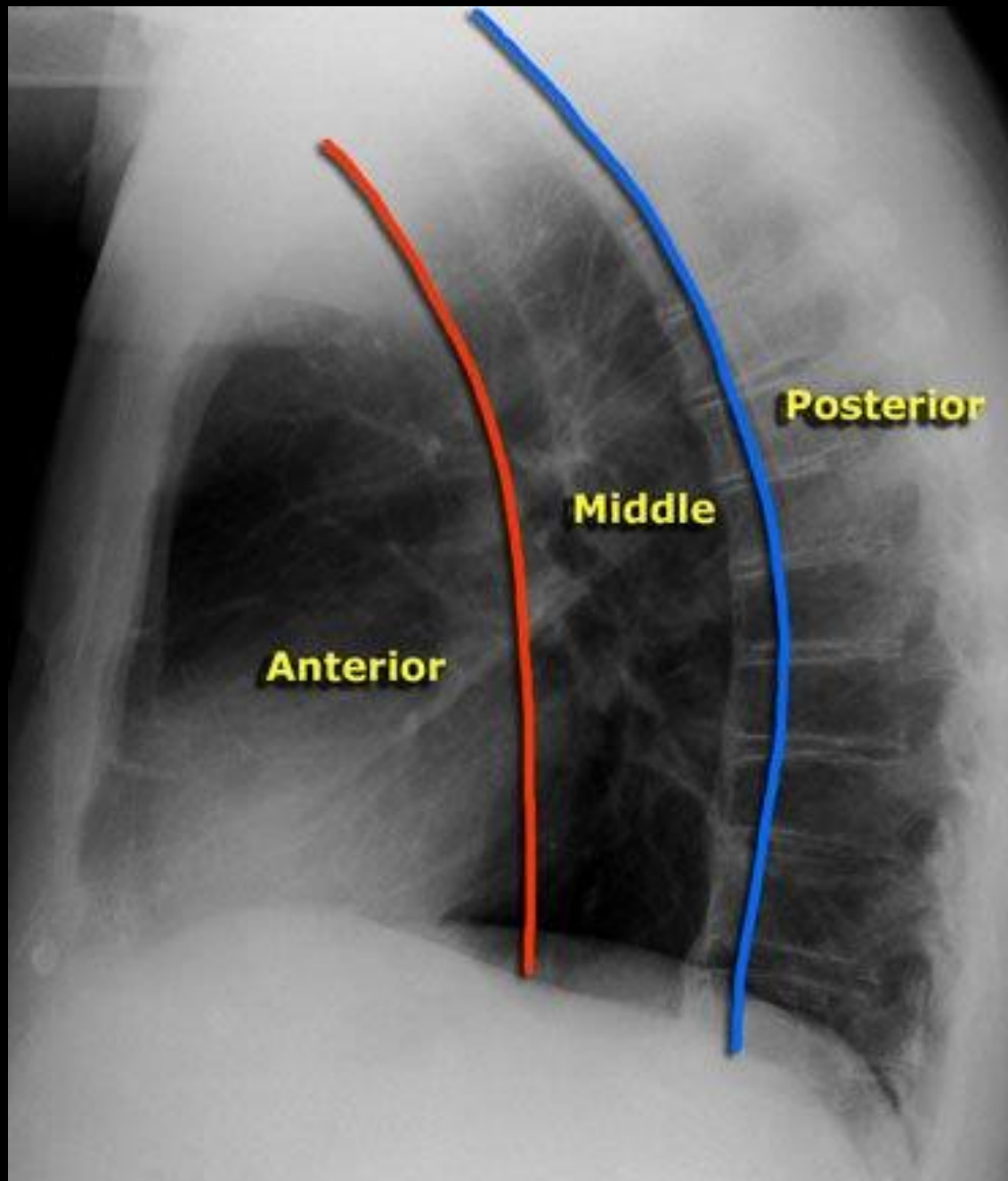
食道

肺門

Retrosternal triangle

Retrocardiac triangle





縱膈

前中後縱膈

Anatomy Landmarks

Anterior
Middle
Posterior

} mediastinum

- 氣管前緣-心臟後緣
- 椎體前緣向後1 cm

Mediastinum 縱膈

■ Shift

■ Widening

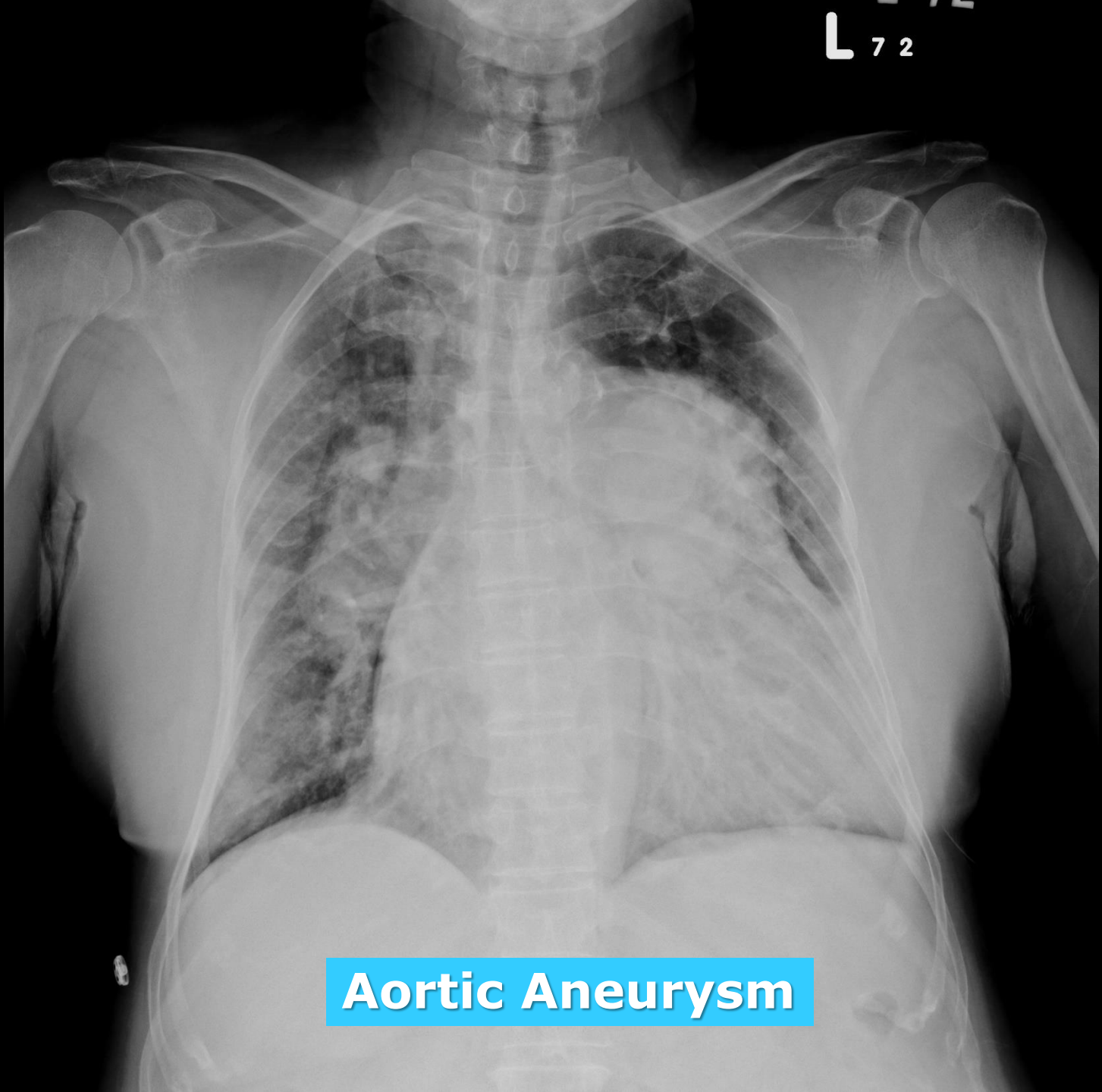
- Aortic aneurysm
- Lipomatosis
- Mediastinitis (air-fluid level)

■ Soft tissue density

- Mass, neoplasm

■ Air or air-fluid level

- Pneumomediastinum
- 食道病變 : esophagus reconstruction, esophageal cancer, achalasia
- Hernia



L 72

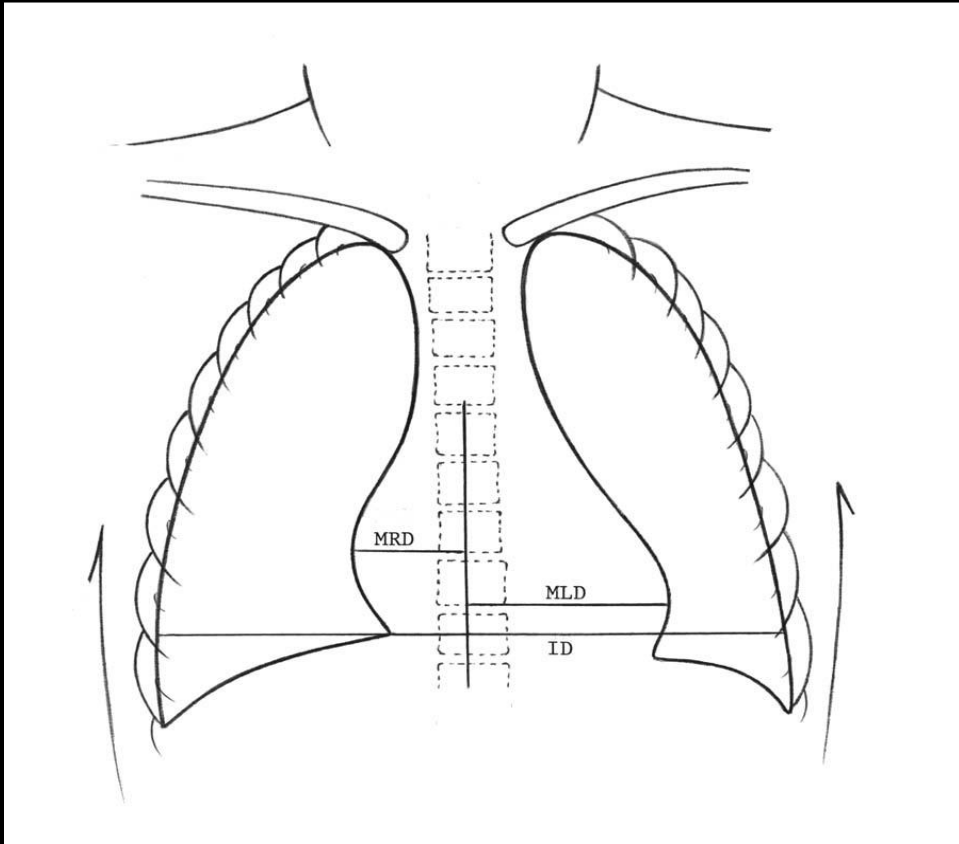
Aortic Aneurysm

Heart

- Size change: Cardiothoracic (C-T) ratio
- Signs:
 - Water bag: **Pericardial effusion**
 - Boot-shaped: **Tetrology of Fallot (TOF)**
 - Straight Lt heart border (Flat-waist sign) : LLL atelectasis
 - Double density of right heart border (Double contour sign): LAE
- Pericardiac mass : 心臟、橫膈、肺、其他縱膈腫塊
 - L: LV aneurysm
 - R: Morgagni hernia
 - R / L: Epicardial fat pad, pericardial cyst, diaphragmatic hernia, lung mass
- Pericardial calcification: **constrictive pericarditis**
- Retrocardiac density: 死角

Cardiothoracic Index

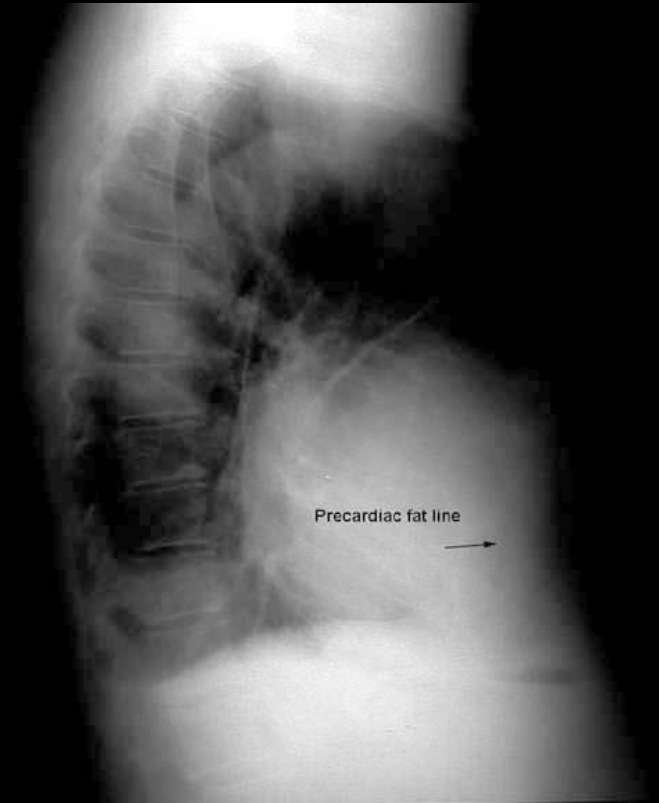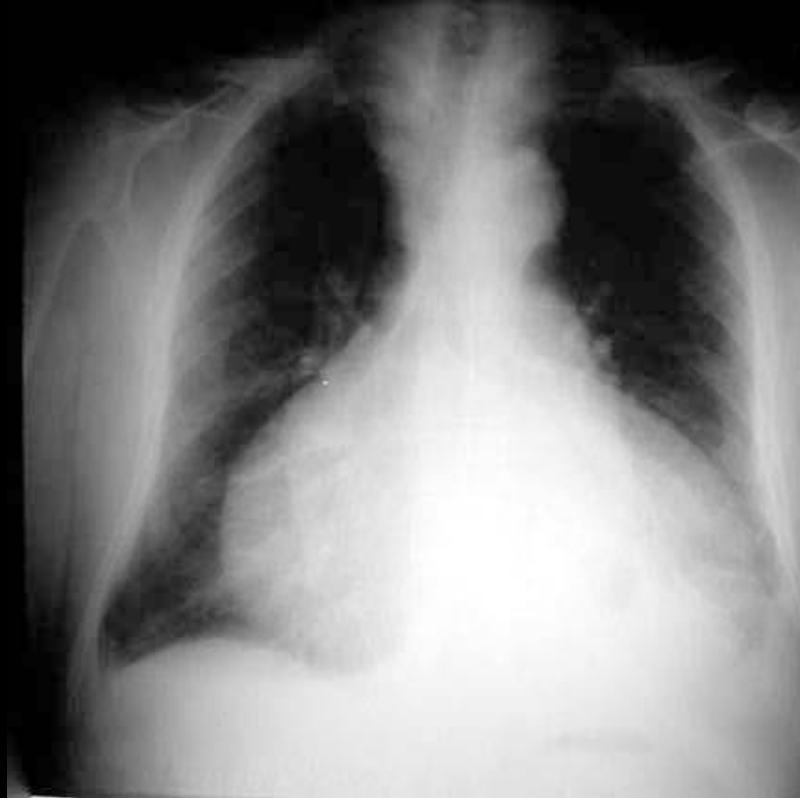正常成人 < 0.5 in PA view



- ID = internal diameter of chest at level of right hemi-diaphragm
- MRD = greatest perpendicular diameter from midline to right heart border
- MLD = greatest perpendicular diameter from midline to left heart border
- CT index = $(MRD + MLD)/ID$

Pericardial Effusion

- Enlarged "cardiac" density
- Water bottle appearance
- Pulmonary oligemia
- Precardiac fat line in lateral view below



Airway

- Diameter change: (Normal < 2-2.5cm)
 - Stenosis: Relapsing polychondritis
 - Dilate: tracheomalacia
- Deviation:
 - Pathological change
 - Aortic notch compression
- Tumor:
 - Tracheal tumor; hamartoma; carcinoid tumor; cylindroma
- Carina angle: (正常約75°; Rt : 30 °, Lt: 45 °)
 - < 60°: lower lobe volume reduction
 - > 90°: upper lobe volume reduction, LAE, pericardial effusion, subcarinal LAP

Hilum

■ 觀察重點：

- 大小、位置、形狀、濃度(density)

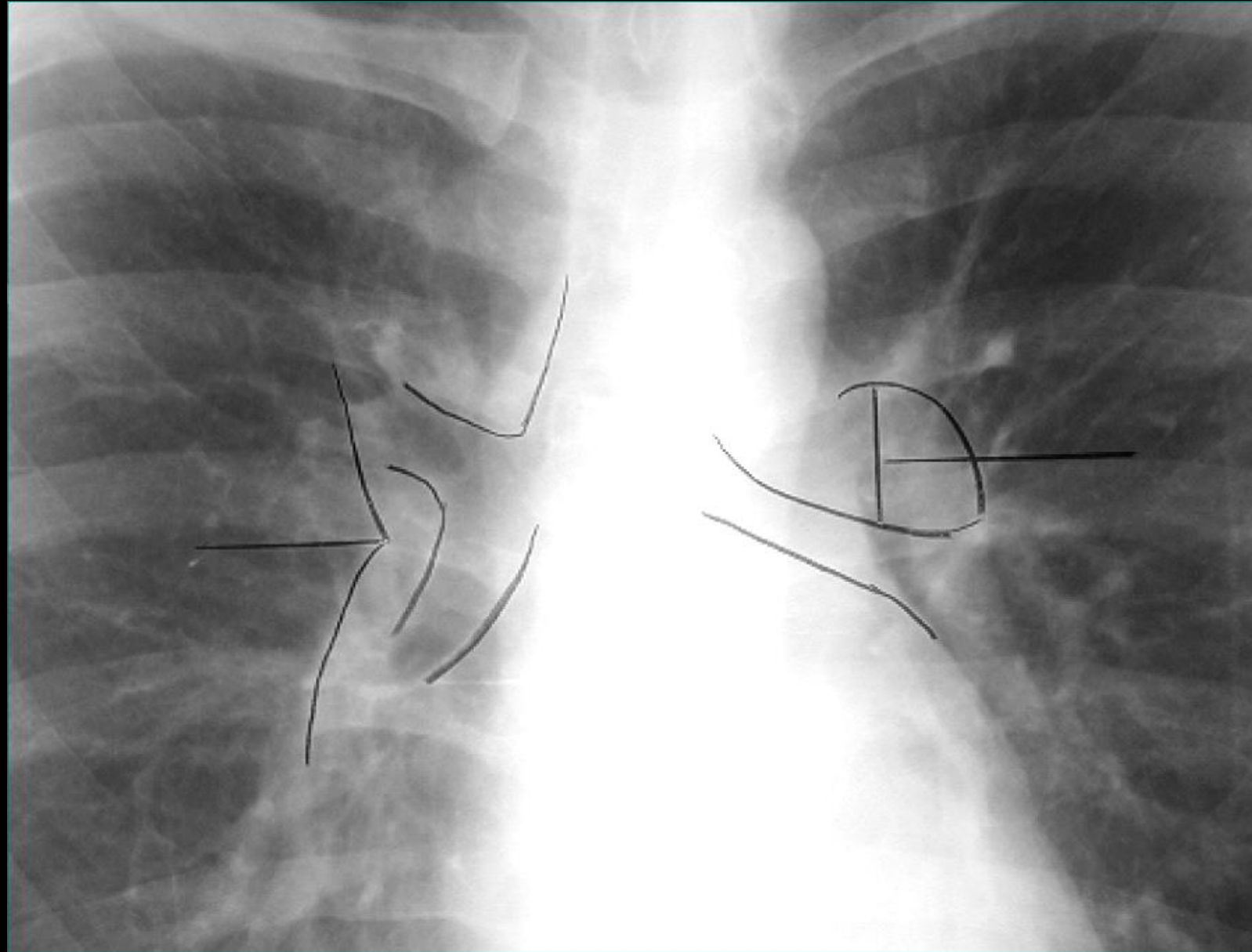
■ 位置：

- 正常：左高於右(97%，0.75-3cm，左右等高(3%))
- 異常：右高於左
- 右側肺門：R't superior pulmonary vein 和 inferior limb of R't pulmonary artery 的交點
- 左側肺門：Upper margin of L't pulmonary artery trunk and LMB 的中點

■ Hilum enlargement

- Hilar lesion
 - Vessel engorgement
 - Hilar LAP
- Superimposed mass(lung, mediastinum)

肺門定位法



Lung Fields

- 太白太黑都要注意
- 兩側相互比較
- 單側hemithorax density異常
 - lesion site是太白處or太黑處
- Increased opacity(太白)
 - Abnormal shadows
- Increased radiolucency(太黑):由外而內D/D
 - 胸廓外：mastectomy, **Poland's syndrome**(少了大胸肌)
 - 肋膜：**pneumothorax**
 - Decreased vessel: pulmonary embolism(a), Pul. a. agenesis(a), Scimitar syndrome(v)
 - Air collection: **endobronchial obstruction, Swyer-James syndrome emphysema, localized bullae**

Trachea and Esophagus (Lateral View)

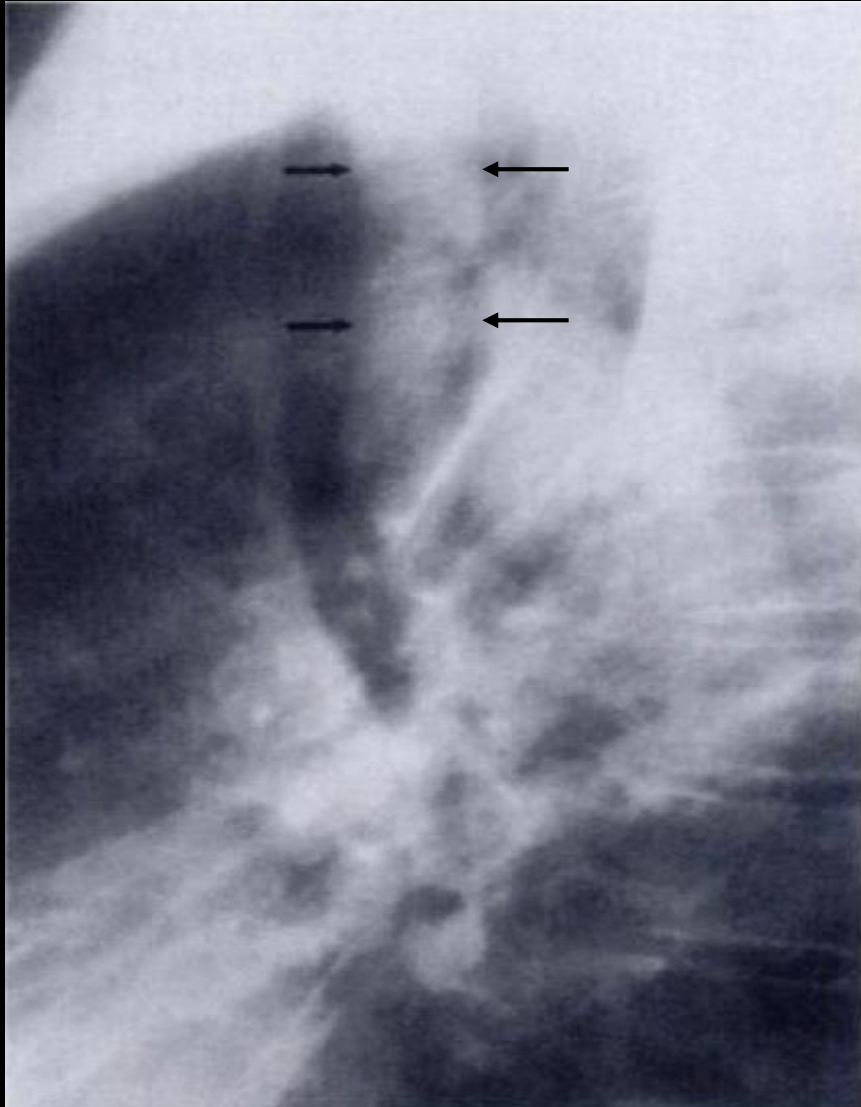
■ Trachea:

- 注意endotracheal內有無腫瘤陰影或狹窄
- 如果trachea後方有腫瘤或是LAP，會把氣管往前推擠。

■ Esophagus

- 正常Posterior tracheal strip < 3mm，當>4mm時為異常。應該懷疑食道疾病。
- Abnormal air-fluid level: achalasia, esophageal cancer, post-operative change with reconstruction

Esophageal cancer

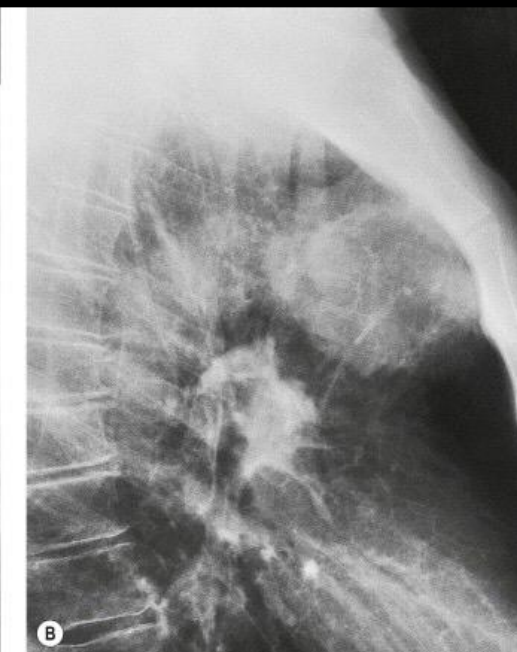
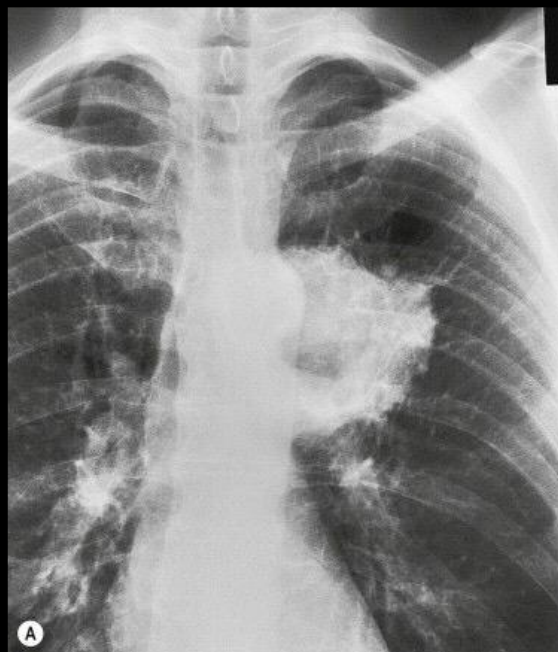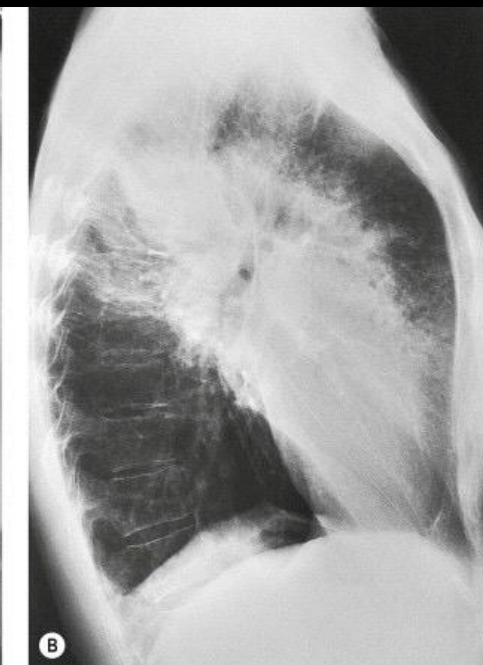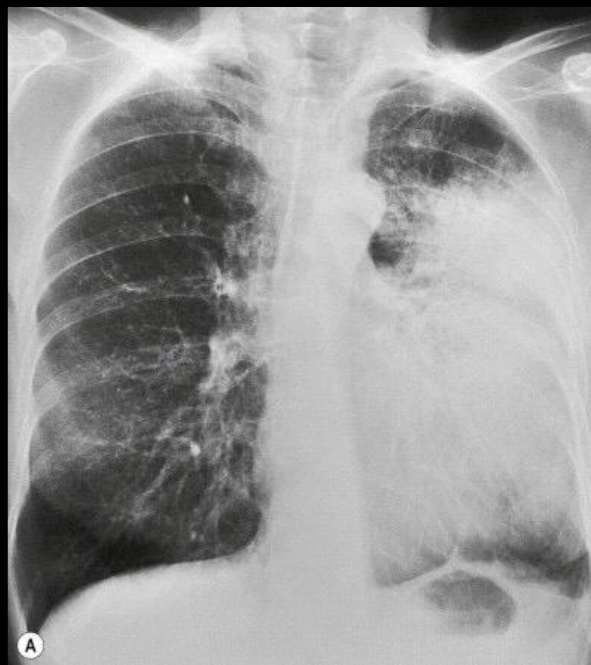


Thickened posterior paratracheal stripe

Signs of Chest Radiograph

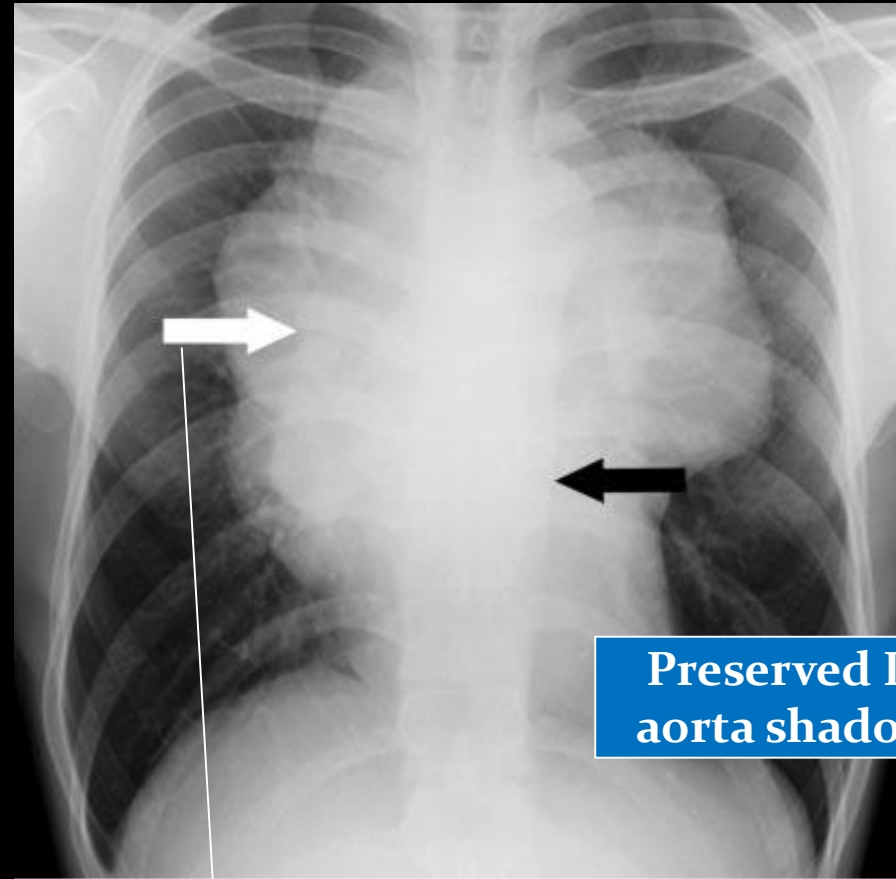
Silhouette Sign (輪廓癥)

兩個密度相近物質直接靠在一起時，兩者的界線在X光上是分不出來的



Hilum Overlay Sign

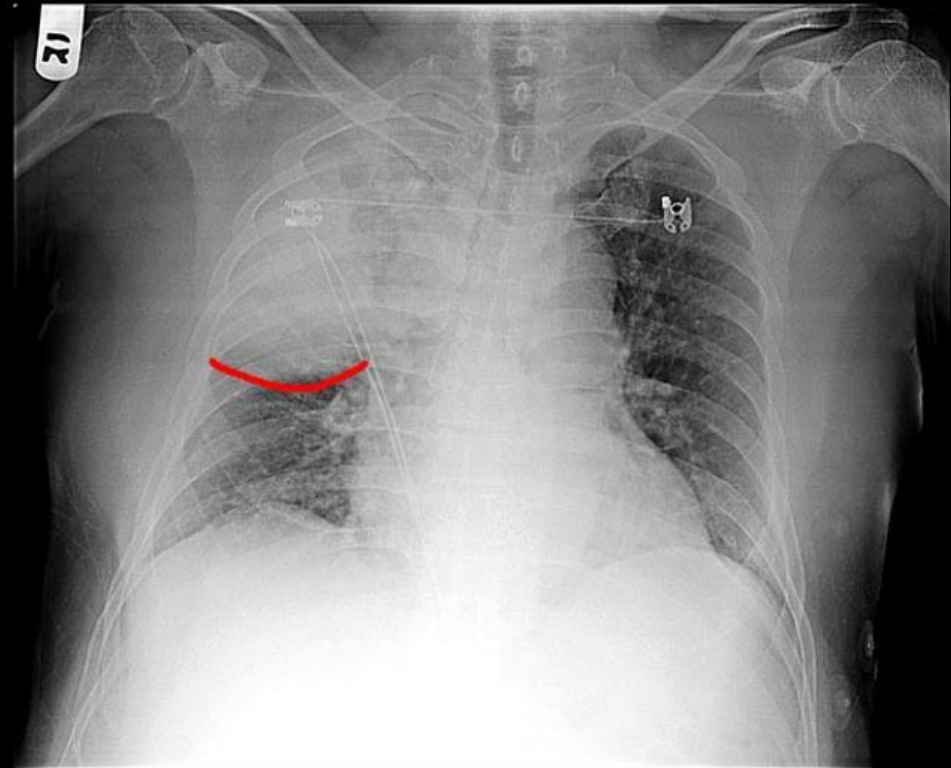
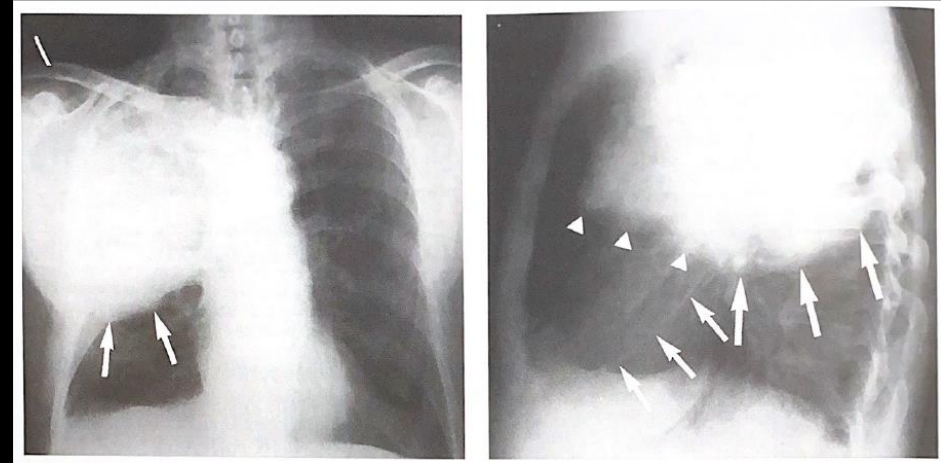
- 用來區分肺門附近的病灶是 mediastinal mass 或 vascular lesion .
 - 若 pulmonary artery 的第一個分叉點在 lesion 外緣的 內側 且大於 1cm 以上 - favor mediastinal mass



Hilum overlay sign

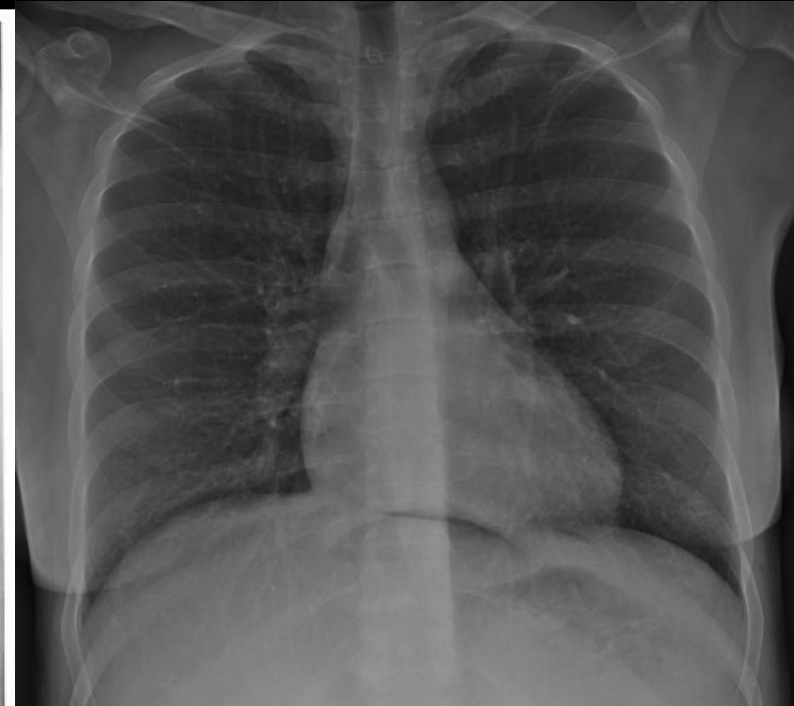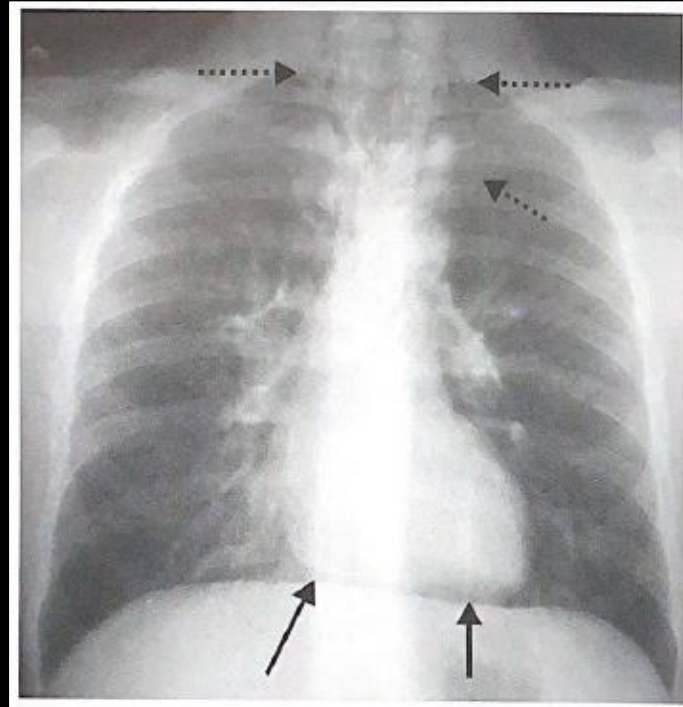
Bulging fissure sign

Pneumonia caused by
Klebsiella pneumoniae



Continuous diaphragm sign

Pneumomediastinum



Fallen lung sign

The appearance of the collapsed lung occurring with a fractured bronchus.

- the bronchial fracture results in the lung "falling" away from the hilum, either inferiorly and laterally in an upright patient. (posteriorly in supine patient)
- Normally, a pneumothorax causes a lung to collapse inward toward the hilum.

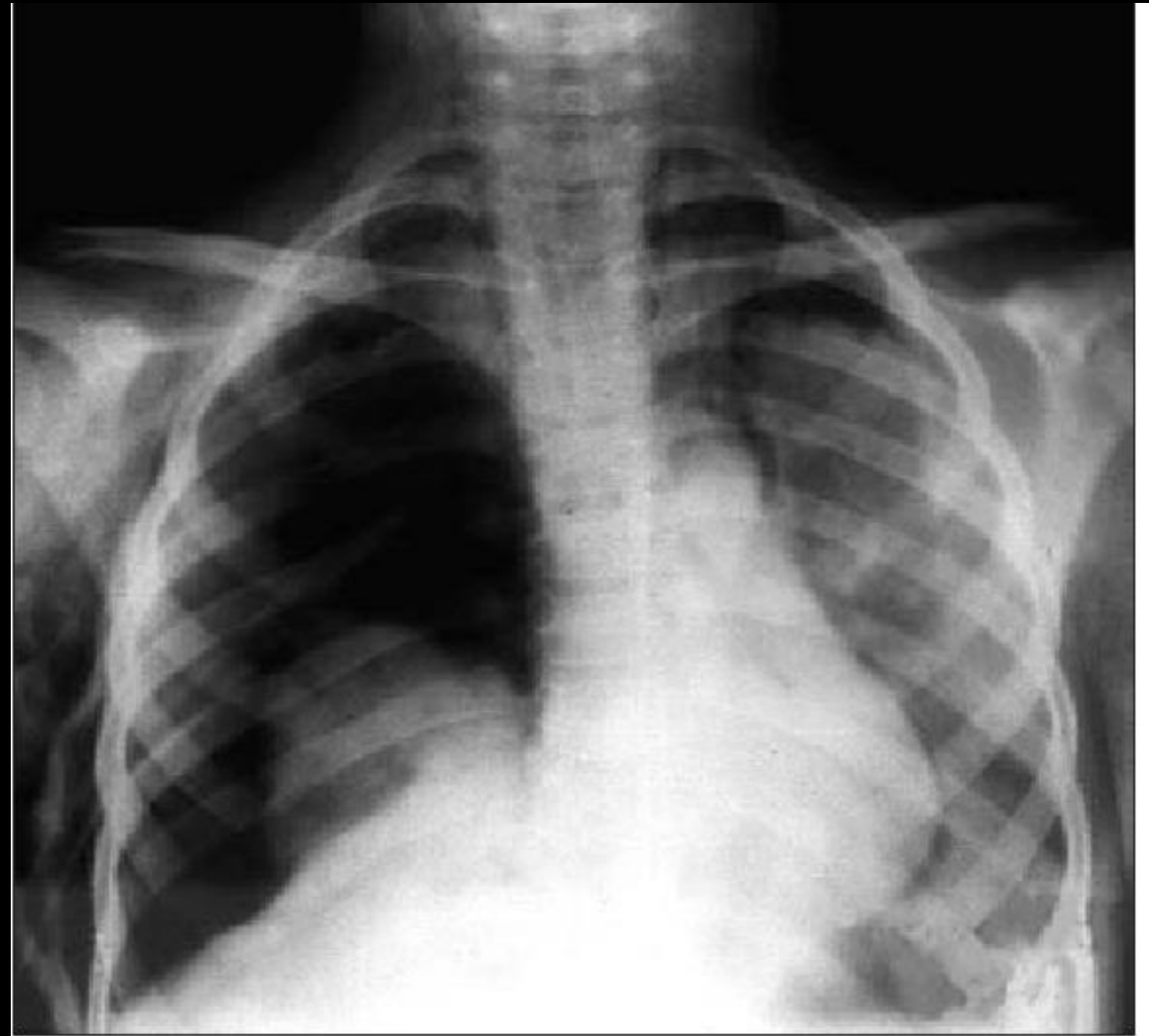
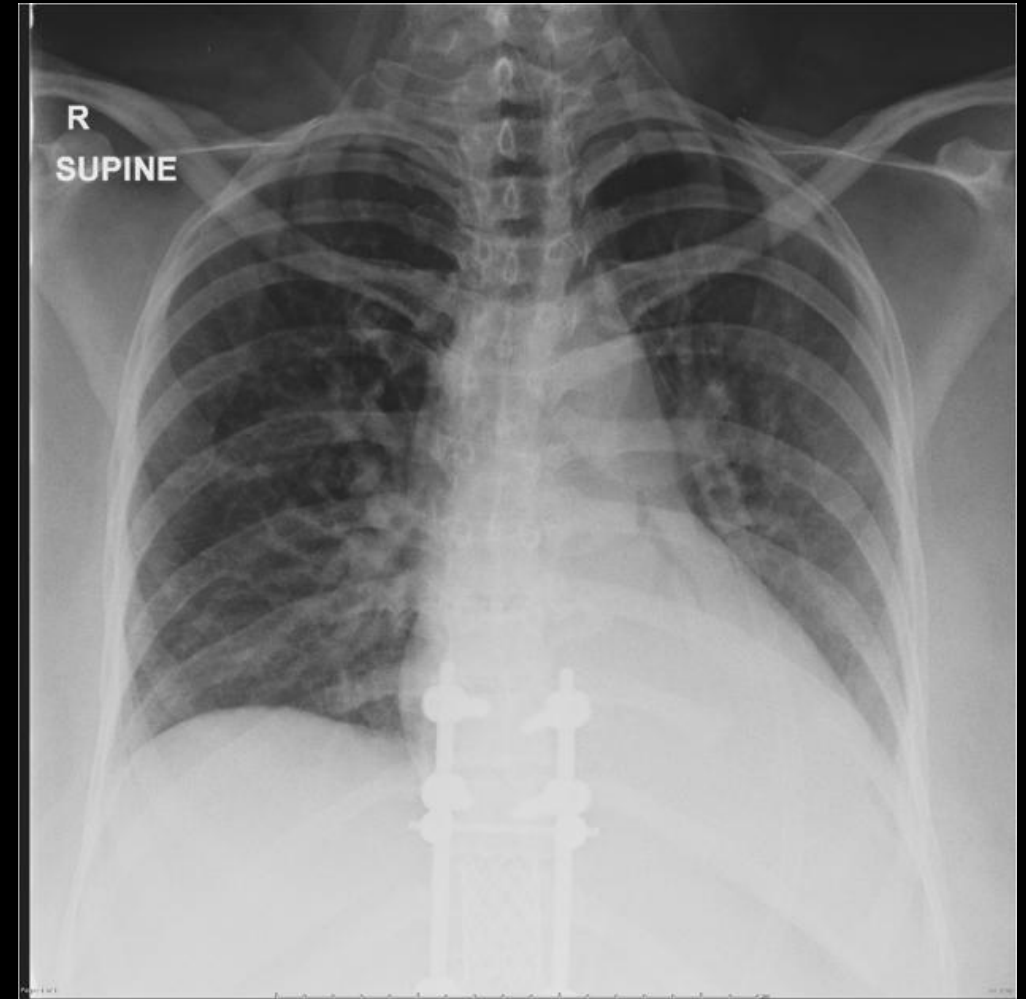


Figure 2. Chest radiograph obtained six hours after the initial

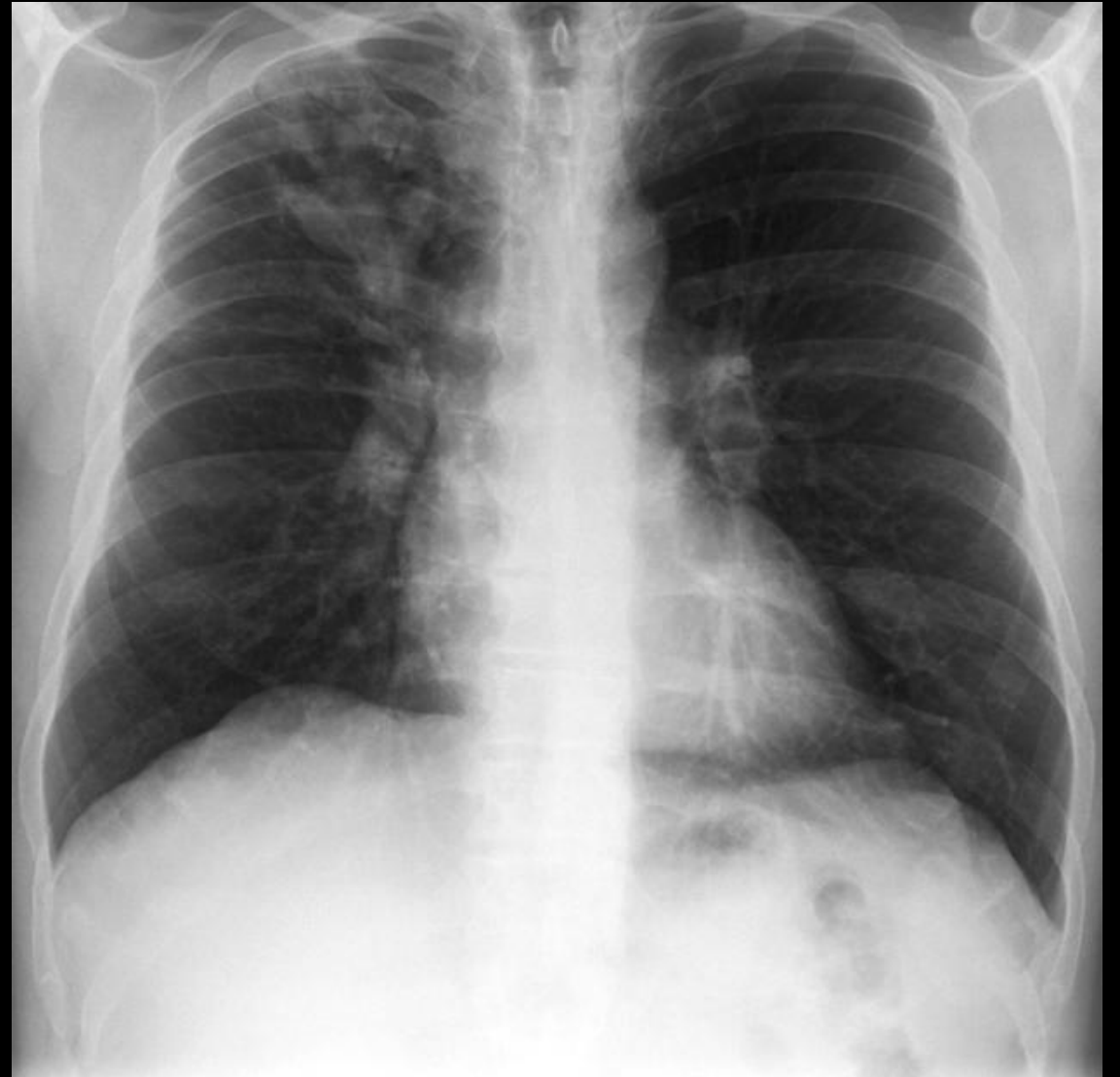Flat Waist sign

- Flatten of the contours of the aortic knob and adjacent main pulmonary artery.
- Severe collapse of the LLL and is caused by leftward displacement and rotation of the heart.



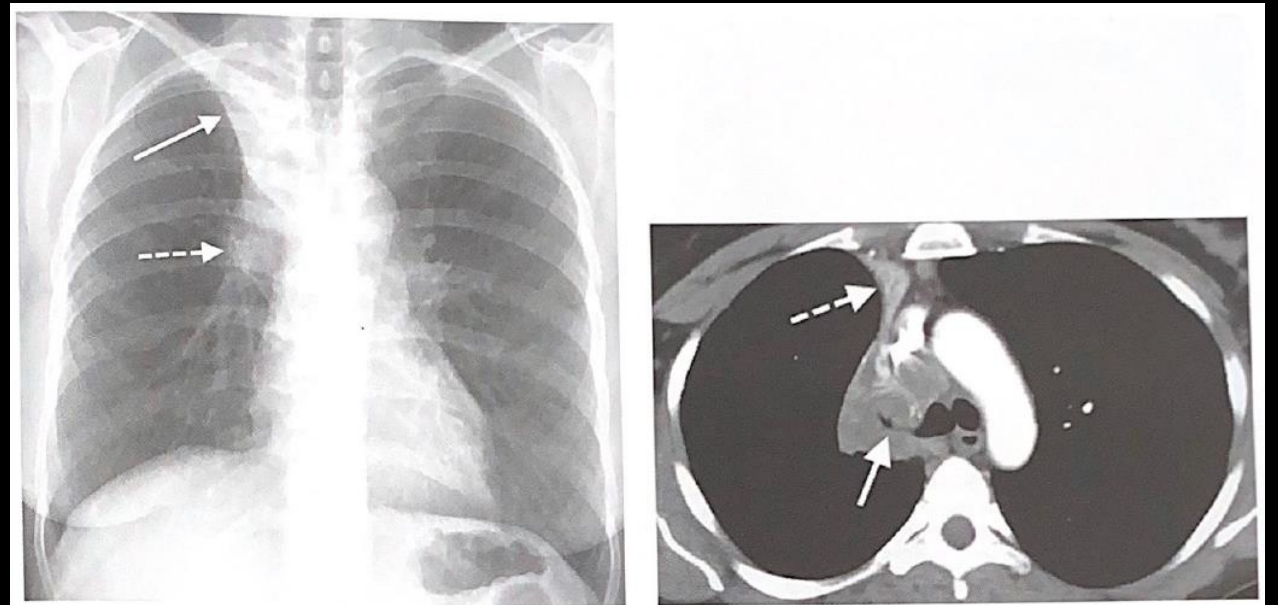
Finger-In-Glove sign

- ABPA
- Gloved finger, Y, V, inverted V, tooth paste



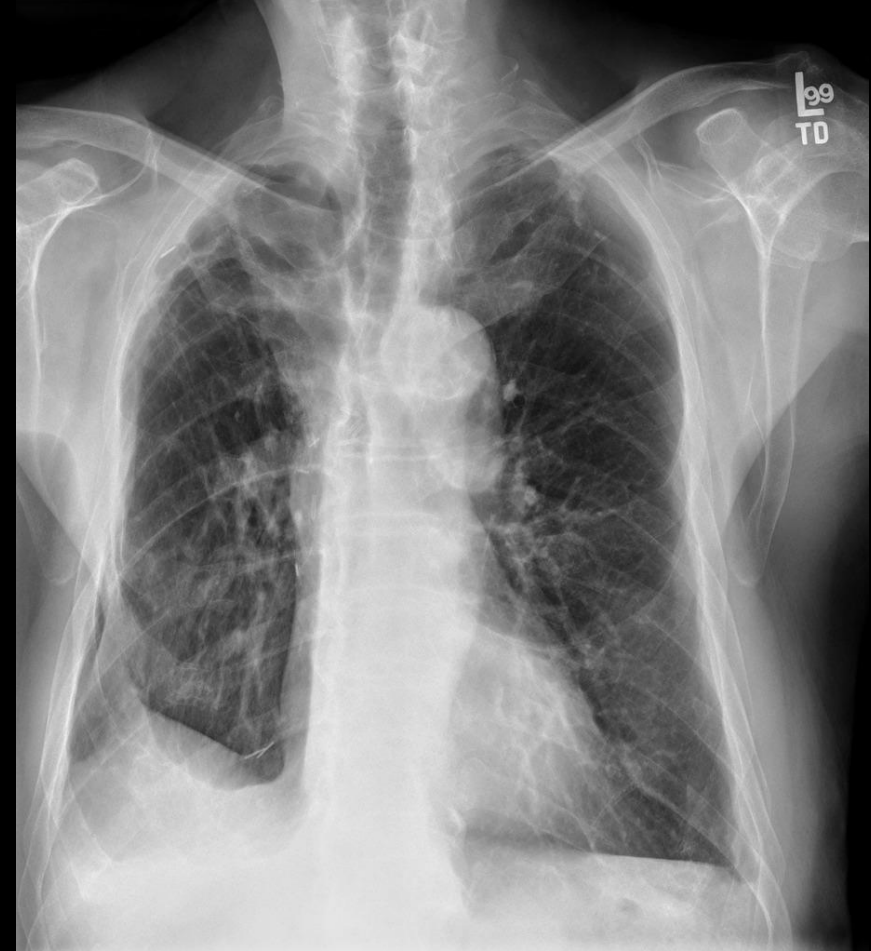
Golden S sign

Lobar collapse around a large central mass



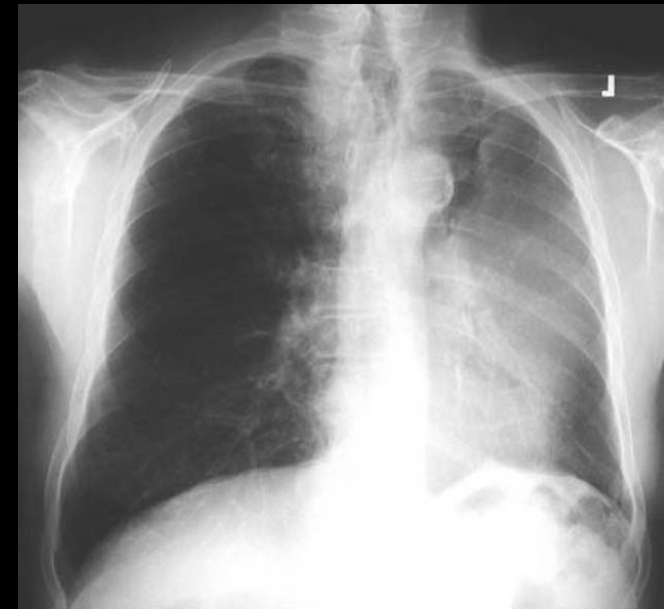
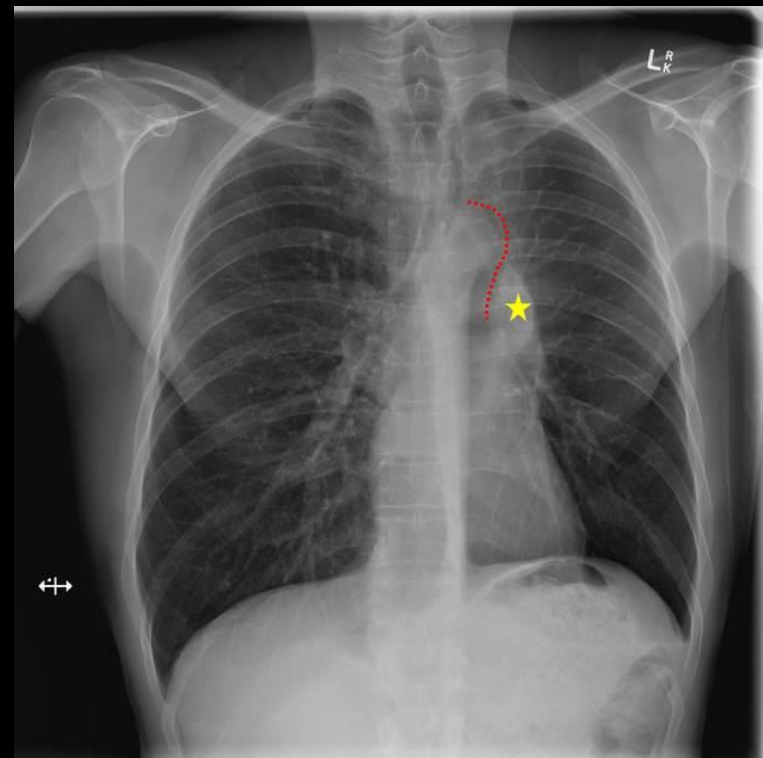
Juxtaphrenic Peak sign

- Small triangular shadow that obscures the dome of the diaphragm
- Traction on the lower end of the major fissure, the inferior accessory fissure, or the inferior pulmonary ligament



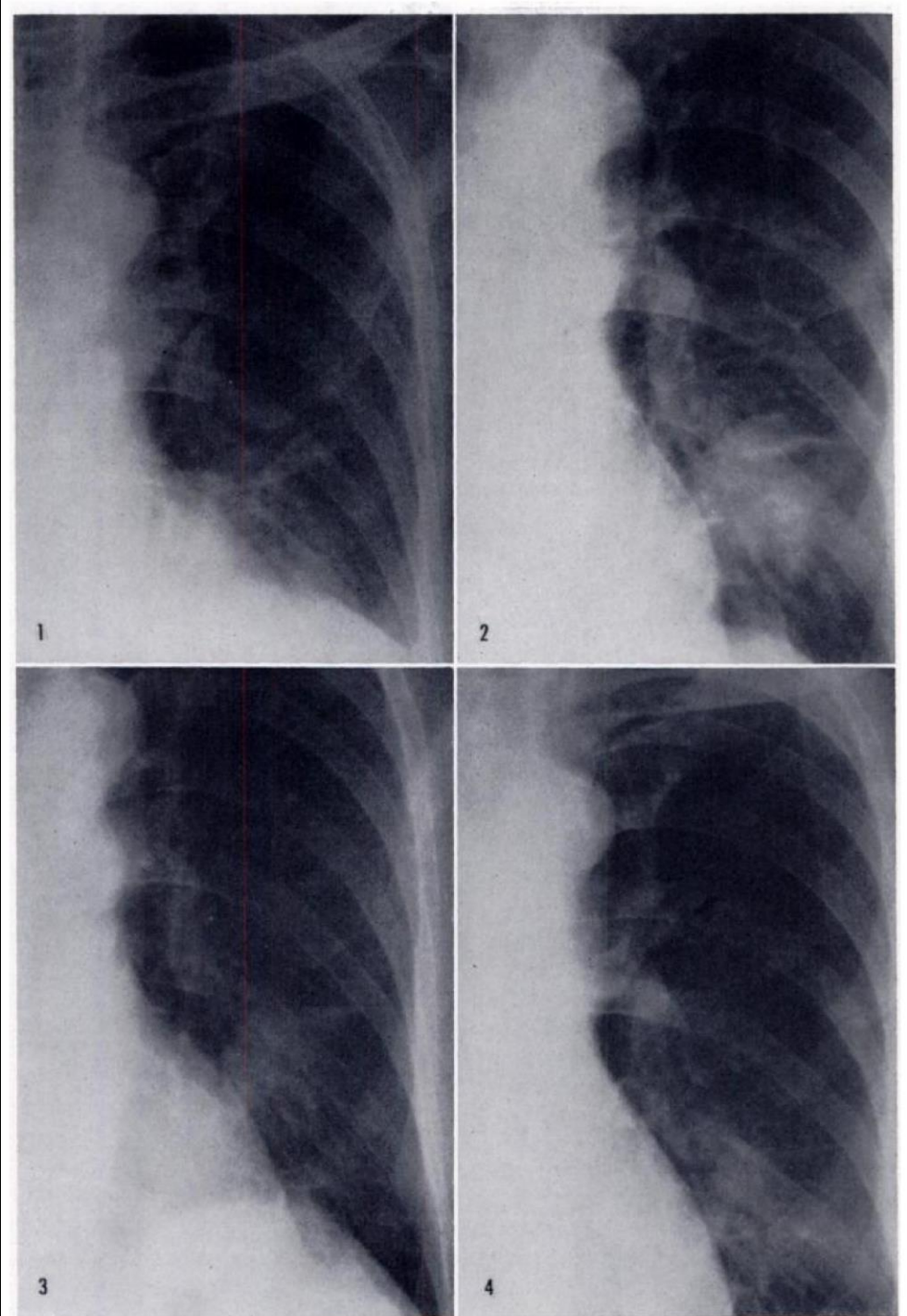
Luftsichel sign

- LUL collapse
- The sup. Segment of the LLL (hyperinflated), is positioned between the aortic arch and the collapsed LUL
- This aerated segment of LLL is hyperlucent and shaped like a sickle
- *Luft (air), sichel (sickle)*



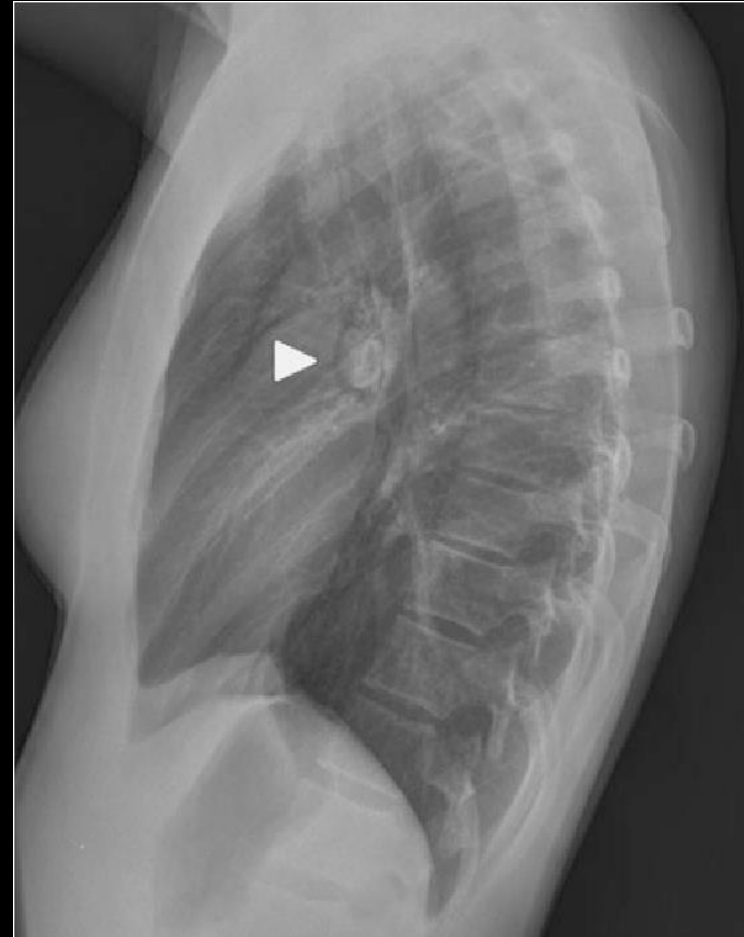Melting Ice Cube sign

- Appearance of a resolving pulmonary infarct
- An ice cube that is melting peripherally to internally



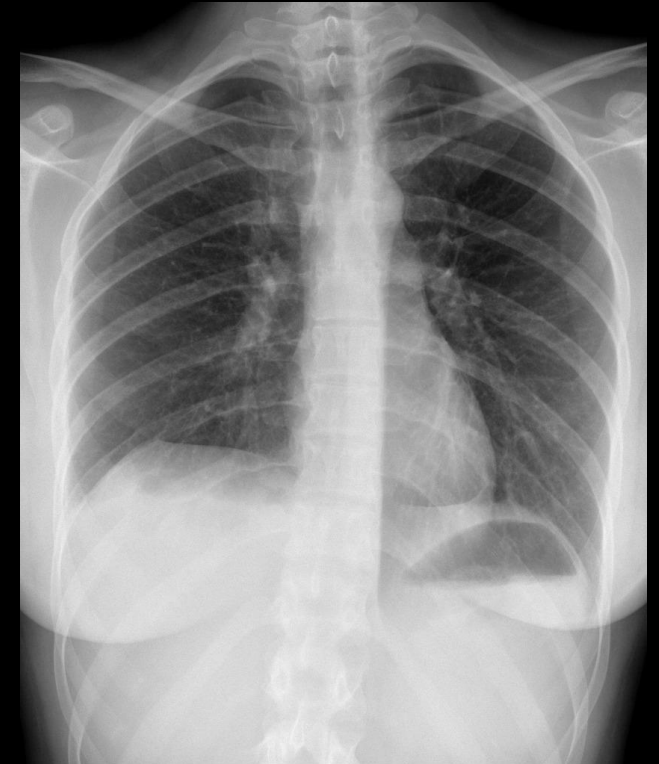
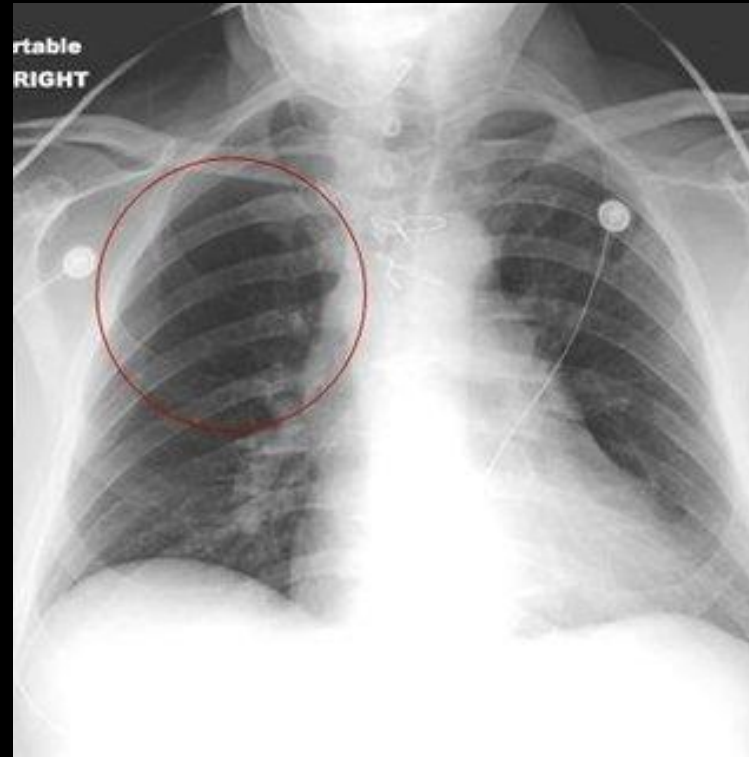
Ring around the artery sign

- Well-defined lucency encircling the right pulmonary artery
- Pneumomediastinum



Westermark sign

Oligemia of the lung beyond an occluded vessel in a patient with pulmonary embolism



盲點：常見的判讀陷阱(四大死角)

- Bilateral Apex
- Large Airway
- Retrocardiac region
- Bilateral lung bases (especially sub-diaphragm)

Pitfalls in Chest X-Ray Interpretation

- 一、吸氣不良或照射條件不佳
- 二、誤認正常影像為空洞或結節
- 三、肺外假影
- 四、肺外病變誤認為肺實質病變
- 五、可消失的假影誤認為腫瘤
- 六、假性透光性增加
- 七、病灶在縱膈腔？肺實質？或血管影像？


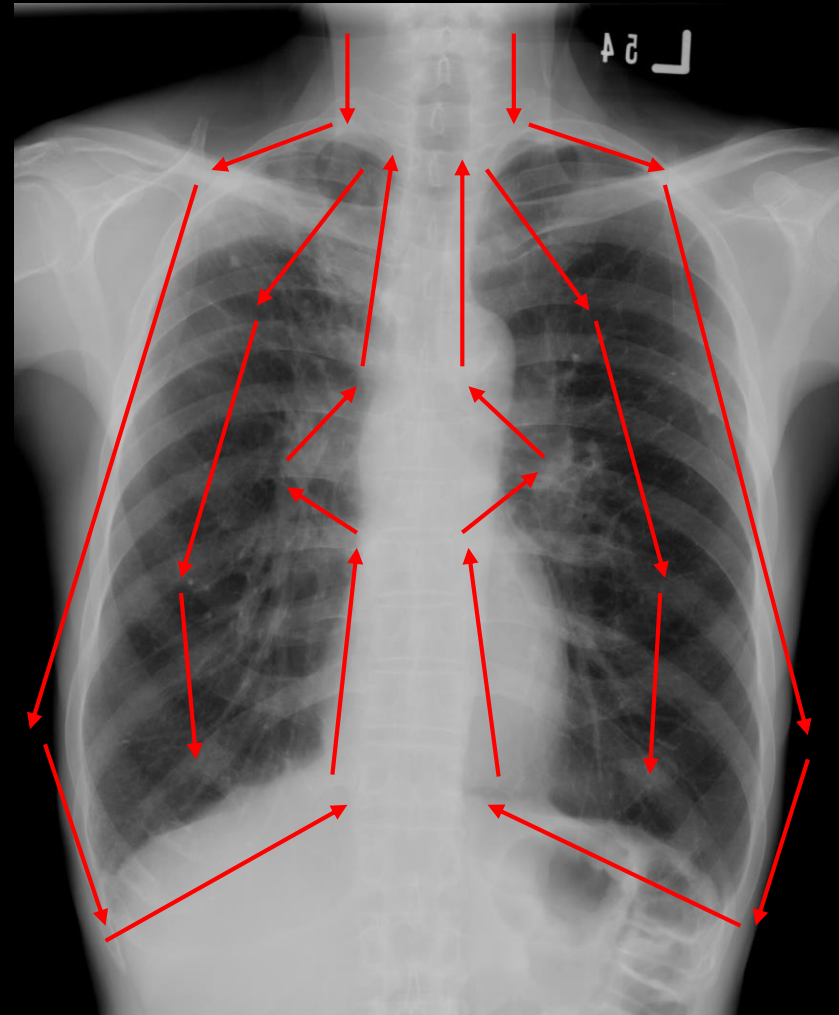
總結

Steps of Image Interpretation

1. 確定片子的照相品質是良好的
2. 找出真正的異常病灶，並確定其位置
3. 描述它的pattern
4. 作鑑別診斷
5. 配合臨床資訊和數據來縮小鑑別診斷的範圍
6. 安排其他檢查確定診斷

A suggested approach (蛙式讀片法)

- Type and quality of the radiograph
- Chest wall: soft tissues and bone
- Diaphragm and pleural boundaries
- Mediastinum
- Lung parenchyma
- Foreign material



Normal CXR ??記得要先排除這些問題

1. Cervical rib, fork rib
2. 左右放反 (Dextrocardia, Situs inversus)
3. Mastectomy
4. Endotracheal or endobronchial lesion
5. Extrapulmonary soft tissue
6. 四個死角 (apex, retrocardia, subdiaphragm, retrocardiac)
7. Artifact (nipple, hair braid)
8. Pneumothorax
9. Malposition of medical device (NG, CVP, endotracheal tube..)

Pattern

- Pulmonary / Extrapulmonary

- Multiple / Solitary

- Alveolar / Interstitial

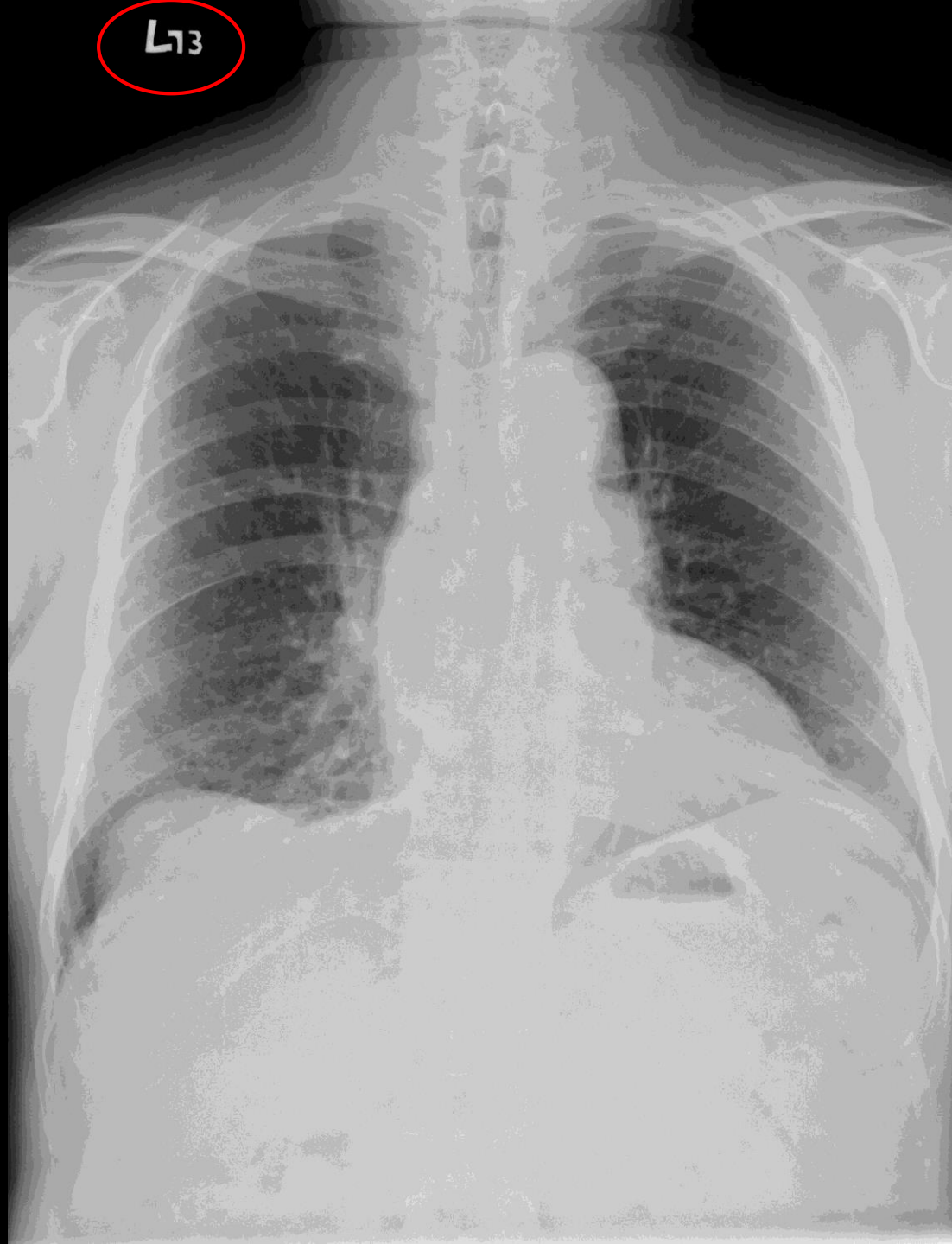
- Diffuse / Focal

鑑別診斷

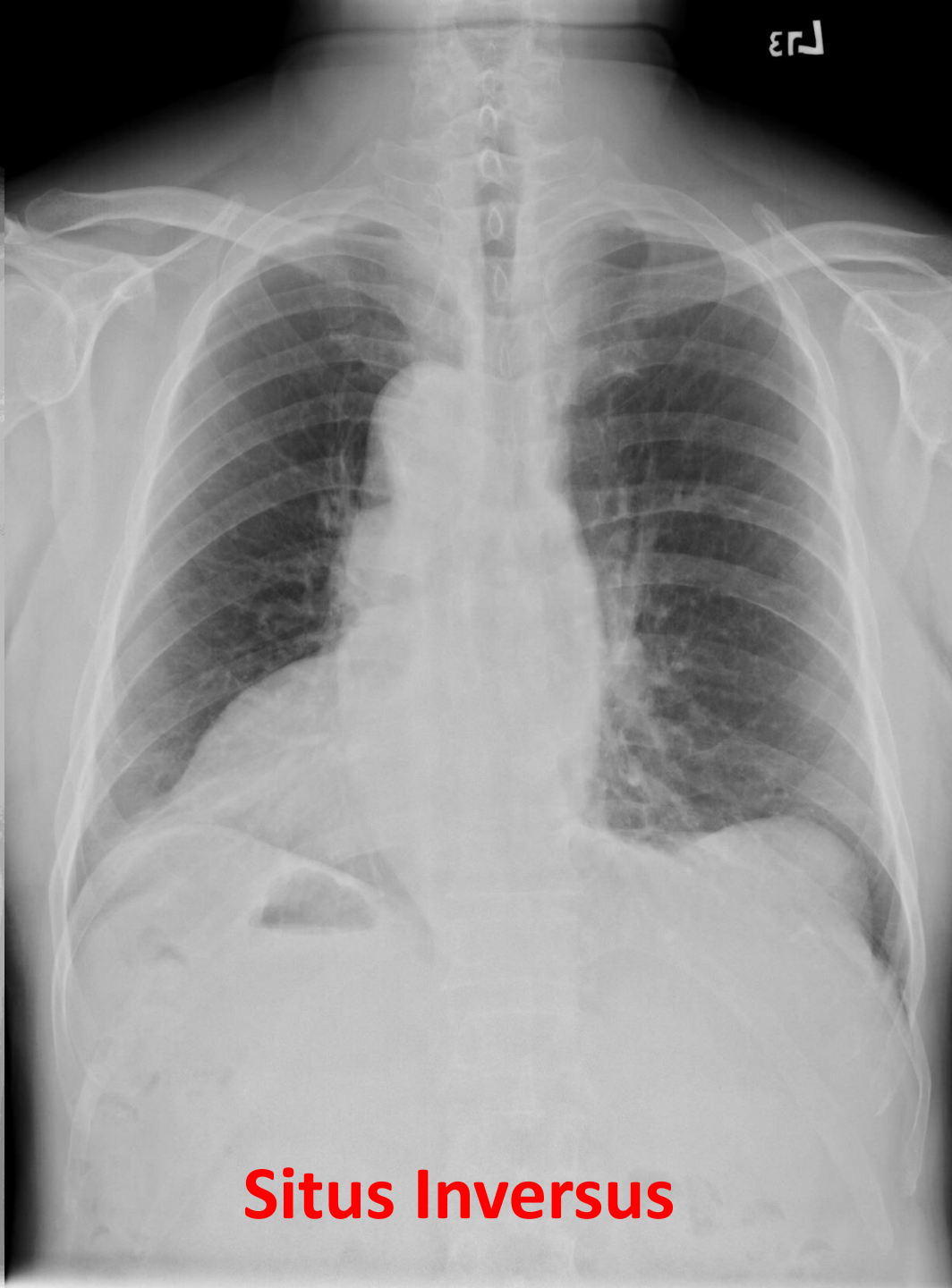- H: hemodynamic
- I: infection
- I: inflammation
- N: neoplasm
- 遺傳: congenital
- 職業: occupation
- 暴露: exposure
- 全身: systemic disease
- 肉芽腫: granulomatous disease

Quiz

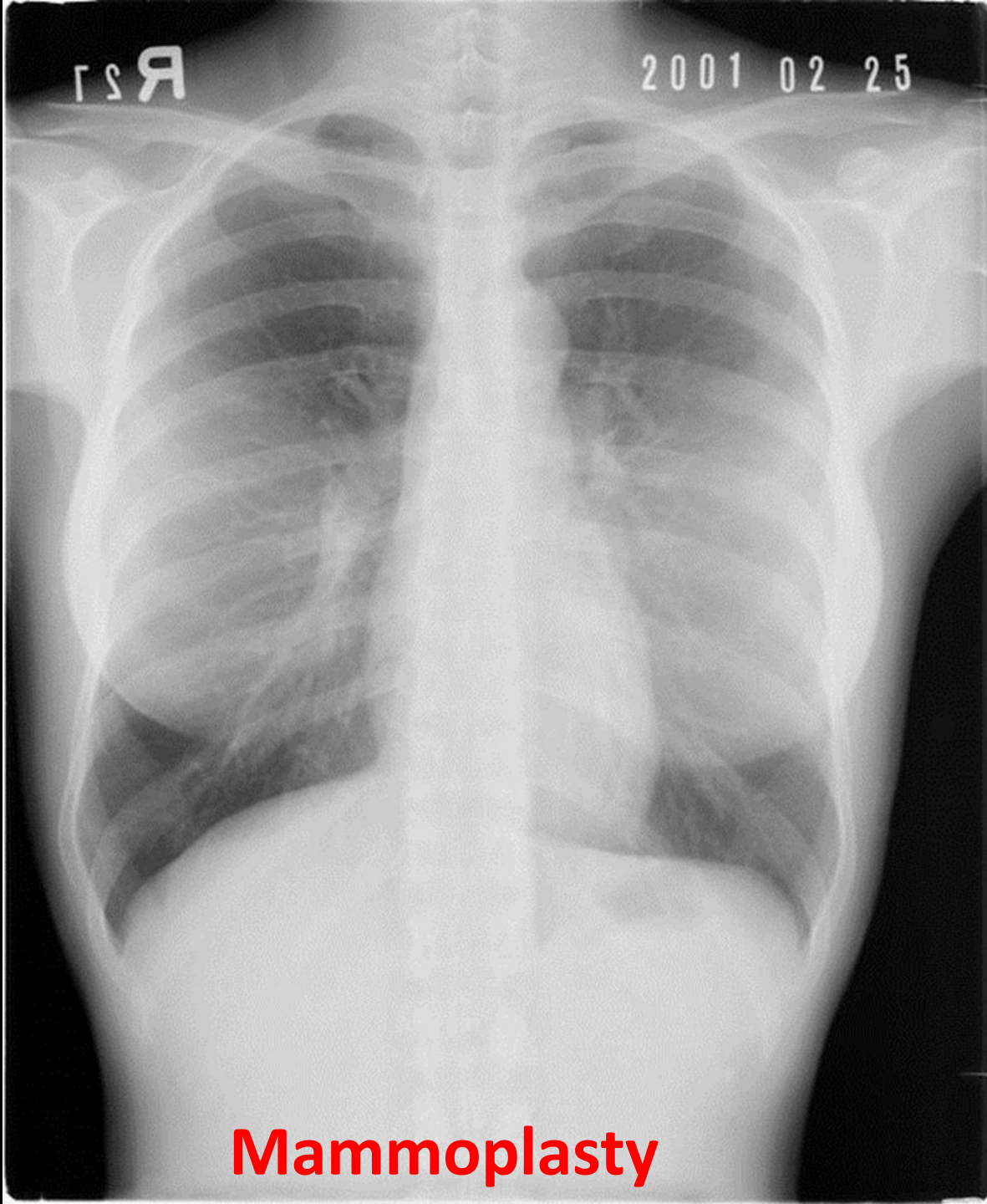L73



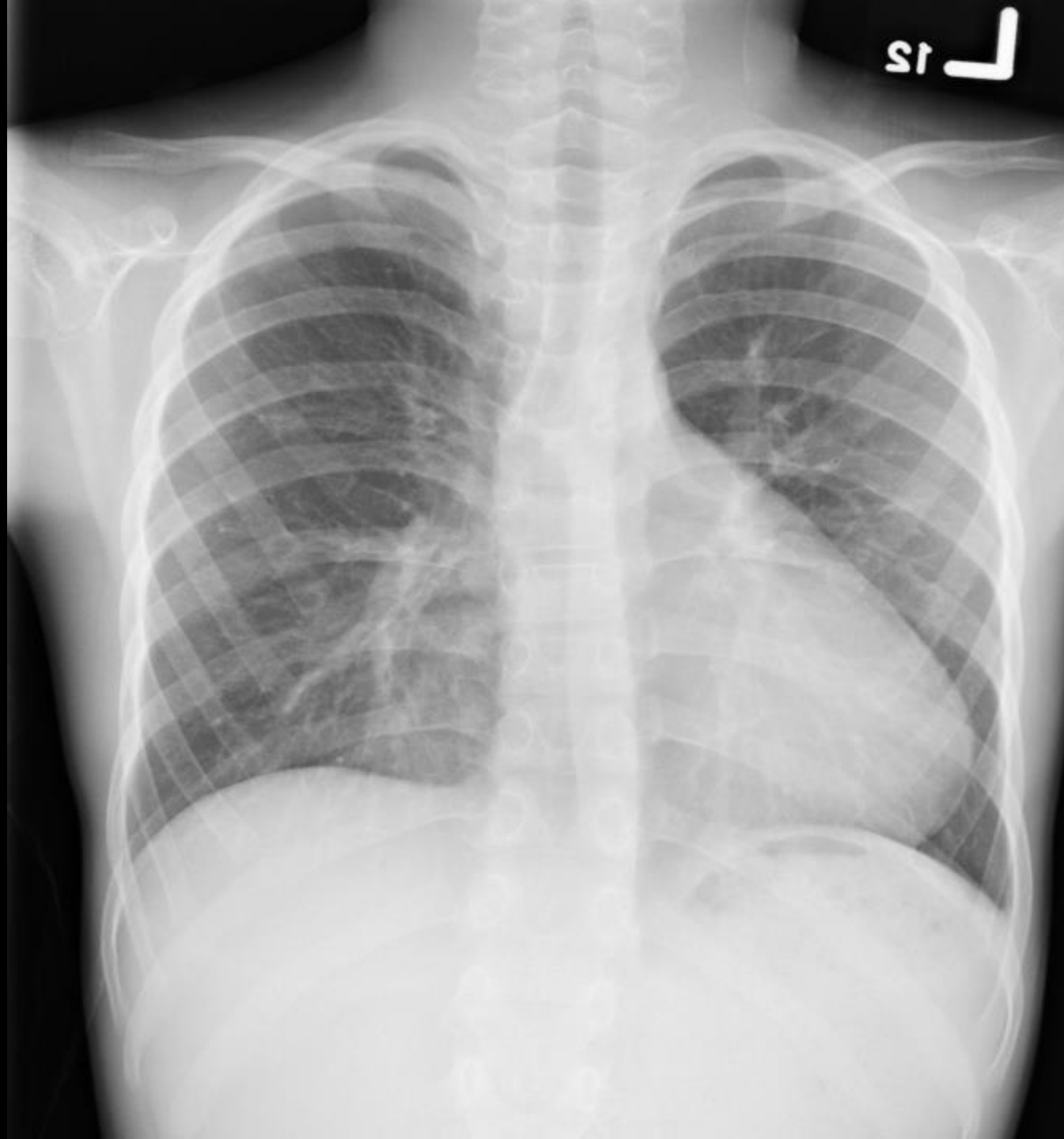
εΓ



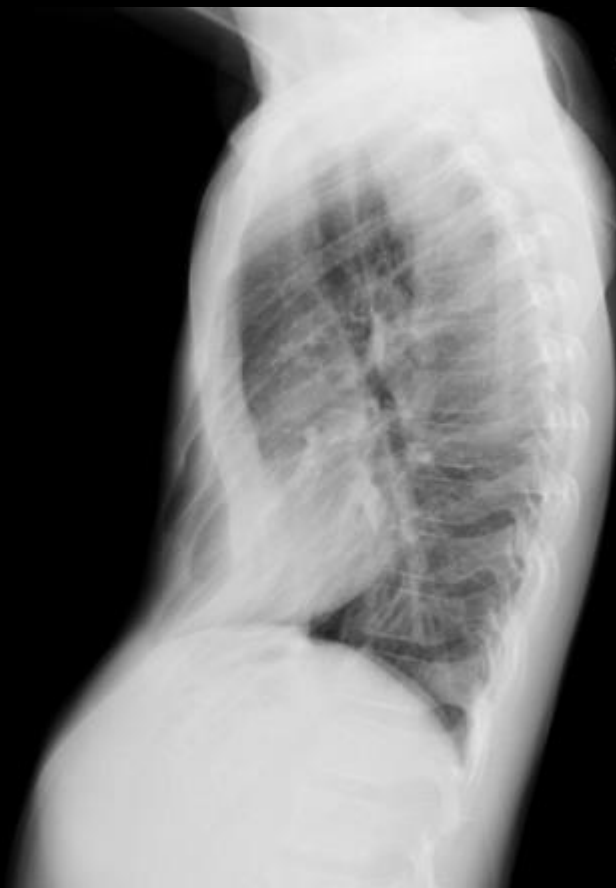
Situs Inversus

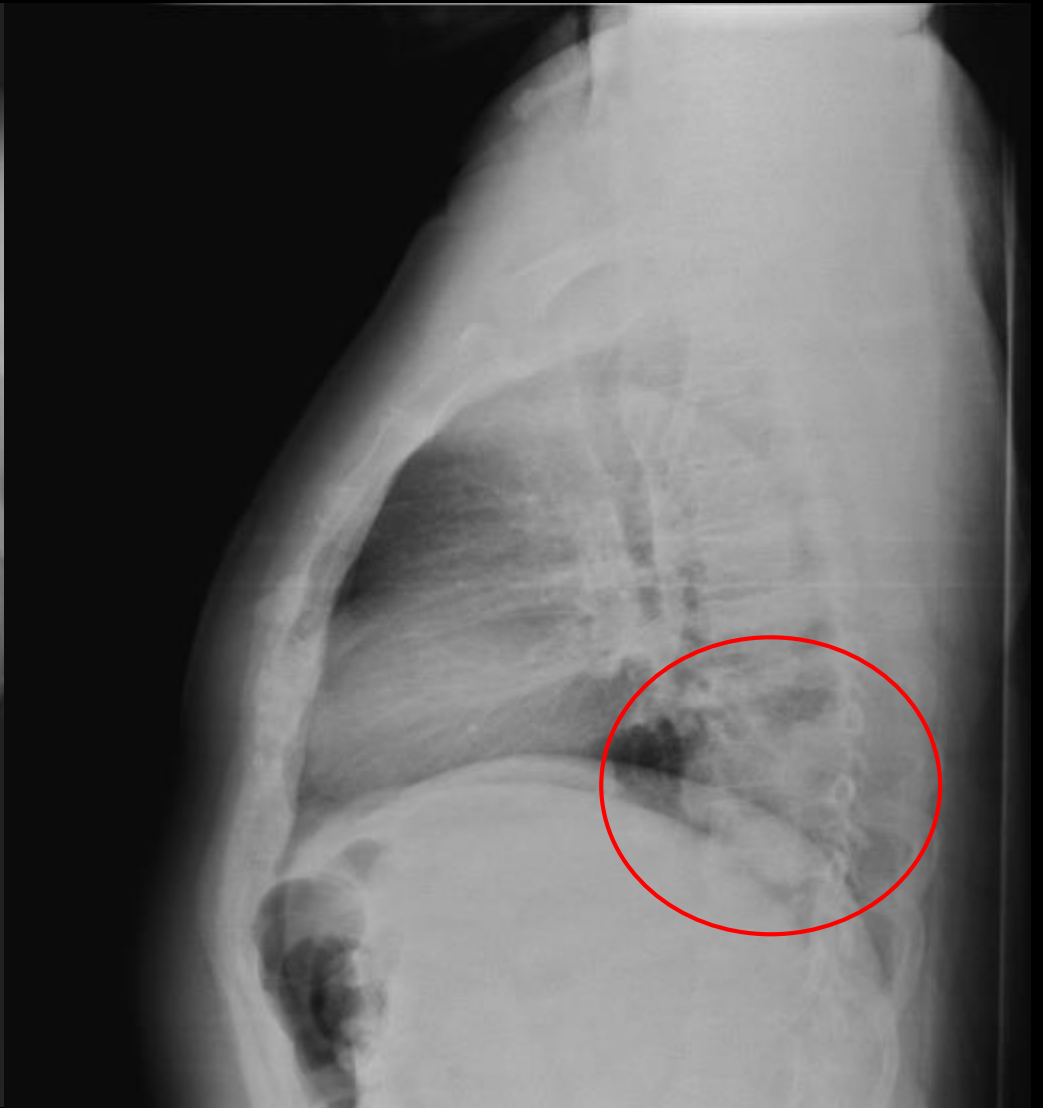
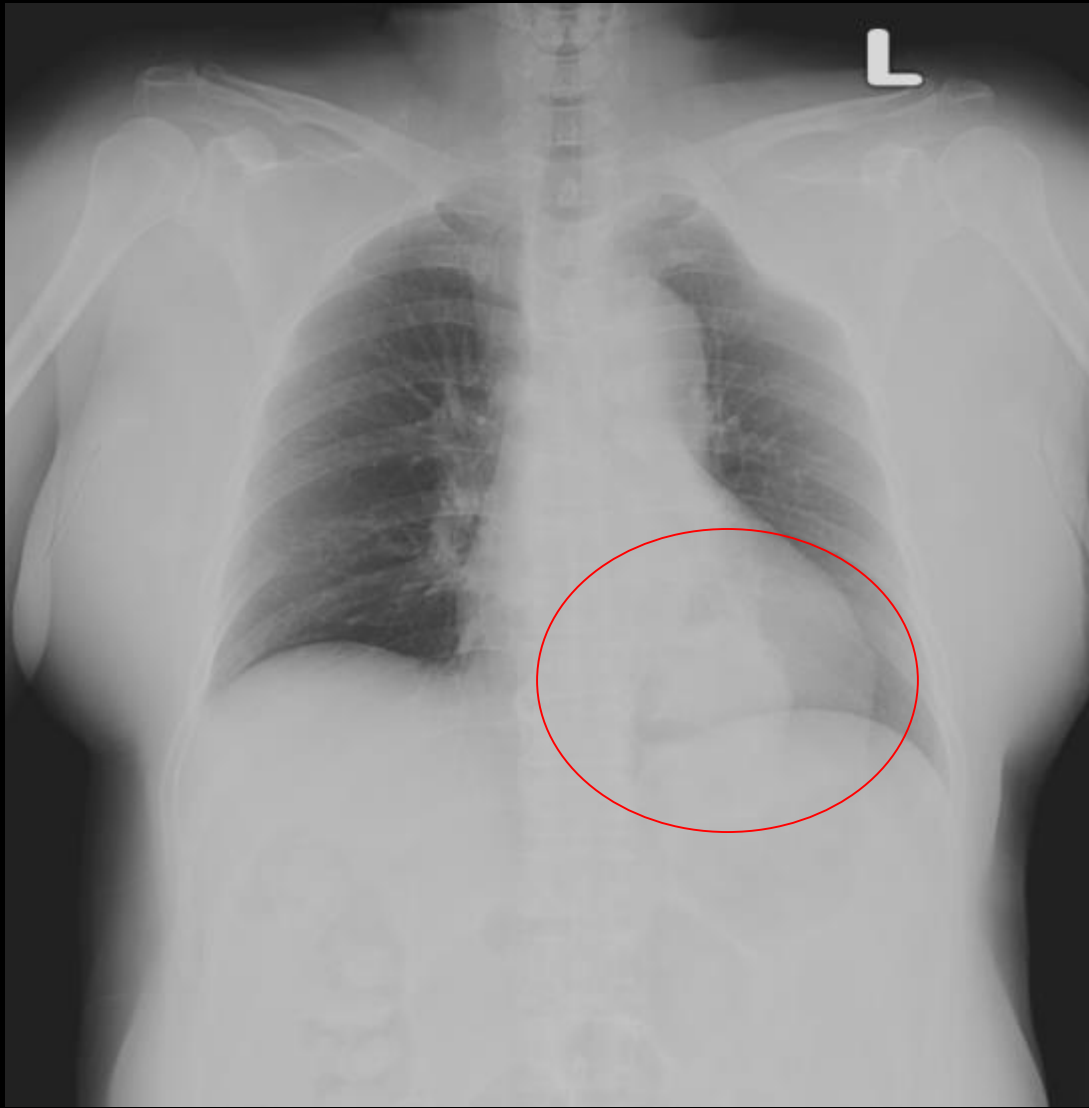


Mammoplasty

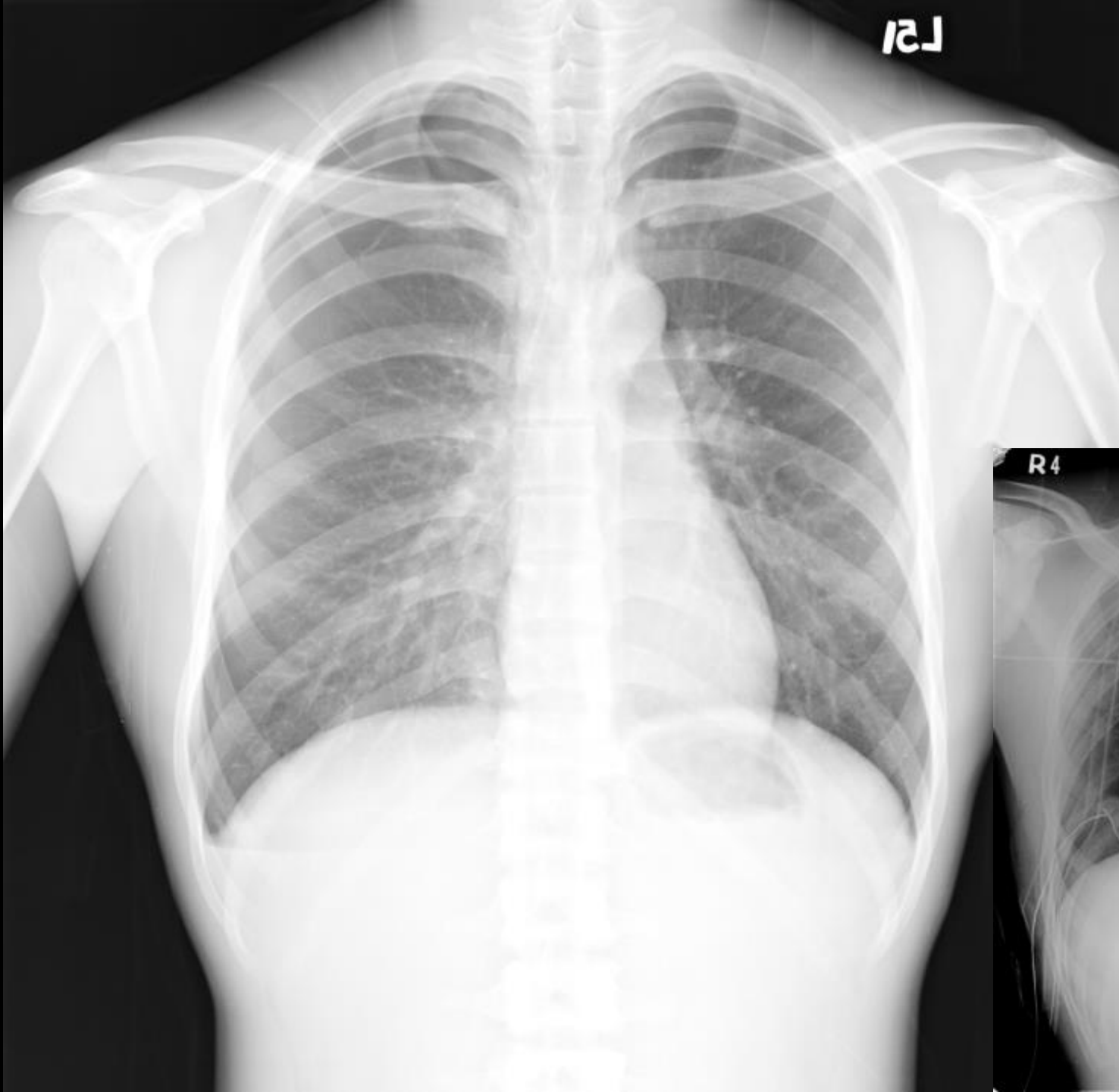


Pectus excavatum





Retrocardiac mass – Lung cancer



R't pneumothorax

