

# 增強CXR判讀能力的密技

臺北榮總 胸腔部

胡栢瑋


# 胸專CXR判讀考試分享

臺北榮總 胸腔部

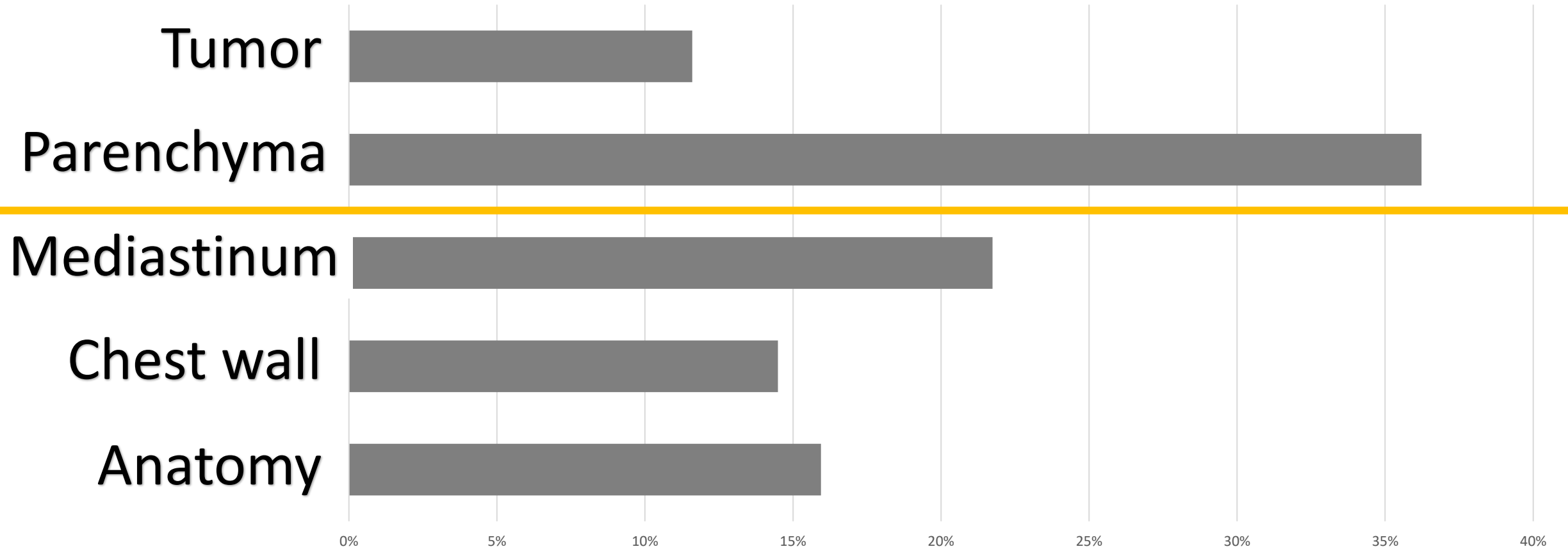
胡栢瑋

# 影像學考試概況

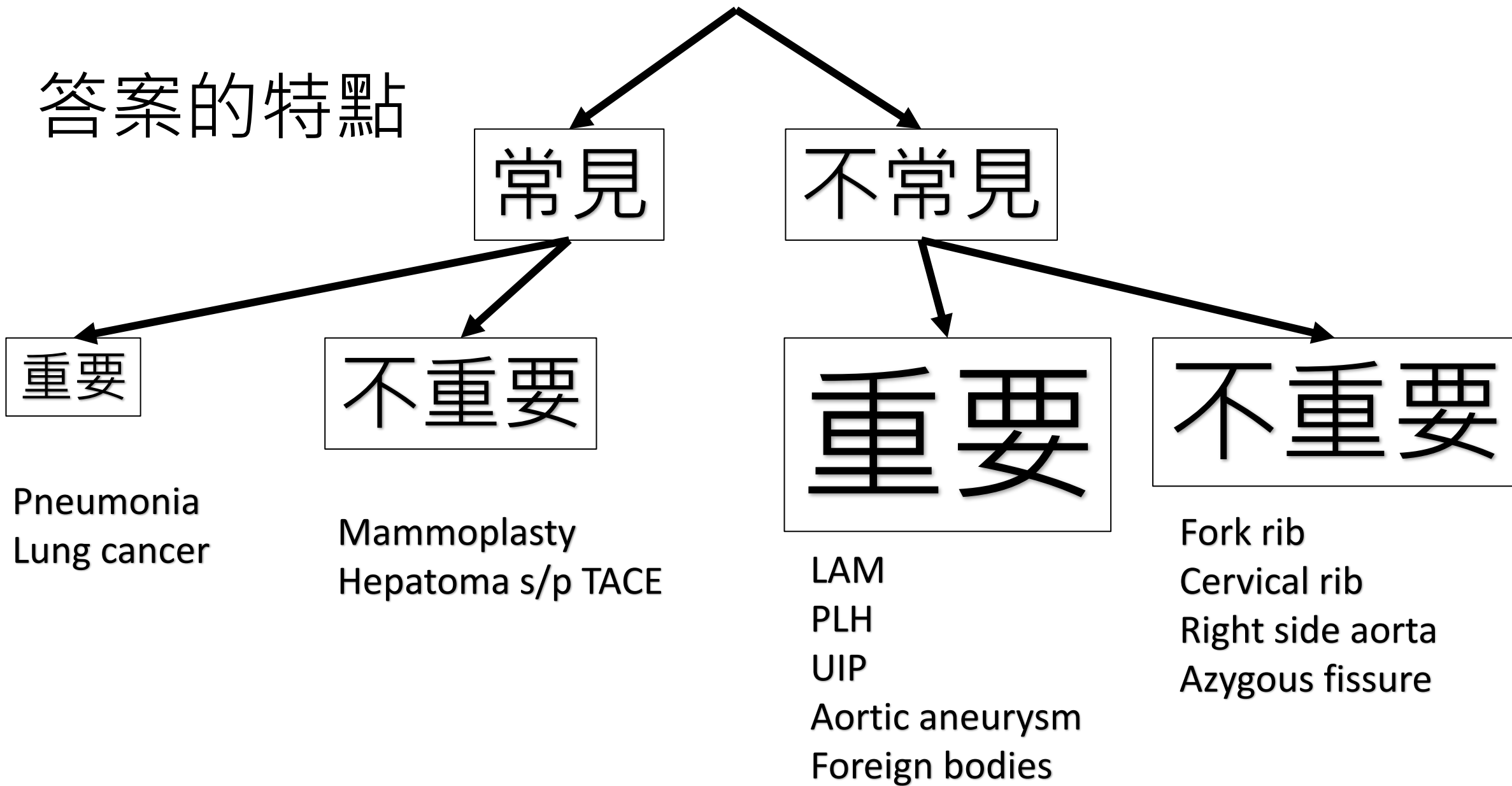
- 33題，100分鐘
- 電腦醫療影像系統
- 繪圖、描述、三個鑑別診斷



# 答案分類(近三年)



# 答案的特點



# 考什麼

- 考眼力
- 考鑑別診斷

找得出異常處(病灶)

說一個合理的故事

異常處的可能原因(鑑別診斷)

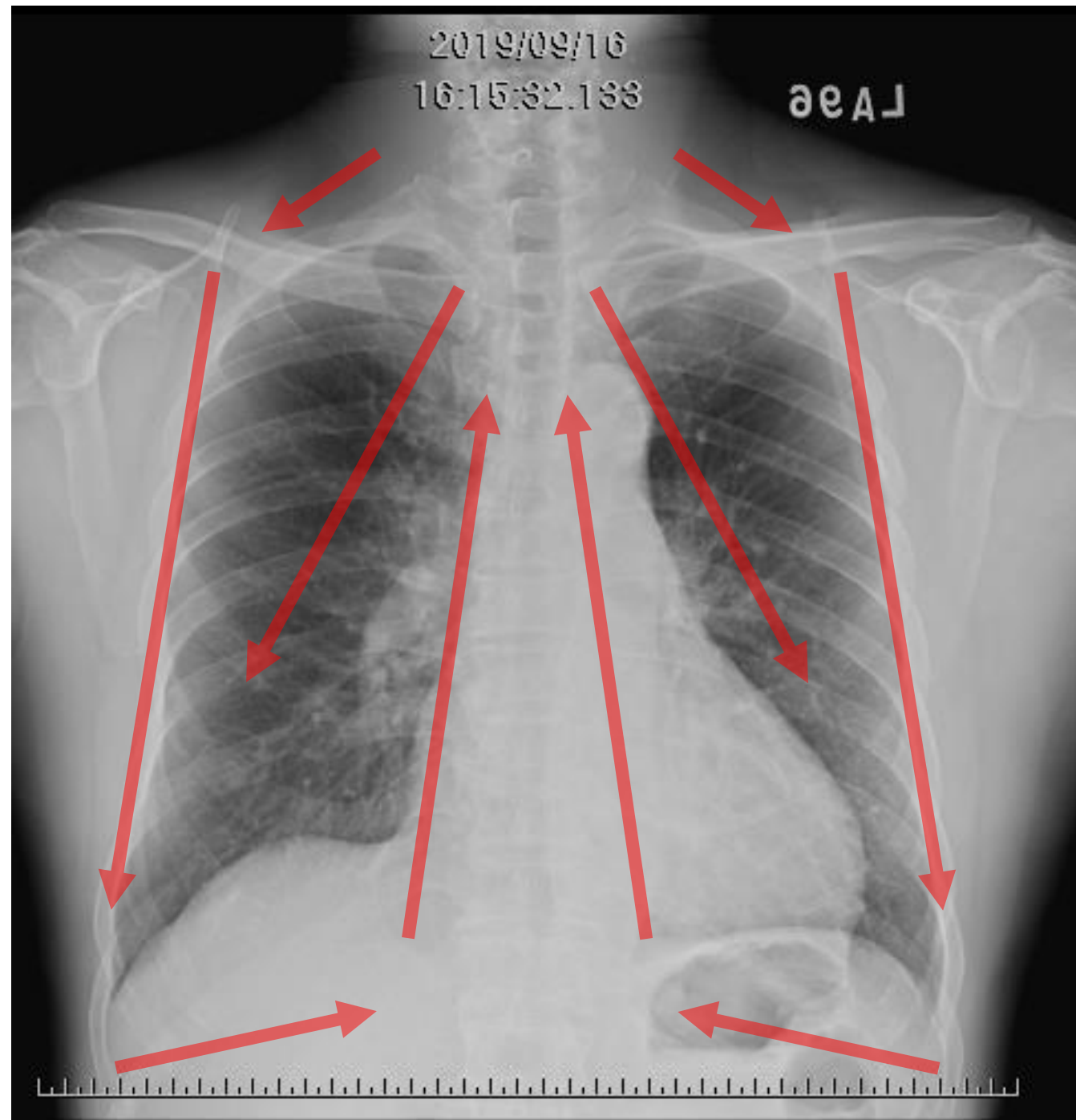
# 找得出異常處(病灶)

- 比較**舊片**
- 比較**對側**
- 比較**正常**CXR
- 系統性閱片，**避免遺漏**



# Systemic reading

- Establish your own methods
- Felson's: **T**here **A**re **M**any **L**ung **L**esions
  - Thorax and soft tissue
  - Abdomen
  - Mediastinum
  - Lung---unilateral
  - Lung---Bilateral
- 蛙式法

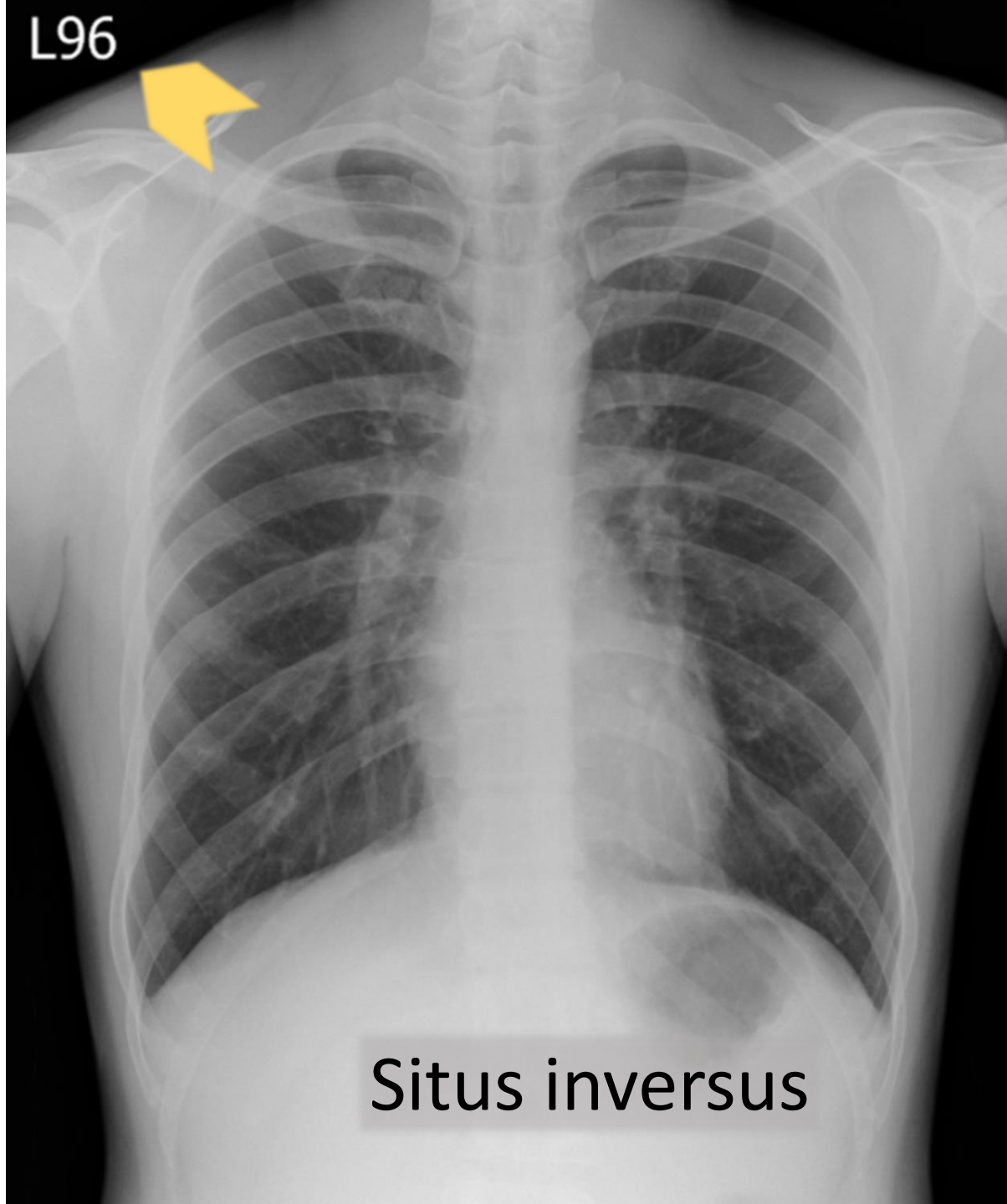


# Normal CXR?

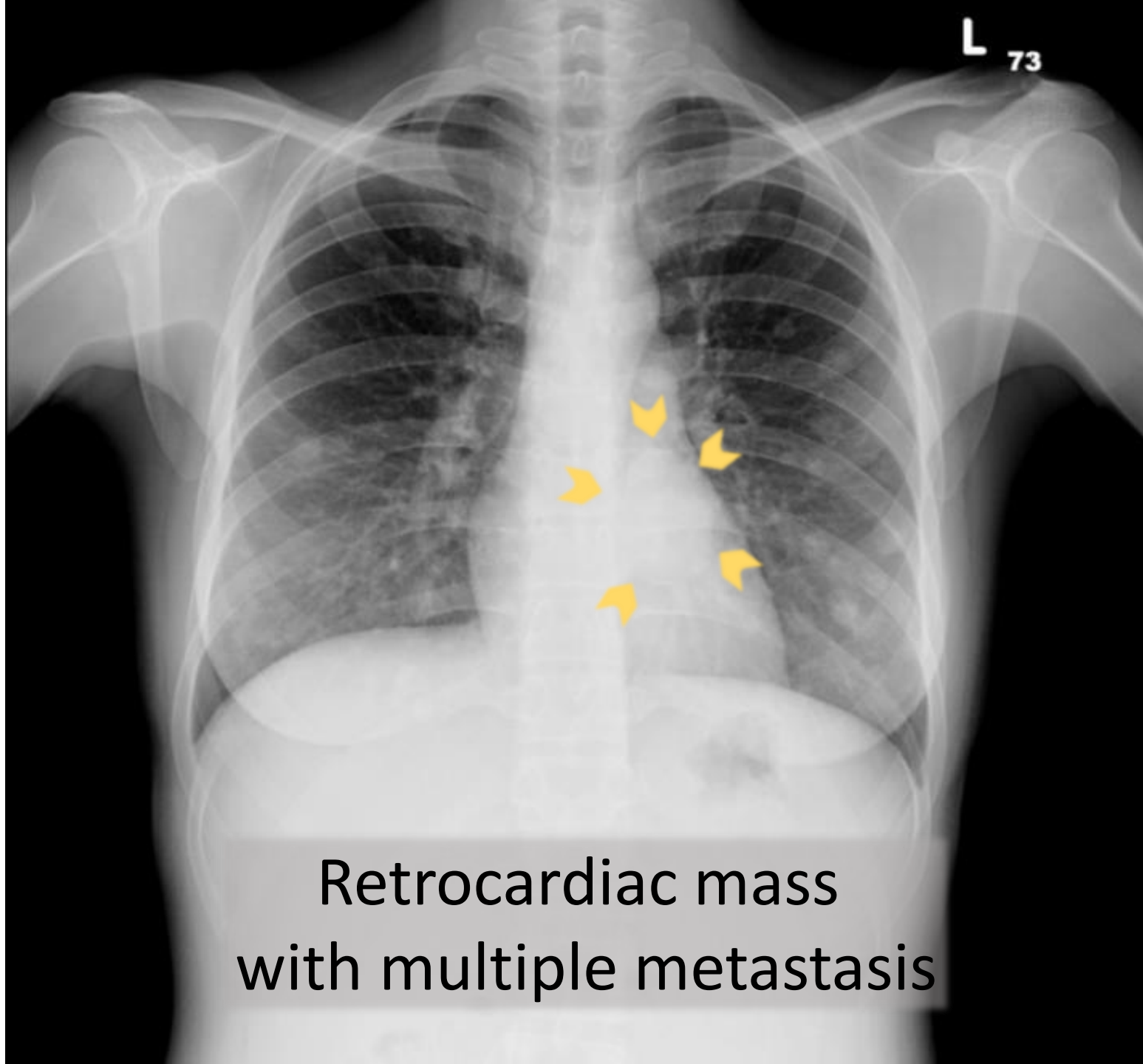
左右 MM A B C D E F

- 左右放反(situs inversus, right side aortic arch)
- Mastectomy, Mammoplasty
- Endotracheal lesion(Airway)
- Pneumothorax(Air)
- 死角(apex, retrocardiac, sub-diaphragm)
- Cervical rib, fork rib, ankylosing spondylitis(Bone)
- Esophagus, extrapulmonary soft tissue
- Foreign body: Artifact(nipple, braid), Malposition of medical devices

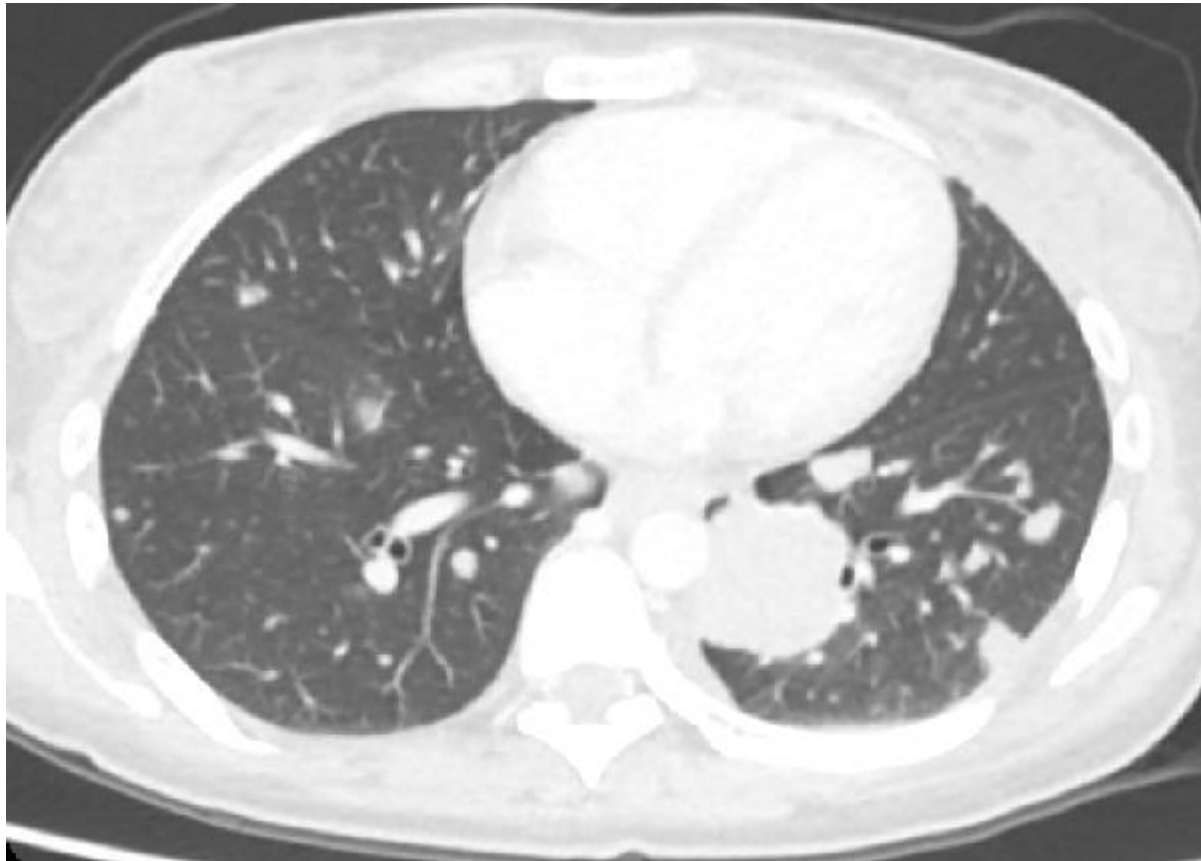
L96



Situs inversus

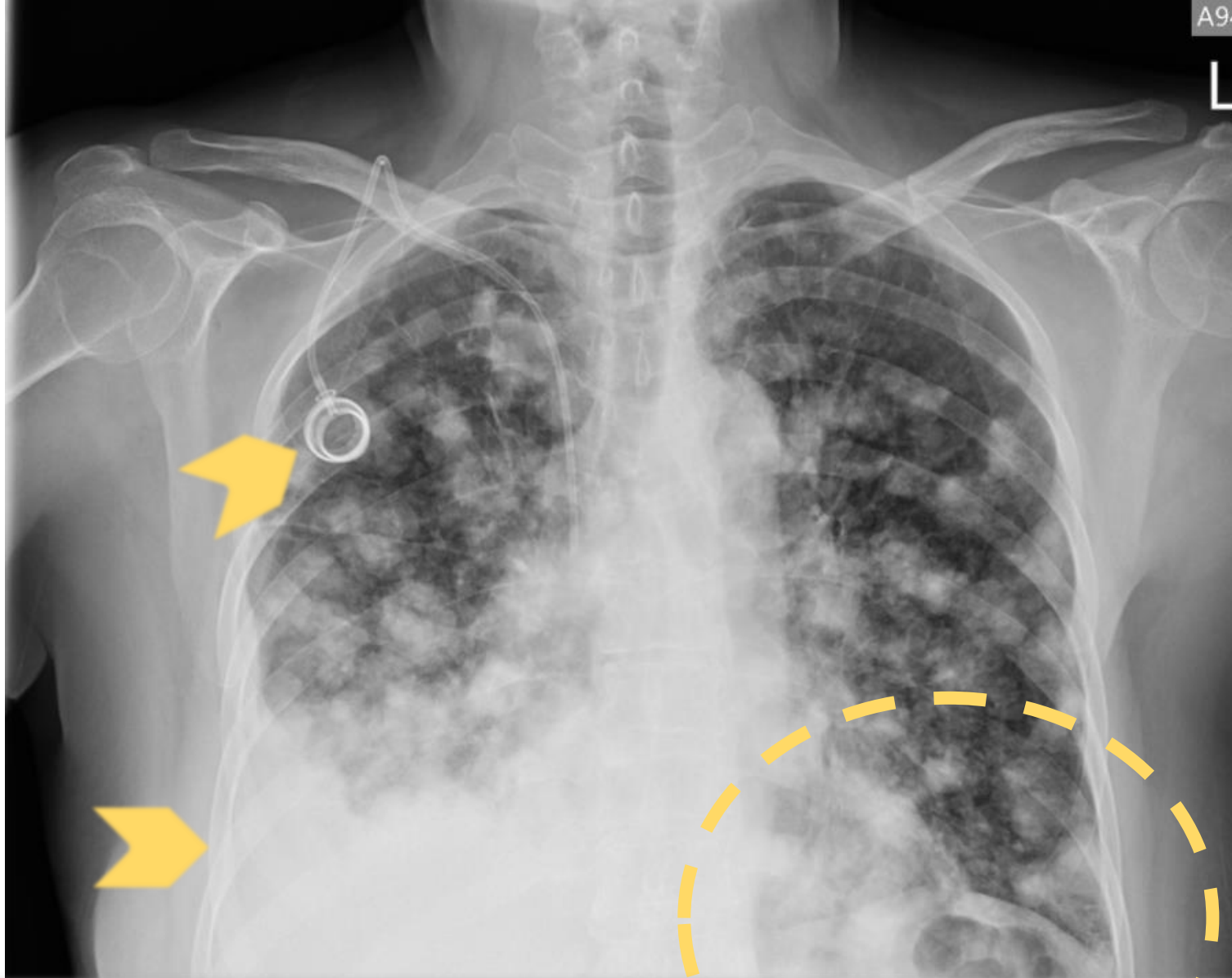


Retrocardiac mass  
with multiple metastasis



# 說一個合理的故事

- 配合臨床訊息: 年紀、性別、主訴、過去病史
- 發揮想像力



breast CA s/p mastectomy,  
with lung metastasis and pleural seeding, s/p chemotherapy

# 異常處的可能原因(鑑別診斷)

- HIIN
  - **H**emodynamics: vascular lesion, emboli, AVM, Simitar syndrome
  - **I**nfection: fungus, PJP, viral pneumonia
  - **I**nflammation: CTD-ILD, GPA
  - **N**eoplasm: lymphangitic carcinomatosis
- 職業 遺傳(先天) 全身 肉芽腫 其他



# EX. Pulmonary nodules

- H: AVM
- I: septic emboli, TB, cryptococcus, healed varicella pneumonia
- I: GPA, rheumatoid nodule, DPB
- N: metastatic carcinomatosis
- 職業: pneumoconiosis
- 肉芽腫: stage III sarcoidosis

# EX. Lesions around diaphragmatic level

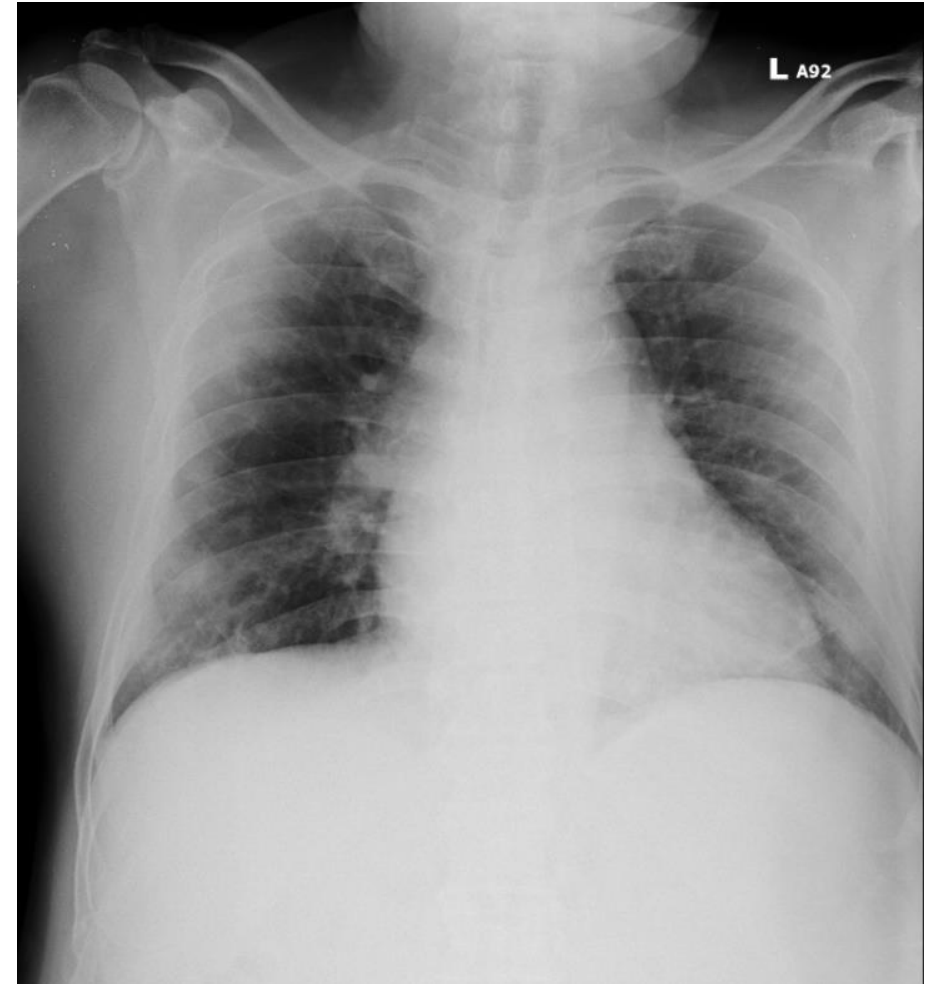
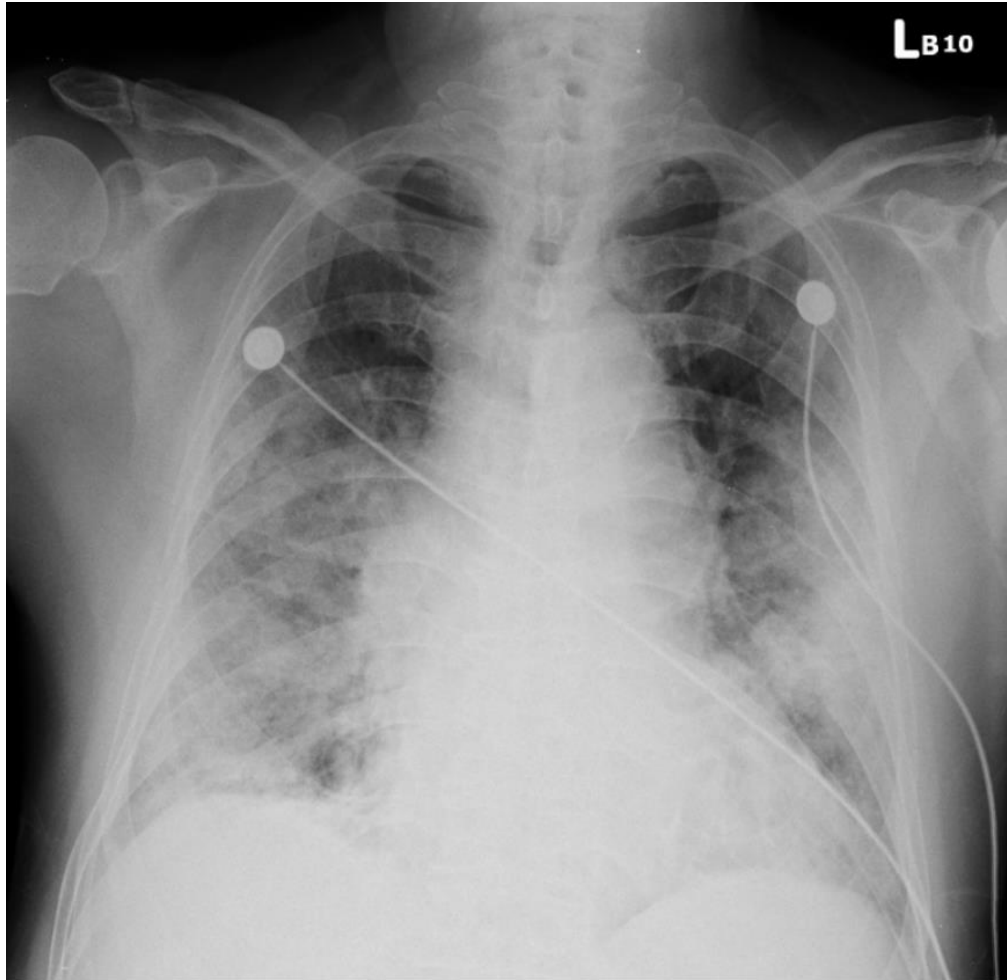
- H: extramedullary medullary hematopoiesis, esophageal varices
- I: TB spine
- N: esophageal cancer, esophageal reconstruction, lung cancer, neurogenic tumor
- 遺傳(先天): sequestration, bronchogenic cyst, CCAM
- 其他: achalasia

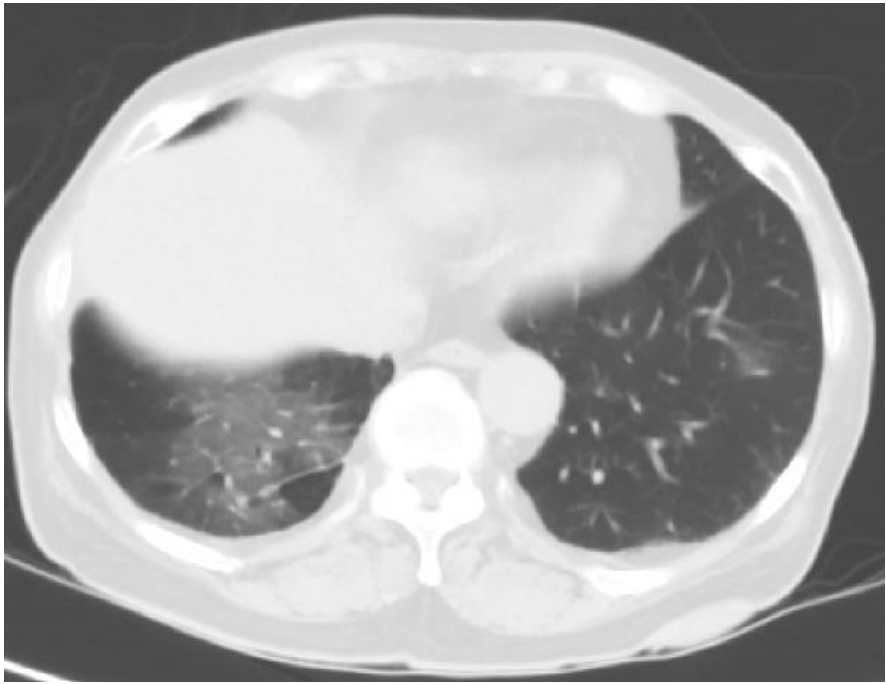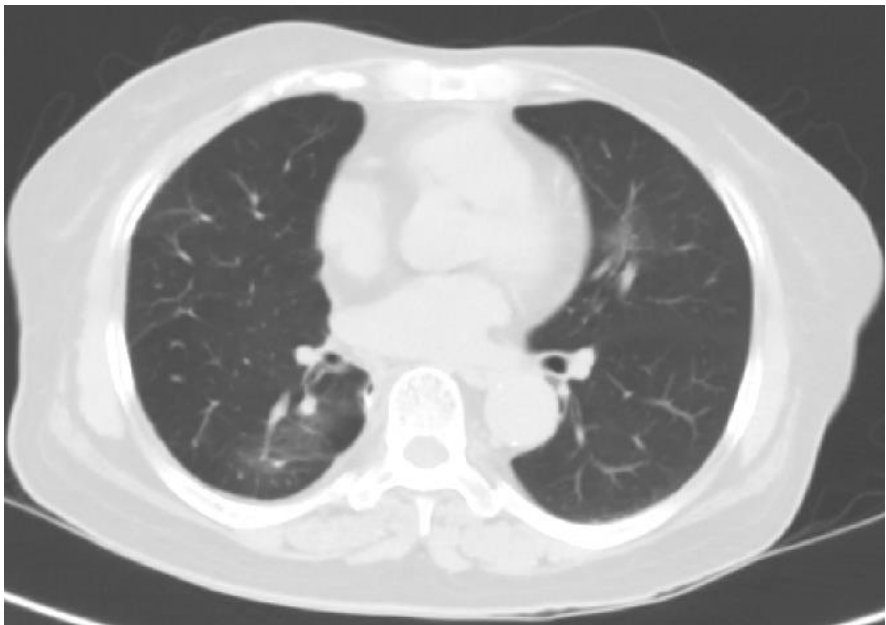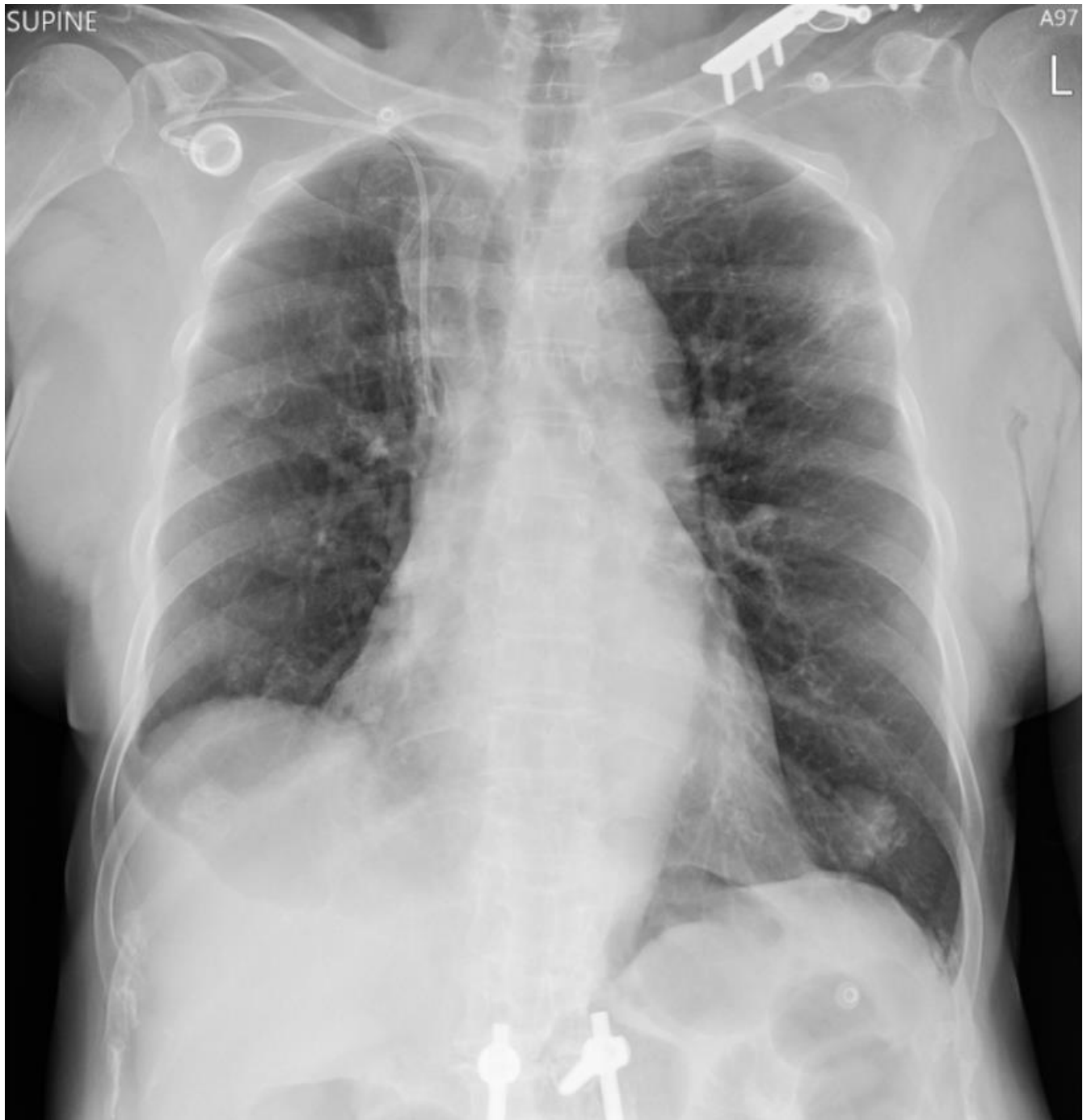# 剩下半個月要準備什麼、怎麼準備

- 歷年景福館CXR考題 (vs 醫院院內題庫)
- 與伙伴一起練習
- 對考題與答案的直覺
- 增強自己的弱點(血管、食道)
  
- Pitfalls: 雙拼、三拼
- **COVID-19 images**

# COVID-19

Peripheral, bilateral and lower lung zone opacity





# 祝考試順利

胡栢瑋

[peterhu824@gmail.com](mailto:peterhu824@gmail.com)