

第一批完成 第二劑疫苗的人員

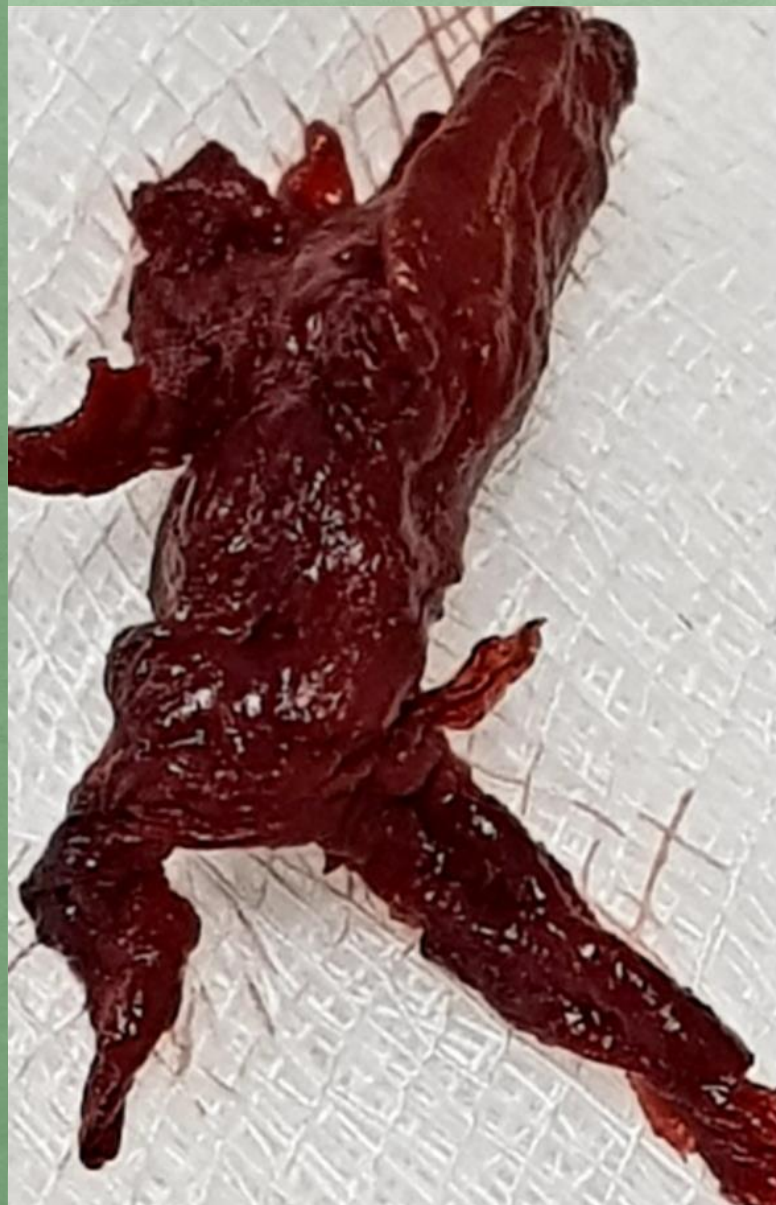距離
不只產生美感
還有安全感

COVID-19 疫苗接種紀錄卡 COVID-19 Vaccination Record

中文姓名 陳忠蔚 英文姓名(同護照) Chung Wei First Name Chen

疫苗種類/劑次 Vaccine/ Dose	廠牌/品名 Manufacturer/ Product name	接種日期 Date vaccine given yyyy / mm / dd	醫師或接種者簽名 Signature of healthcare professional	接種單位章戳 Official stamp of administration
COVID-19疫苗第1劑 COVID-19 1 st dose	<u>AZ</u>	<u>2021 / 3 / 22</u>	<u>陳嘉珊</u> 96404 M0534374	<u>亞東紀念醫院</u> 113101001 門診章
第2劑預約日期 Appointment date for 2 nd dose <u>2021 / 5 / 17</u>				
COVID-19疫苗第2劑 COVID-19 2 nd dose	AstraZeneca	<u>17 MAY, 2021</u>	<u>亞東醫師R</u> <u>陳嘉珊</u> 96404 M0534374	亞東紀念醫院 Far Eastern Memorial Hospital
		/ /		
		/ /		

急重症與外科術後影像判讀



本次內容

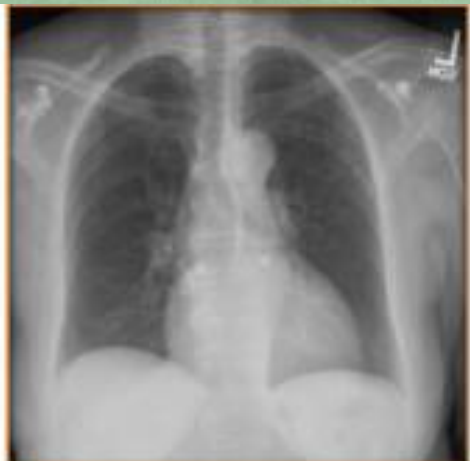未來AI會更厲害

不是每個ICU man都是胸腔科，至少要會看管路位置

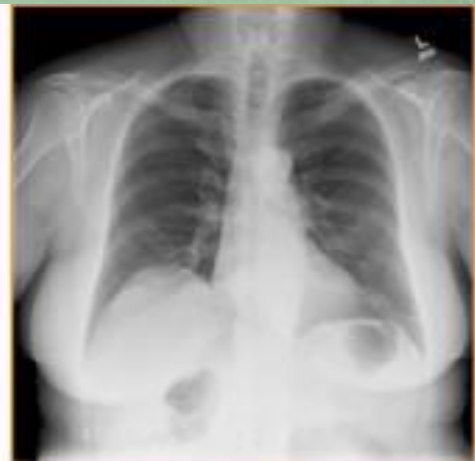FEMH 經驗

Ultrasonography in the ICU

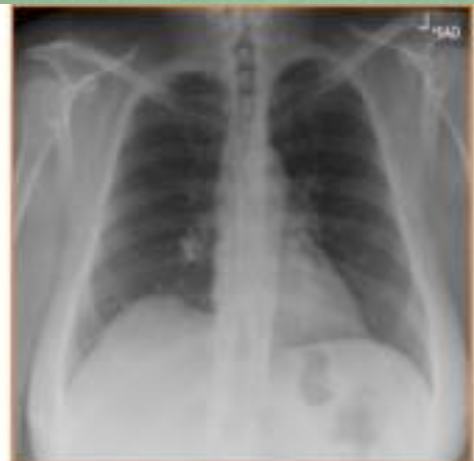input image



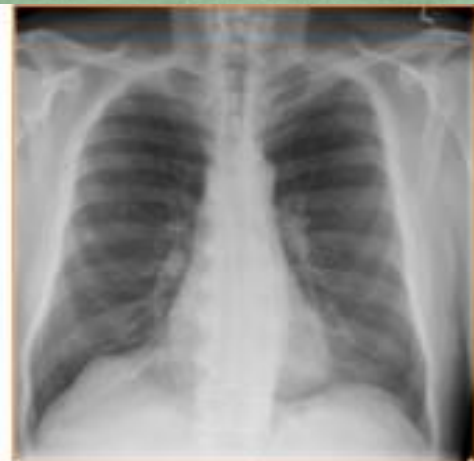aorta_thoracic / tortuous / mild
aorta_thoracic / tortuous



opacity / lung / middle_lobe / right / aorta_thoracic / tortuous
opacity / lung / base / left

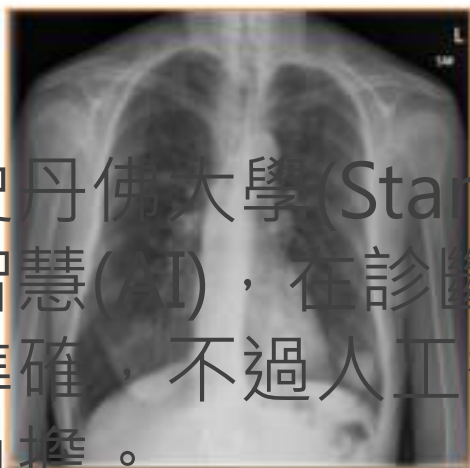


calcified_granuloma / lung / middle_lobe / right / multiple
calcified_granuloma / lung / hilum / right

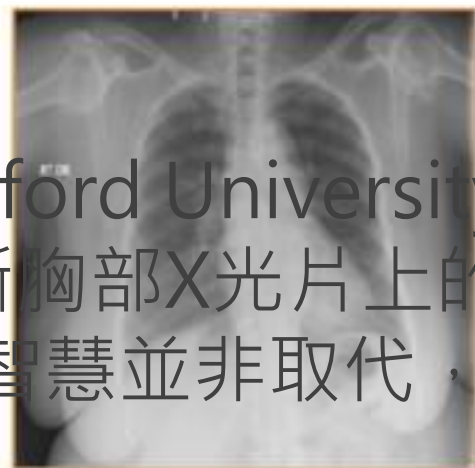

opacity / lung / middle_lobe / right / blood_vessels
calcified_granuloma / lung / middle_lobe / right

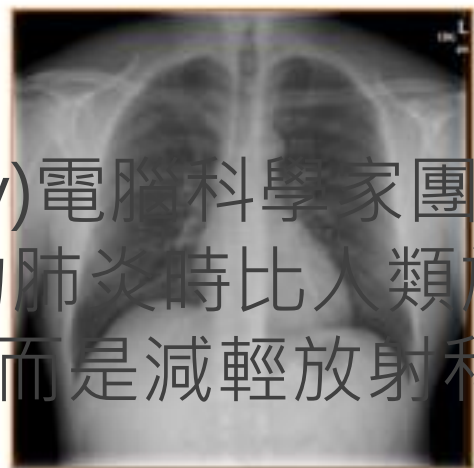
generated annotation



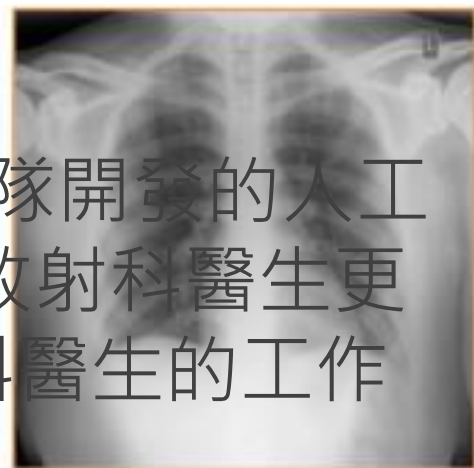
airspace_disease / lung / hilum / right / lung / hilum
nodule / lung / hilum / right



thoracic_vertebrae_degenerative / mild
aorta_tortuous / thoracic_vertebrae_degenerative / mild



normal
normal



normal
normal

true annotation

史丹佛大學(Stanford University)電腦科學家團隊開發的人工智慧(AI)，在診斷胸部X光片上的肺炎時比人類放射科醫生更準確，不過人工智慧並非取代，而是減輕放射科醫生的工作負擔。

中醫大附設醫院首創AI胸部X光輔助判讀系統，一秒快速判讀 (打報告? 還差很大啦!)

2019-06-04

圖一

- 病人性別：男性
- 病人年齡：68歲

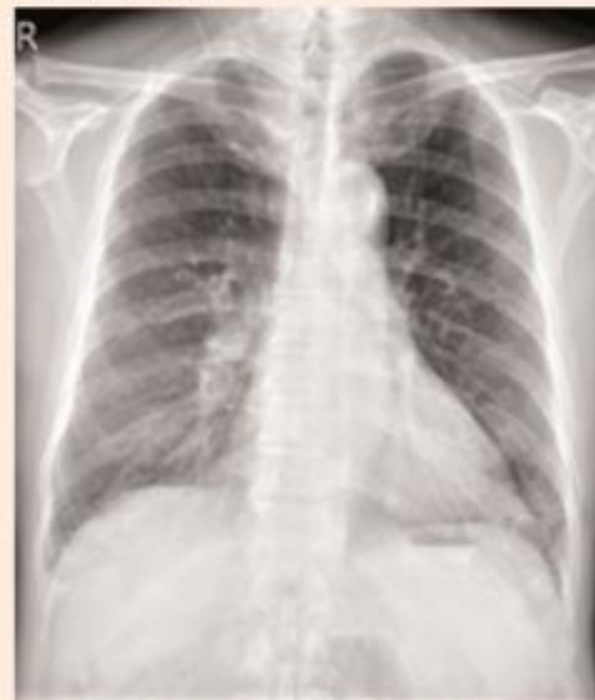放射科醫師診斷：

Tortuous aorta.
Peribronchial shadows increased.
Degenerative change of spine.
Bowel gas increased.
Overinflation of both lungs.
Interstitial shadows over both lungs.

胸腔科醫師判讀看法：

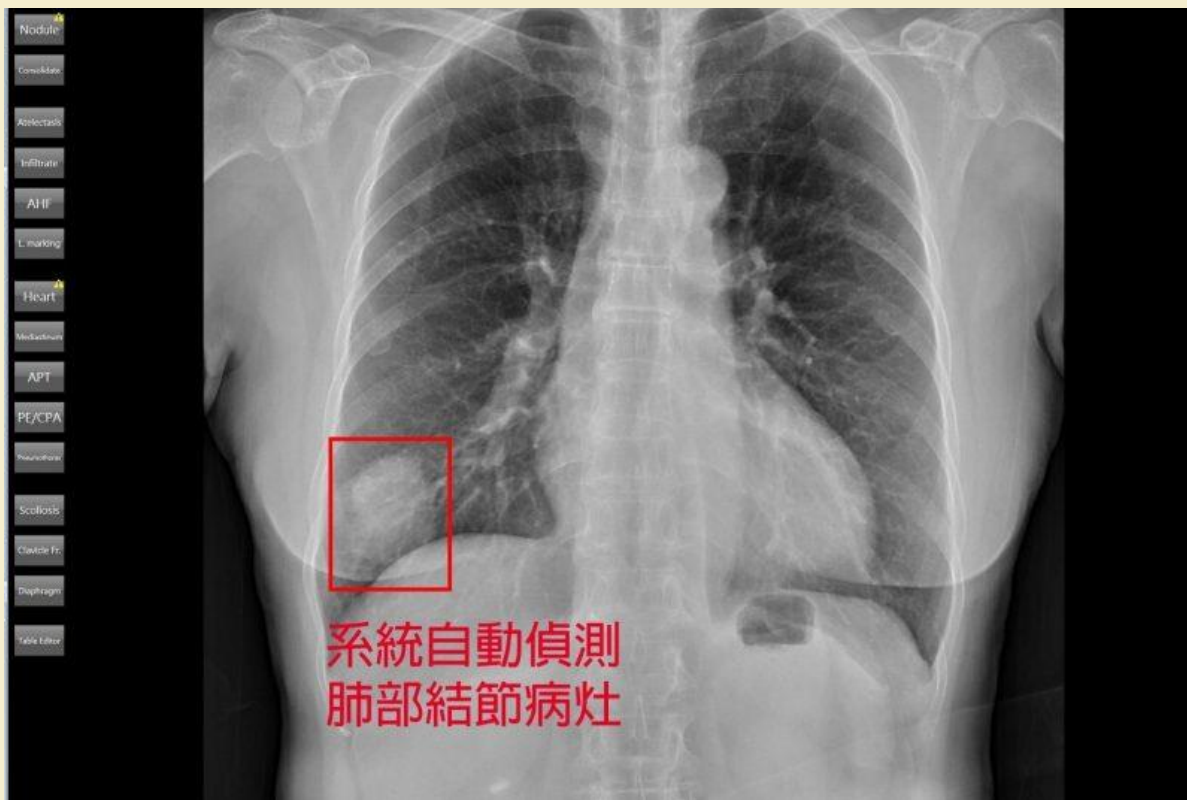
胸腔科醫師徐武輝副院長表示，以這張胸部X光來說一般醫師在判讀上會有比較大的挑戰性，但如果是由專業的胸腔科醫師來看可以兩側下肺葉有一些間質性侵潤情形，而從人工智慧（AI）的判斷結果也顯示異常，同時有高達0.893的信心水準，相當的不錯。

AI預測結果：
異常：0.893



大幅提升判讀率、準確度！亞東醫院智慧胸腔X光AI系統榮獲2020年醫策會「國家醫療品質獎」金獎

- 人工智慧實驗室主持人郭冠宏表示，這是亞東醫院影像醫學科與廣達電腦三年來攜手並進，凝聚醫療與科技頂尖技術的結晶。
- 具備「緊急疾病快篩」和「自動輔助報告」兩大功能，
- 針對四種臨床上重要且緊急的疾病，做有效且即時的快篩影像分類。這四類重大疾病包含：新發現氣胸（Fresh pneumothorax）、氣管內管放置過深（Endotracheal tube malposition）、新發現肺部腫瘤（Fresh lung tumor），以及氣腹（Pneumoperitoneum）

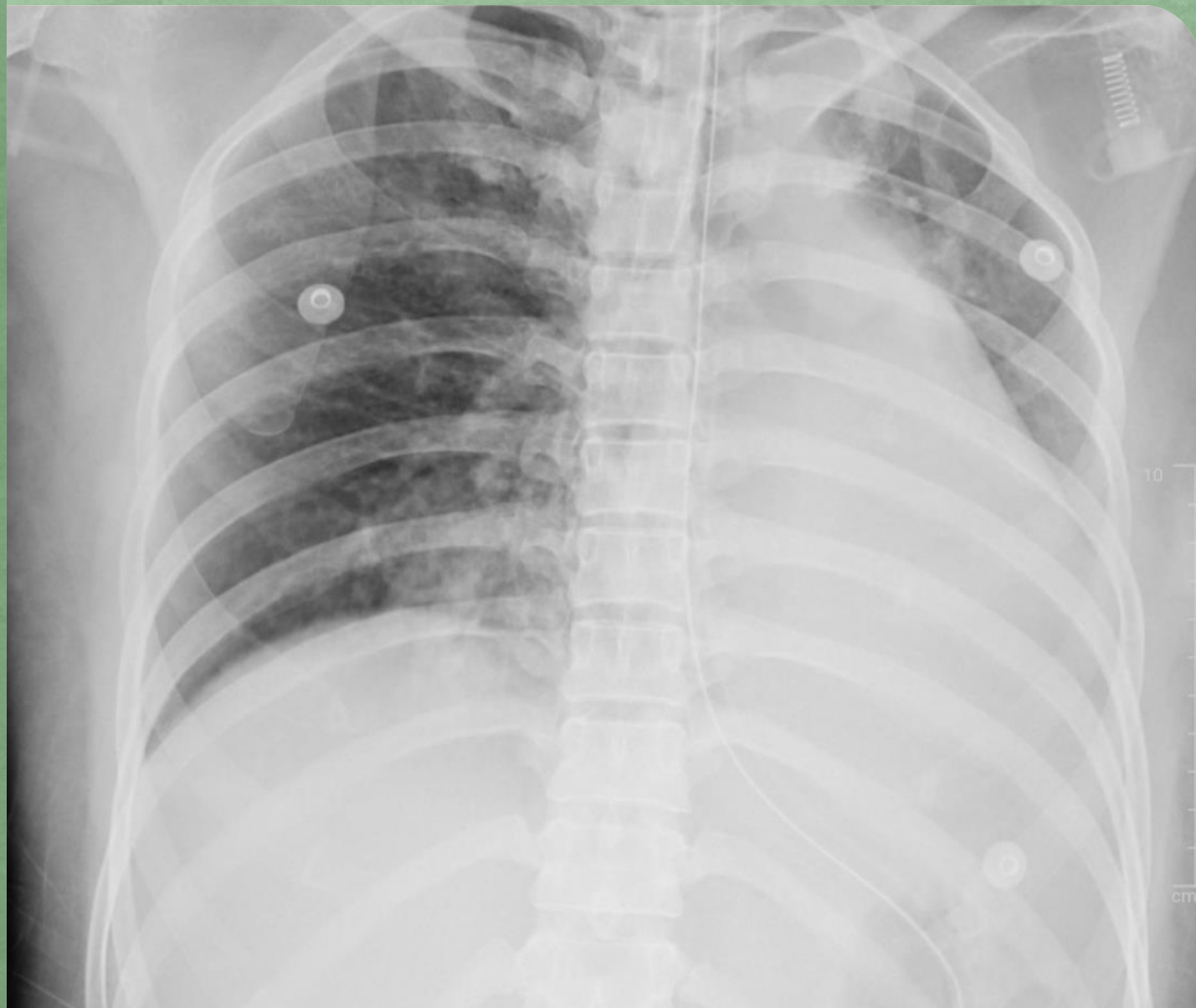


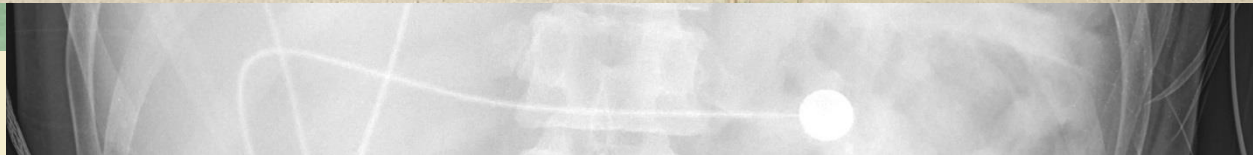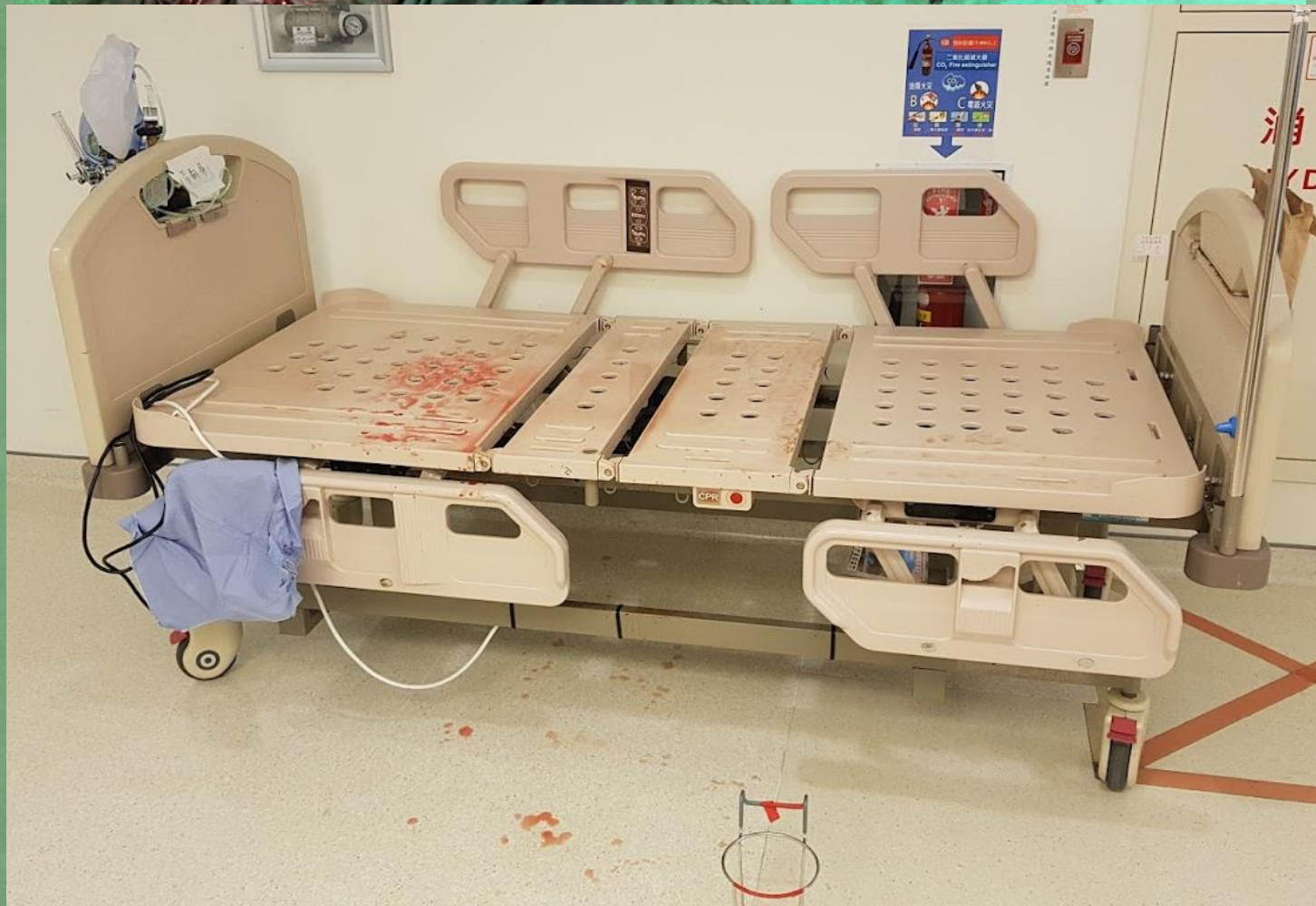
但是...
光和影組成
的可能和你
想的不一樣



目前.....
靠自己比較快

只是Portable
X ray什麼時候
才來

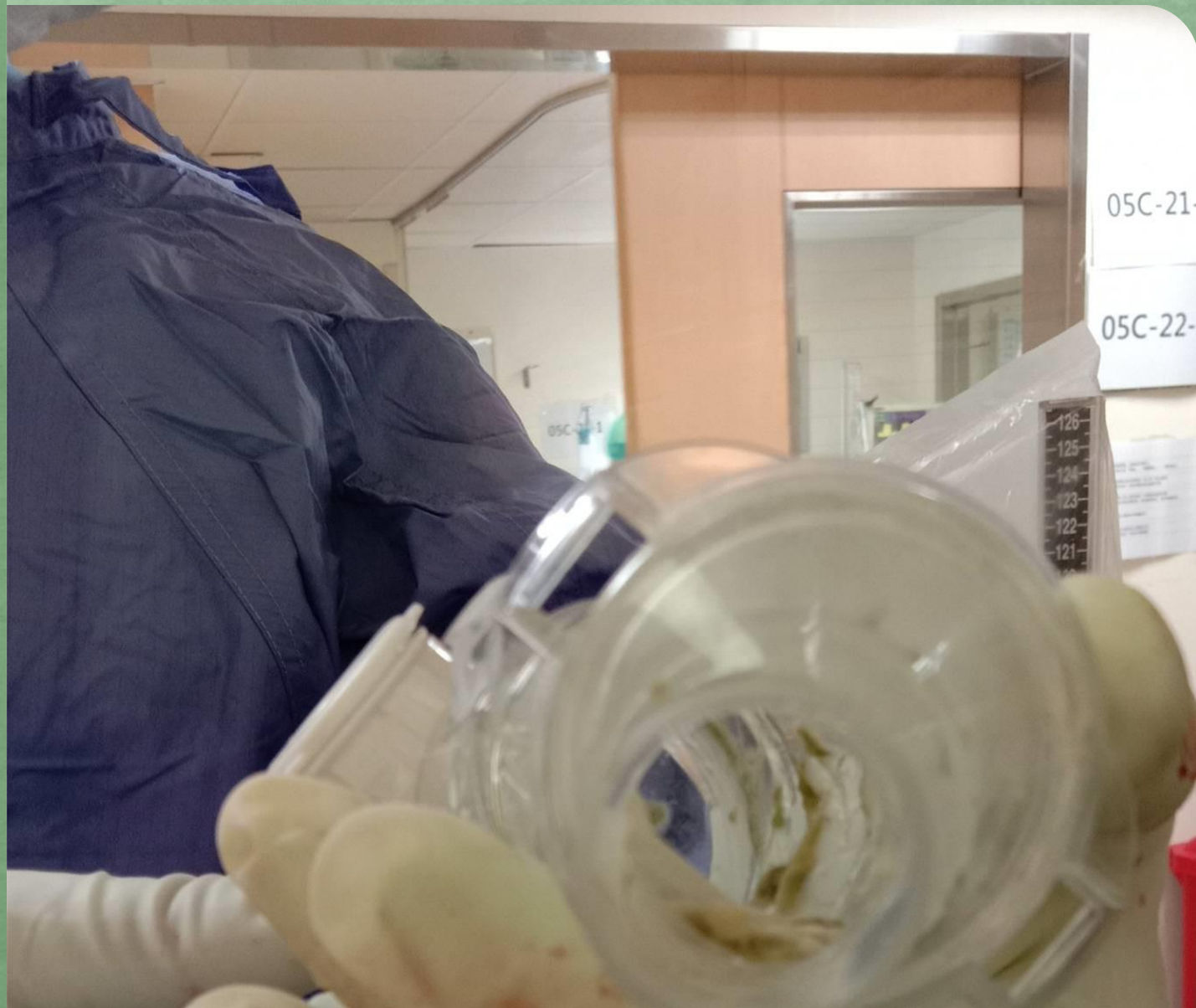


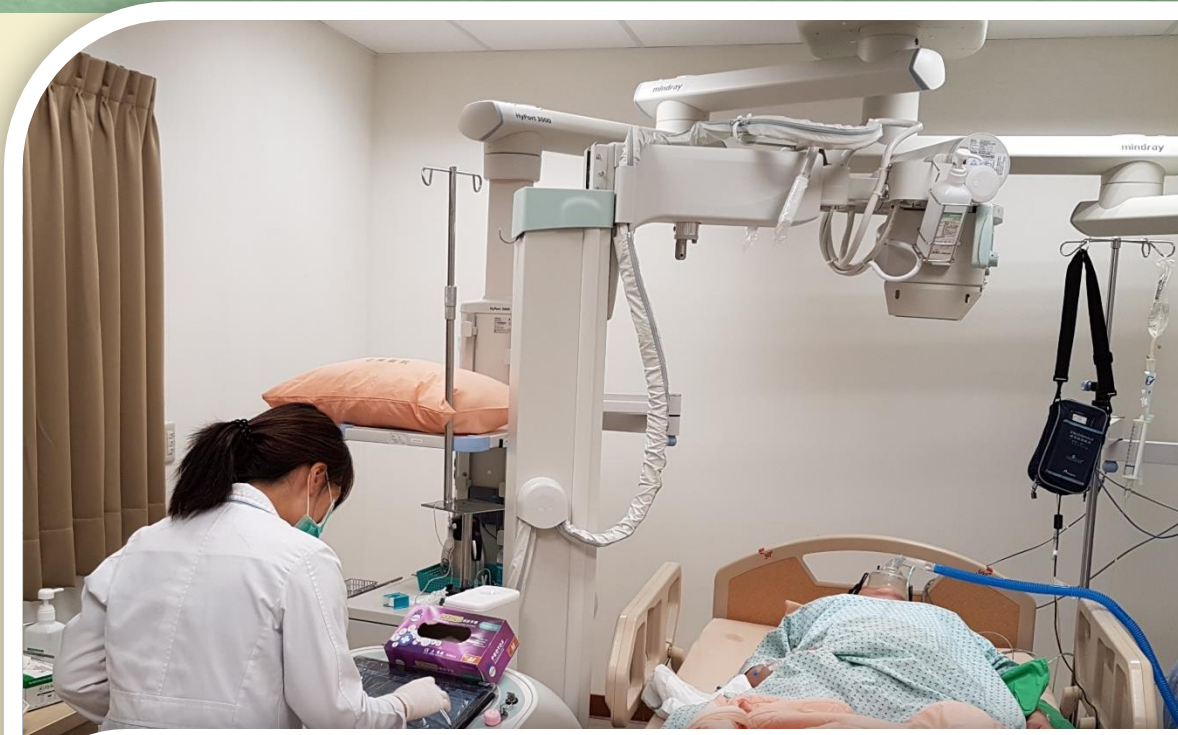
X光只是臨床醫學的一部分

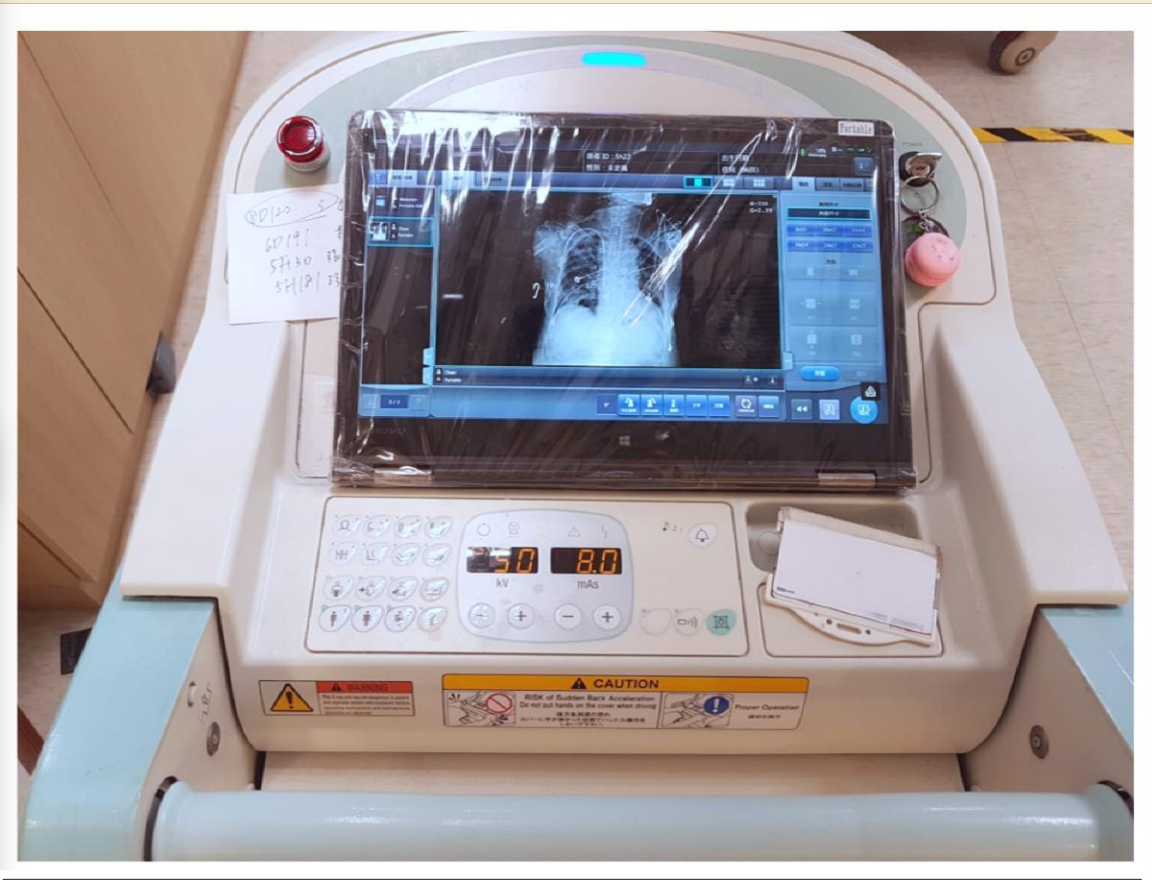用看的就知道要輸血，不用等Hb

有時候，問題不在病人身上

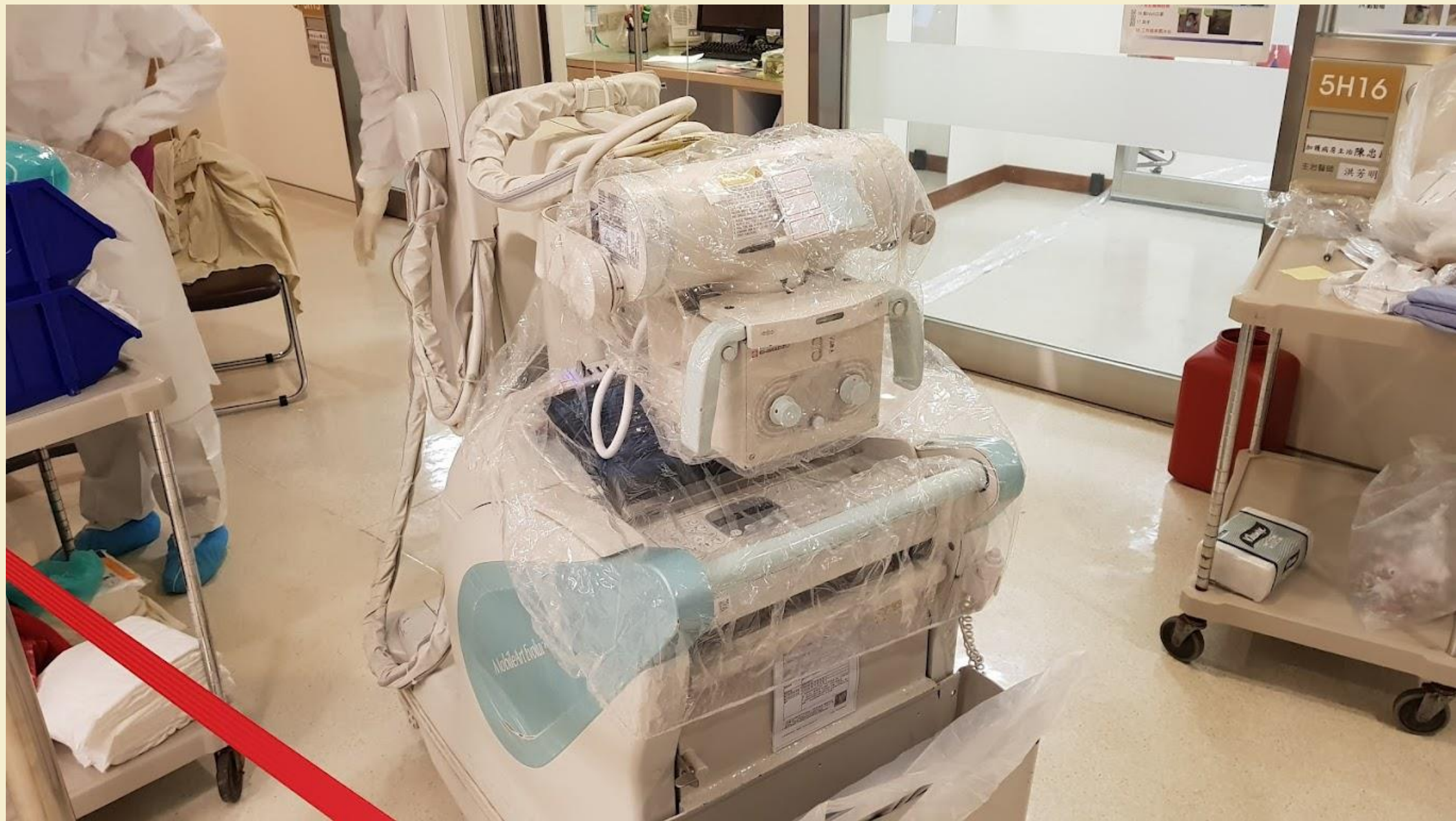

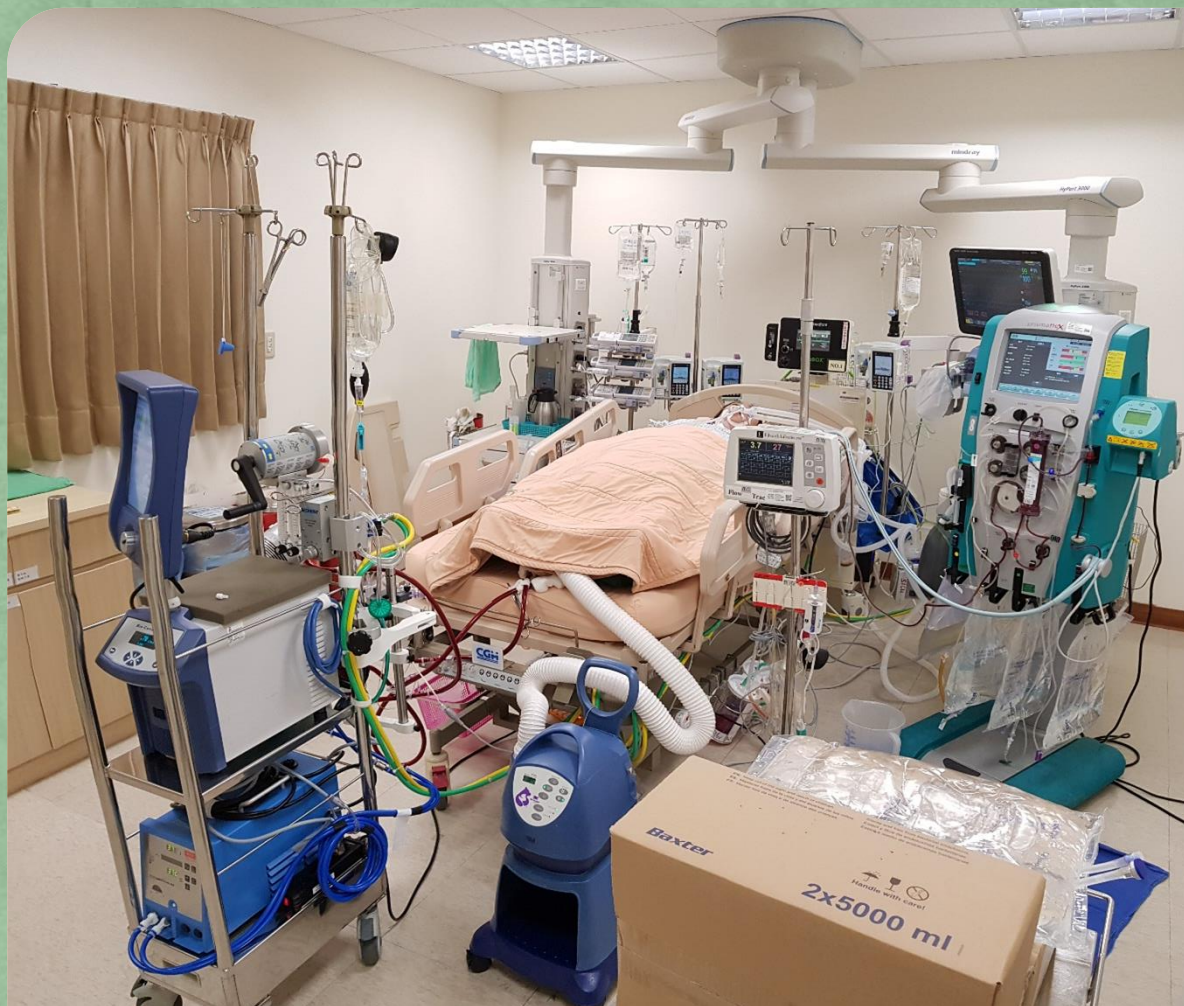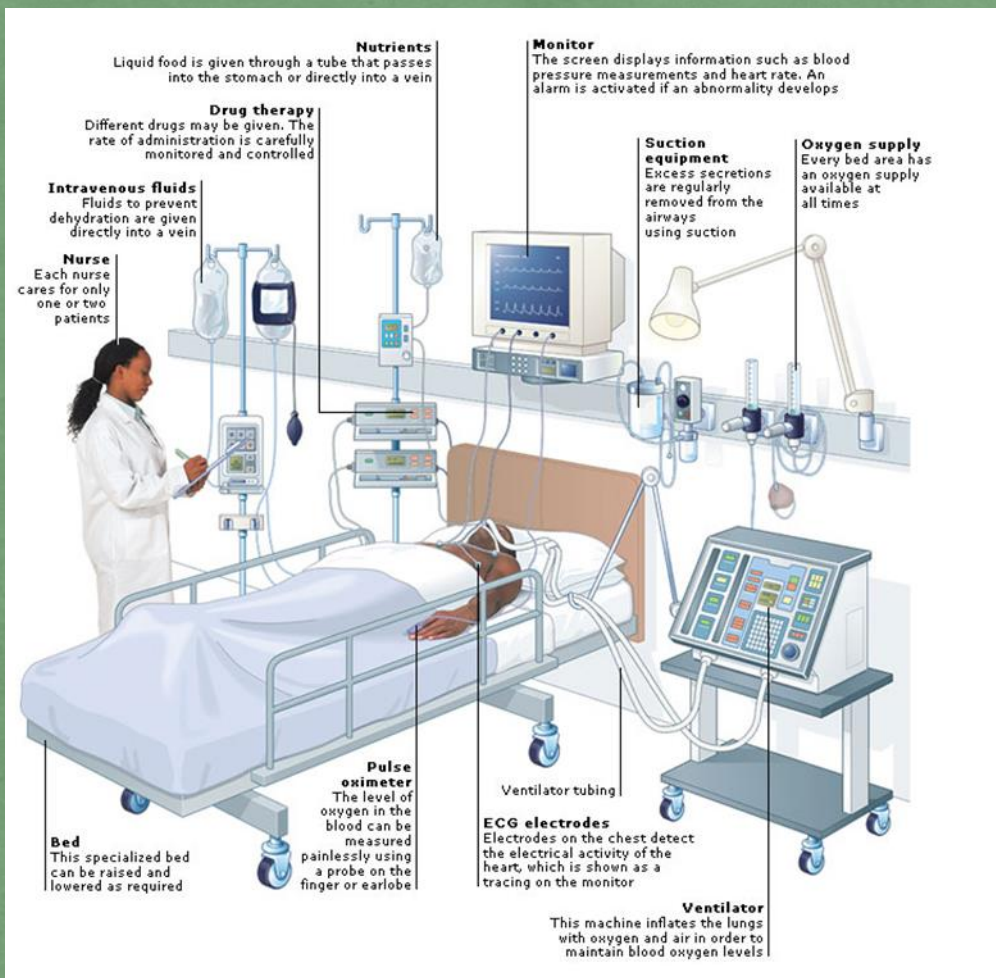


很多個0
" 000000000000 " 



0與1的故事

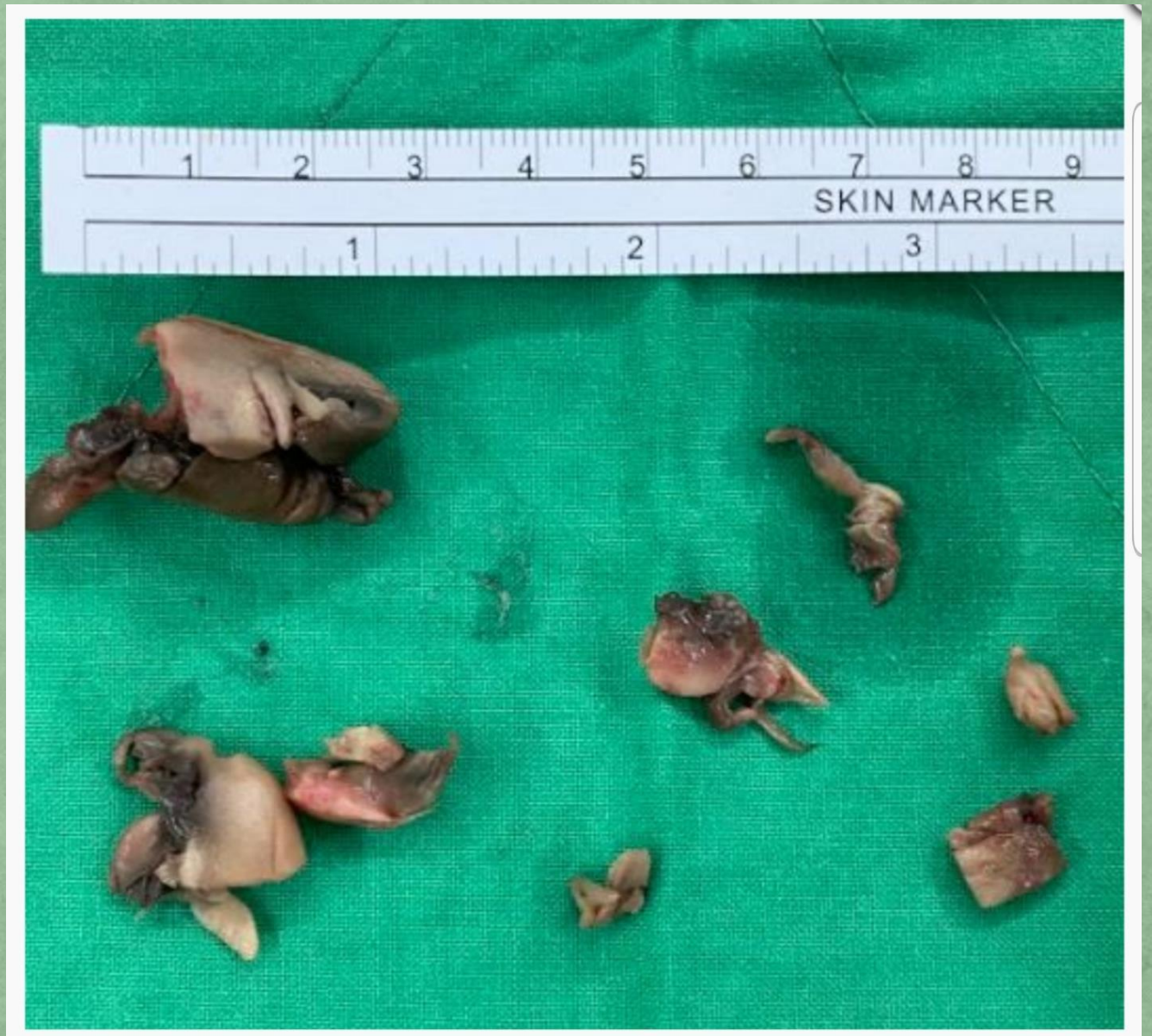



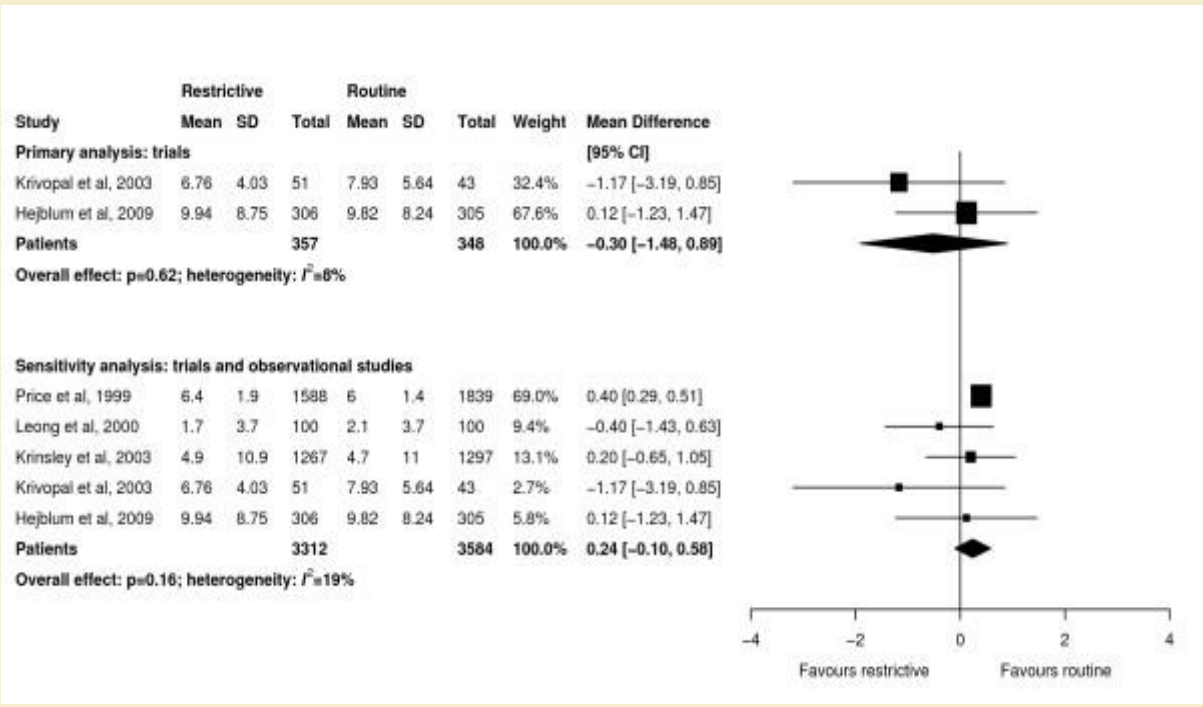
你以為是這樣

看到是這樣

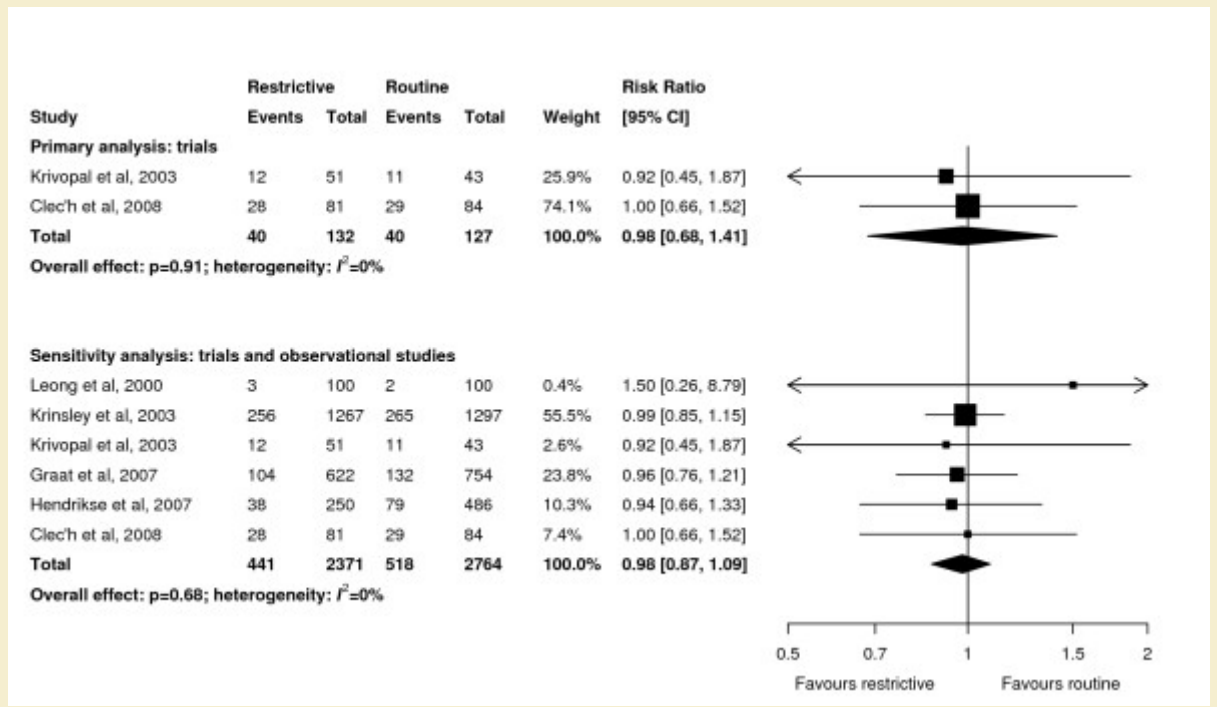
Obstructive
shock
OHCA s/p
CPCR with
ROSC



Routine chest x-rays in intensive care units: a systematic review and meta-analysis



duration of mechanical ventilation (WMD -0.30 days, 95% CI -1.48 to 0.89 days, P = 0.62; three trials, N = 705)



hospital mortality (RR 0.98, 95% CI 0.68 to 1.41, P = 0.91; two trials, N = 259)

X光需要天天照嗎？

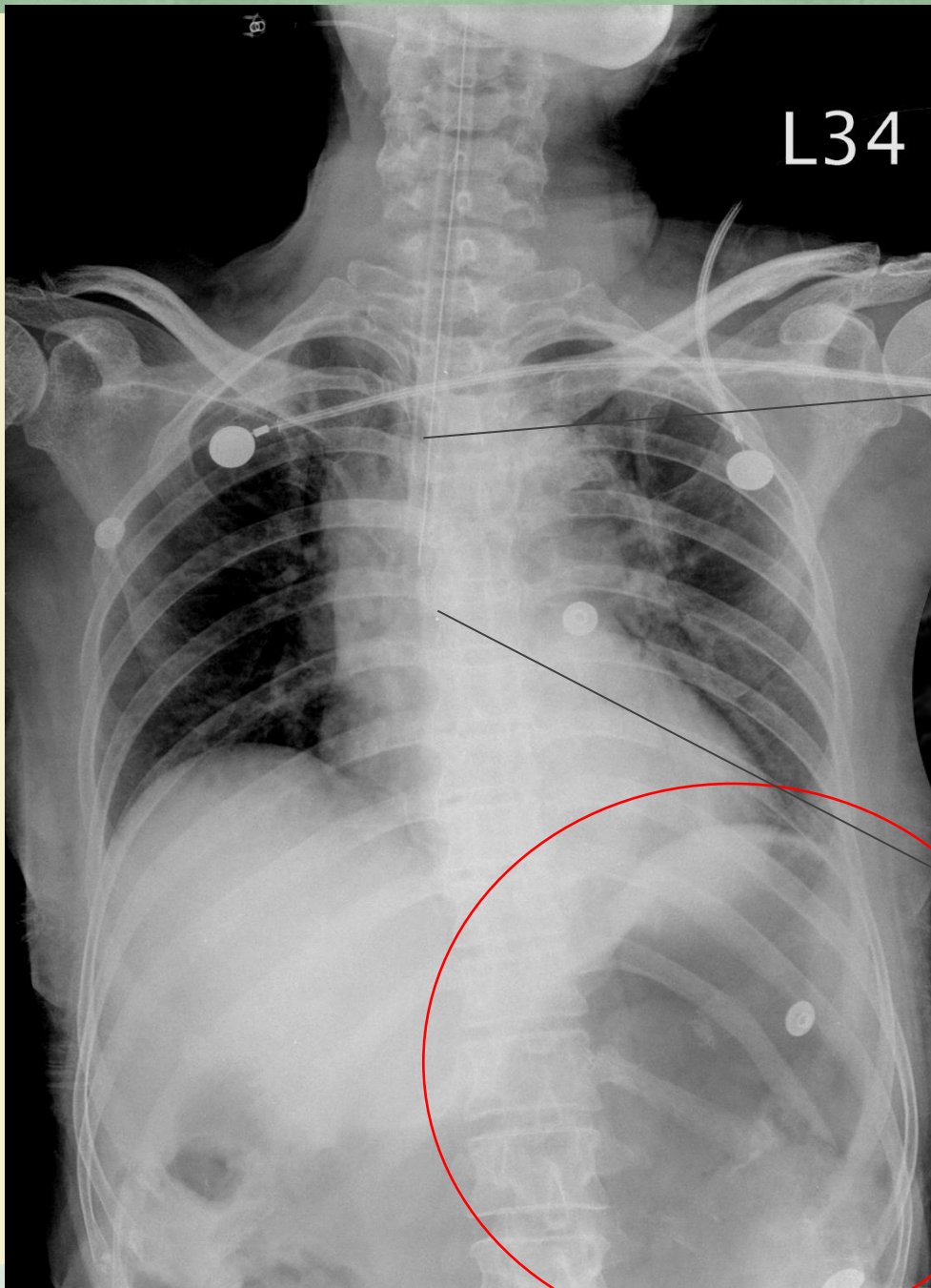
其實，這是個假
議題

ARDS or acute lung edema progress
Traumatic pneumothorax
Invasive procedure

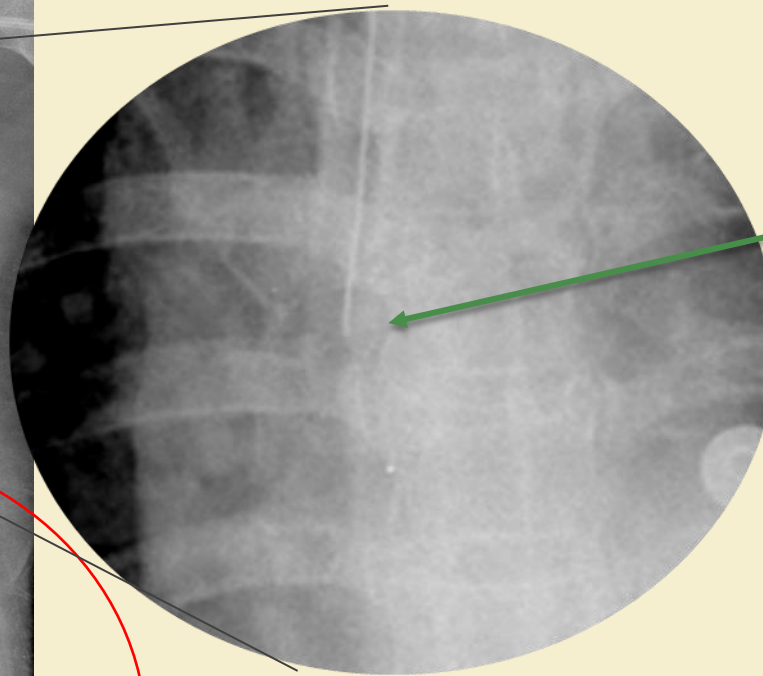


不是每個ICU man都是胸腔科，至少要會看管路位置

- ETT: 3-5 cm from above the carina
- CVC(PICC, Port-A catheter, CVP, Perm cath, Hickman cath): right tracheobronchial angle and carina
- NG: 10~15 cm below diaphragm, Except esophagectomy patient
- Chest tube: in thoracic cavity, at least
- IABP catheter: 2 cm inferior to the aortic arch
- ECMO: Too close of VV ECMO
- Swan-Ganz catheter: rare used



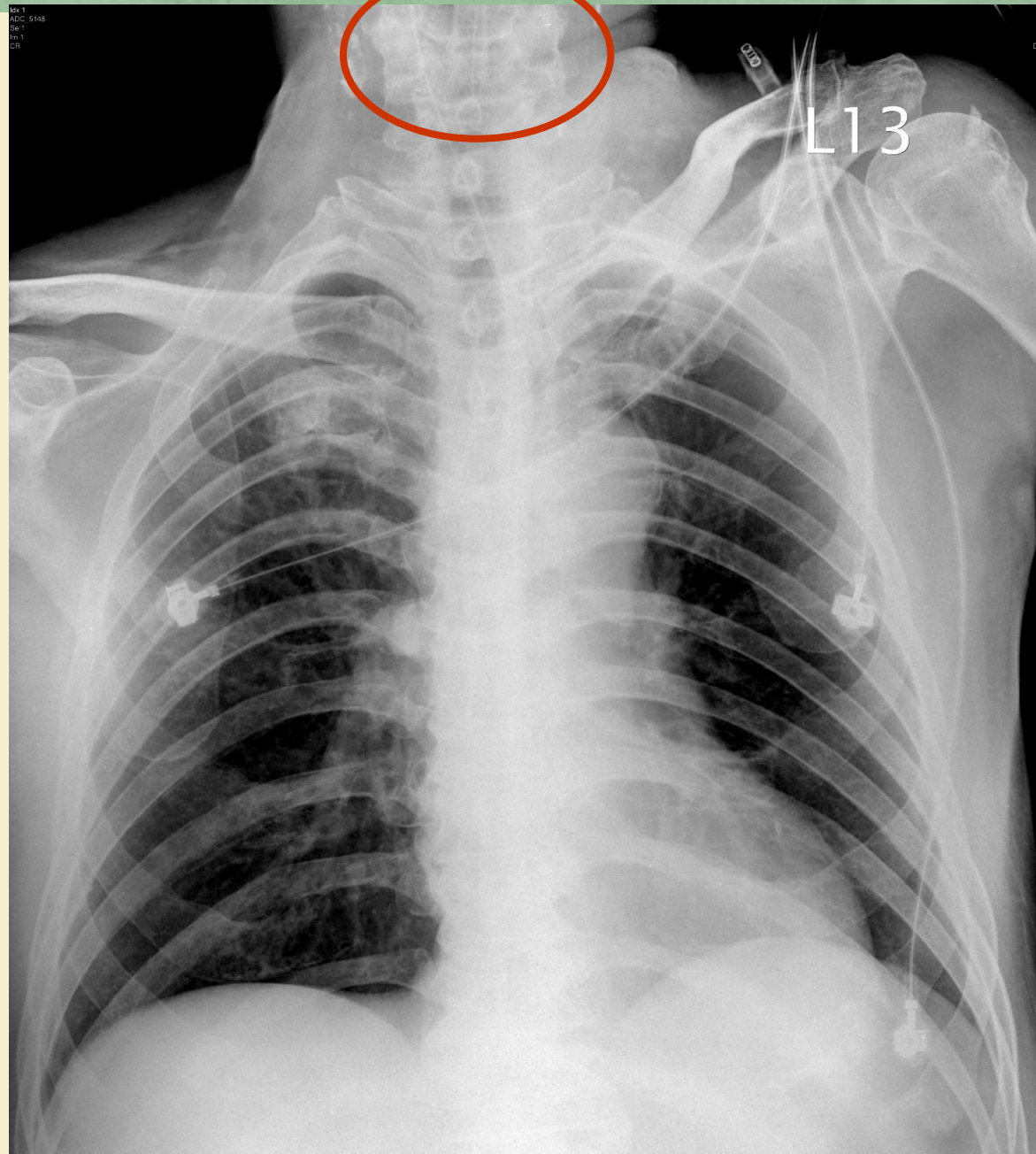
過與不及 Part 1



- 過程看起來很慘烈

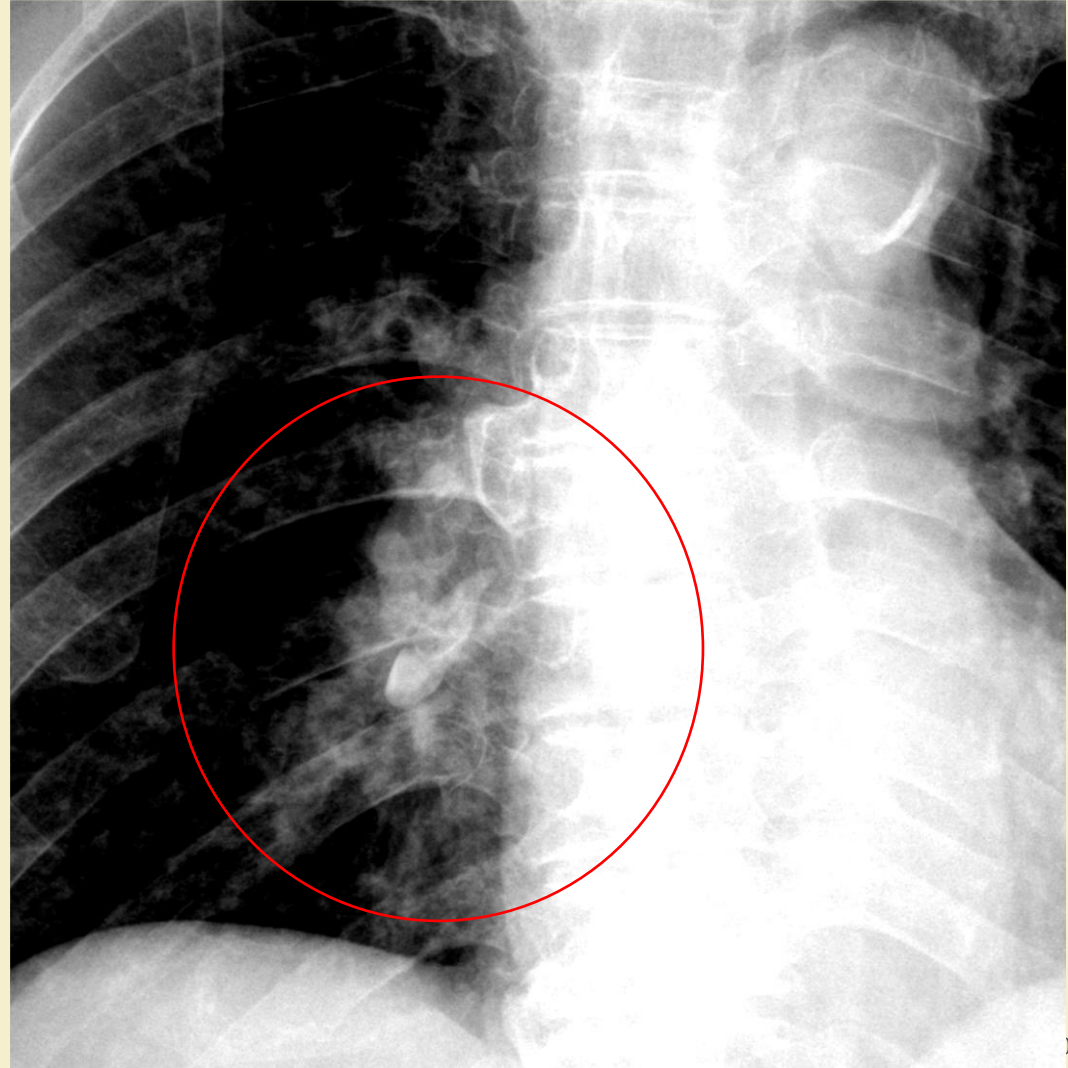
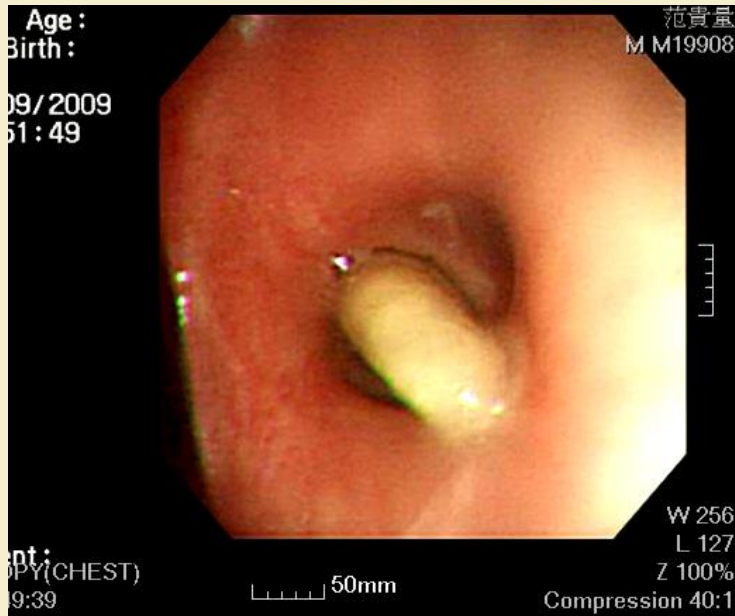
過與不及 Part 2

- 有插管?
沒插管?
- 下一步不是“意外”拔管成功
- 就是推急救車

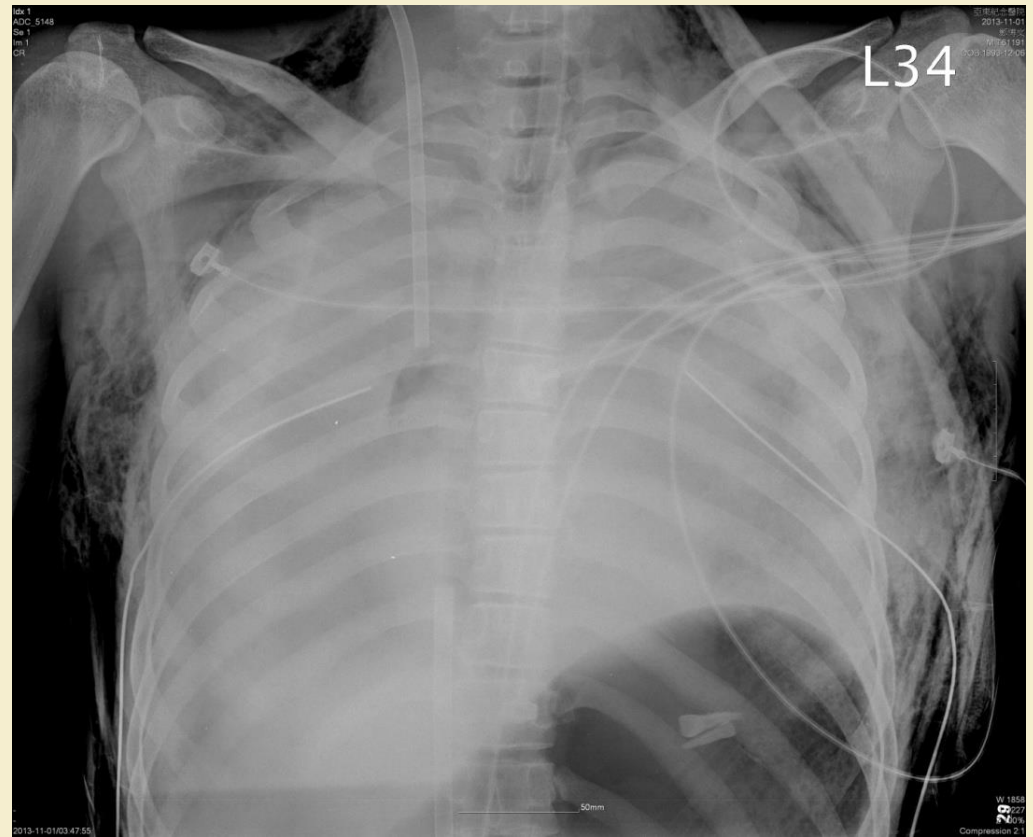
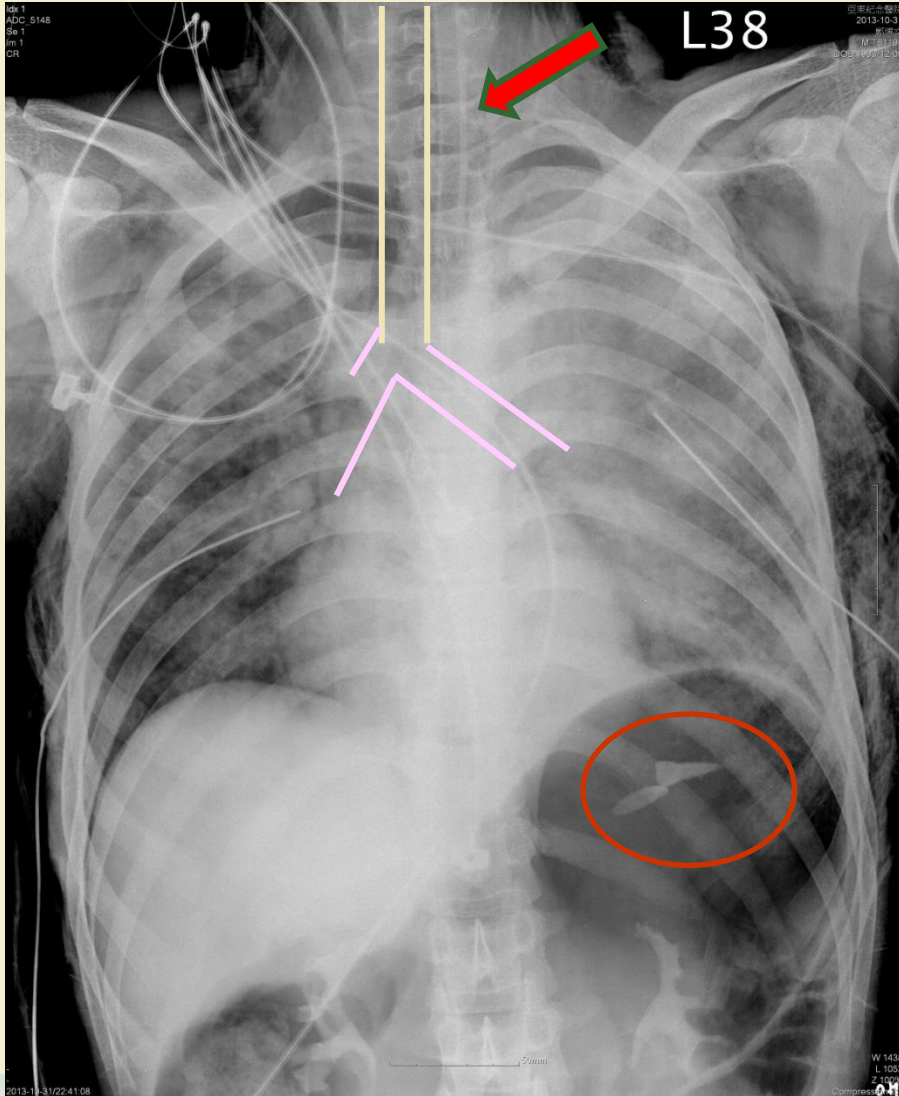


掉進去就撿起來唄

- In RLL bronchus



你發現了什麼？只是胃好脹？牙齒？

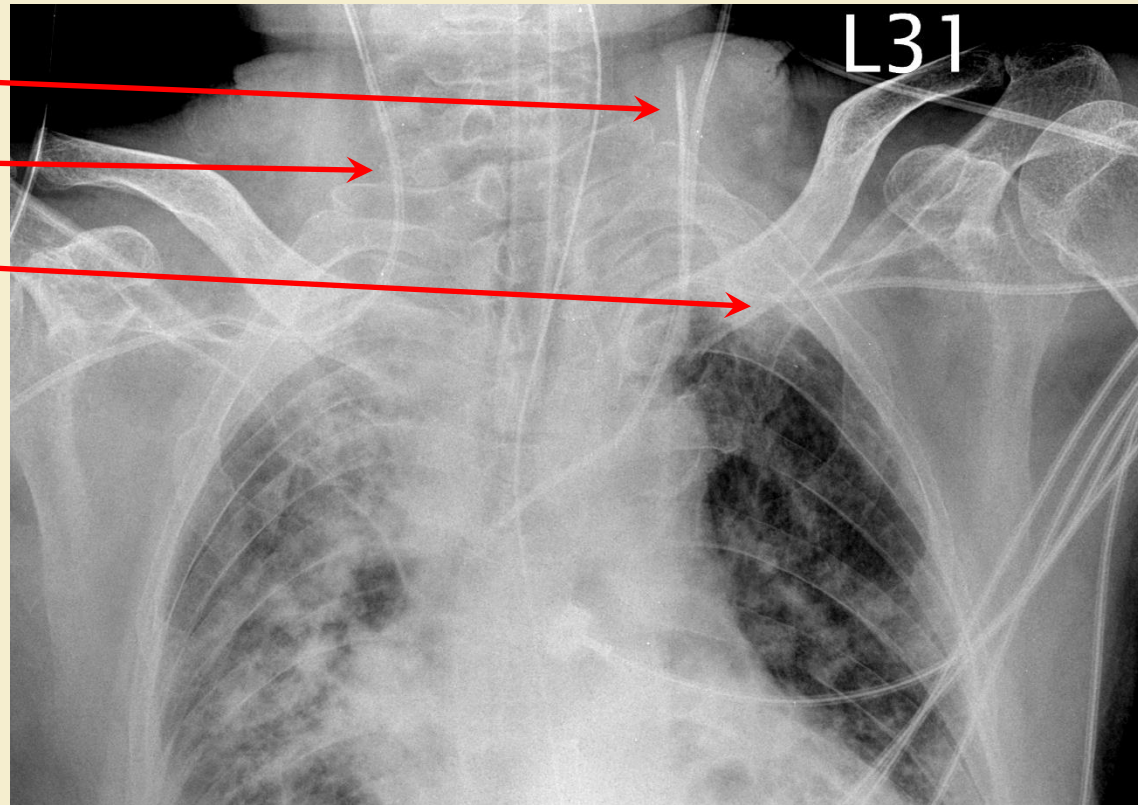


- 新版ACLS已將測EtCO₂列為插管與急救標準步驟

To err is human!

- 1
- 2
- 3

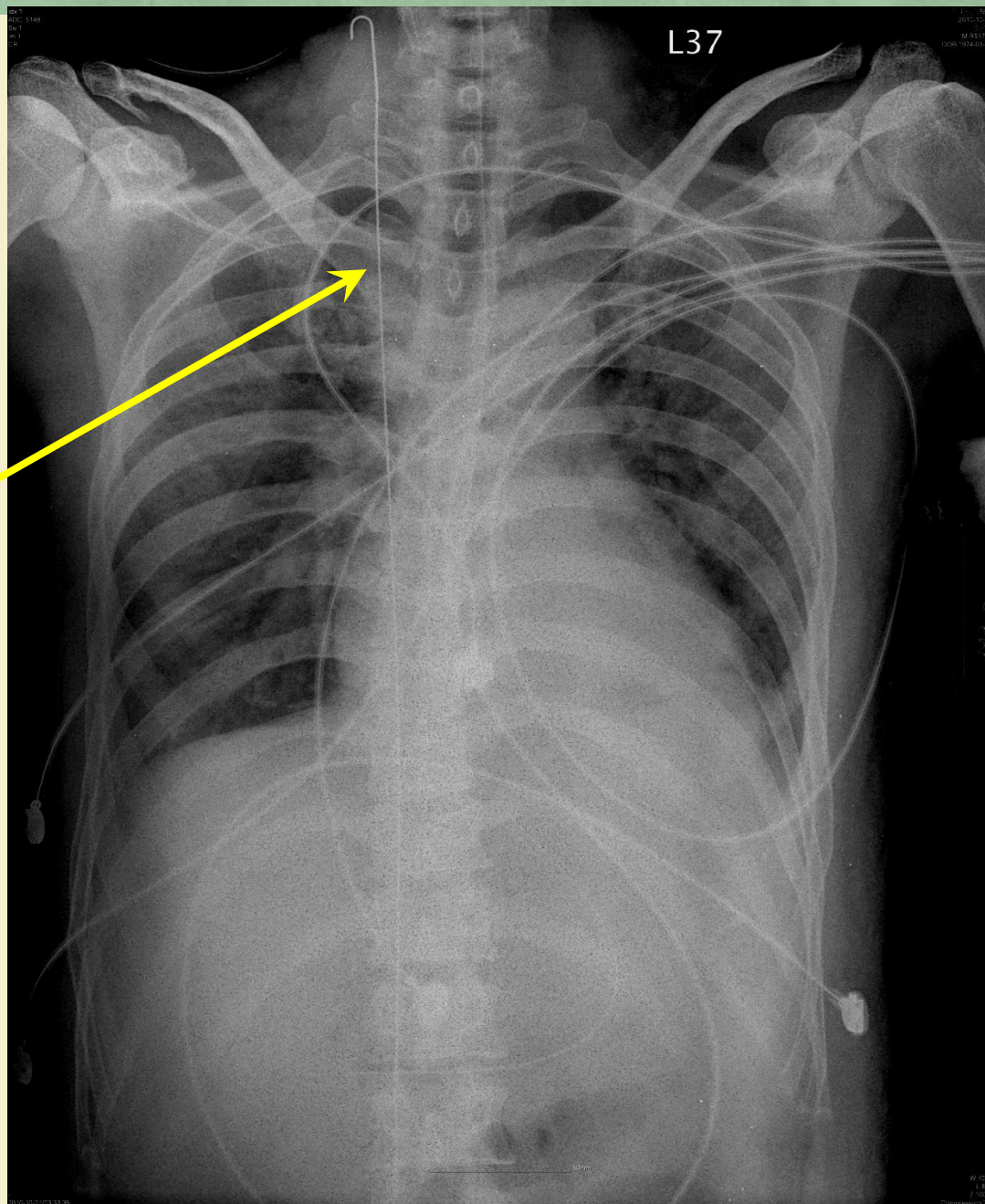
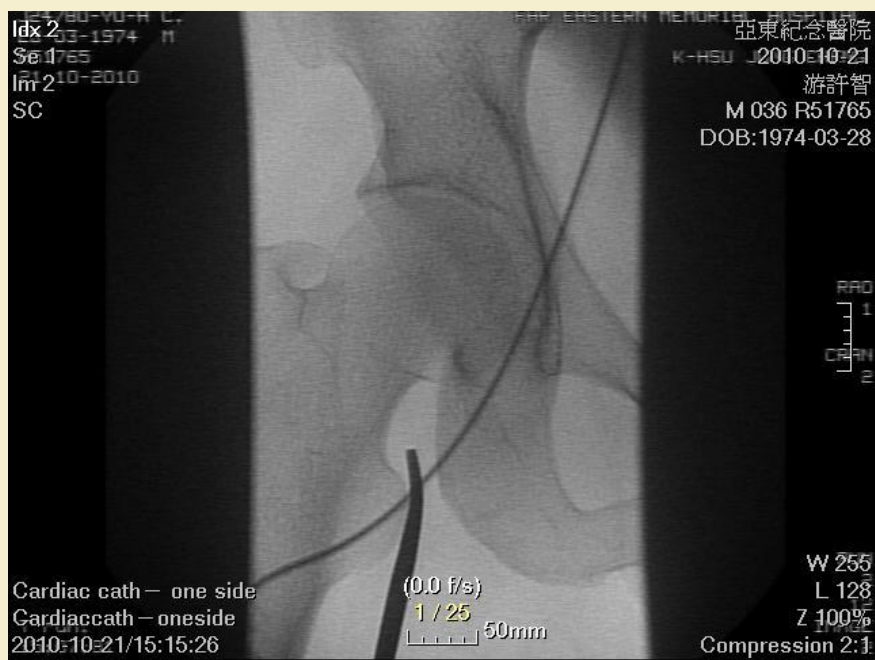下一步該做什麼？



還好有發現!

護理師不是只有給東西
還要點東西

- 在這裡



這是一個“白血”的故事

• In 端

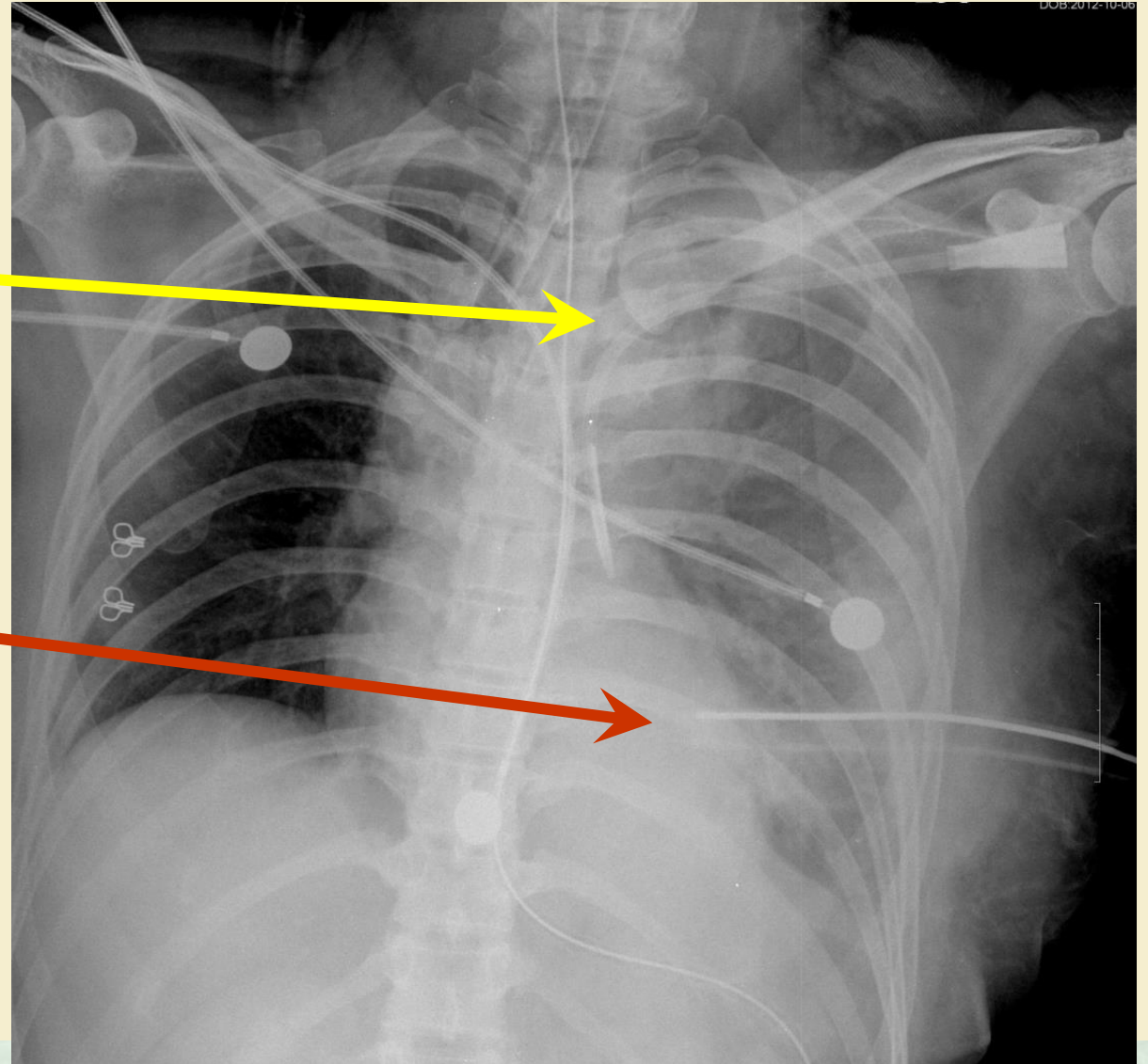
輸入紅色的血

輸入白色的血

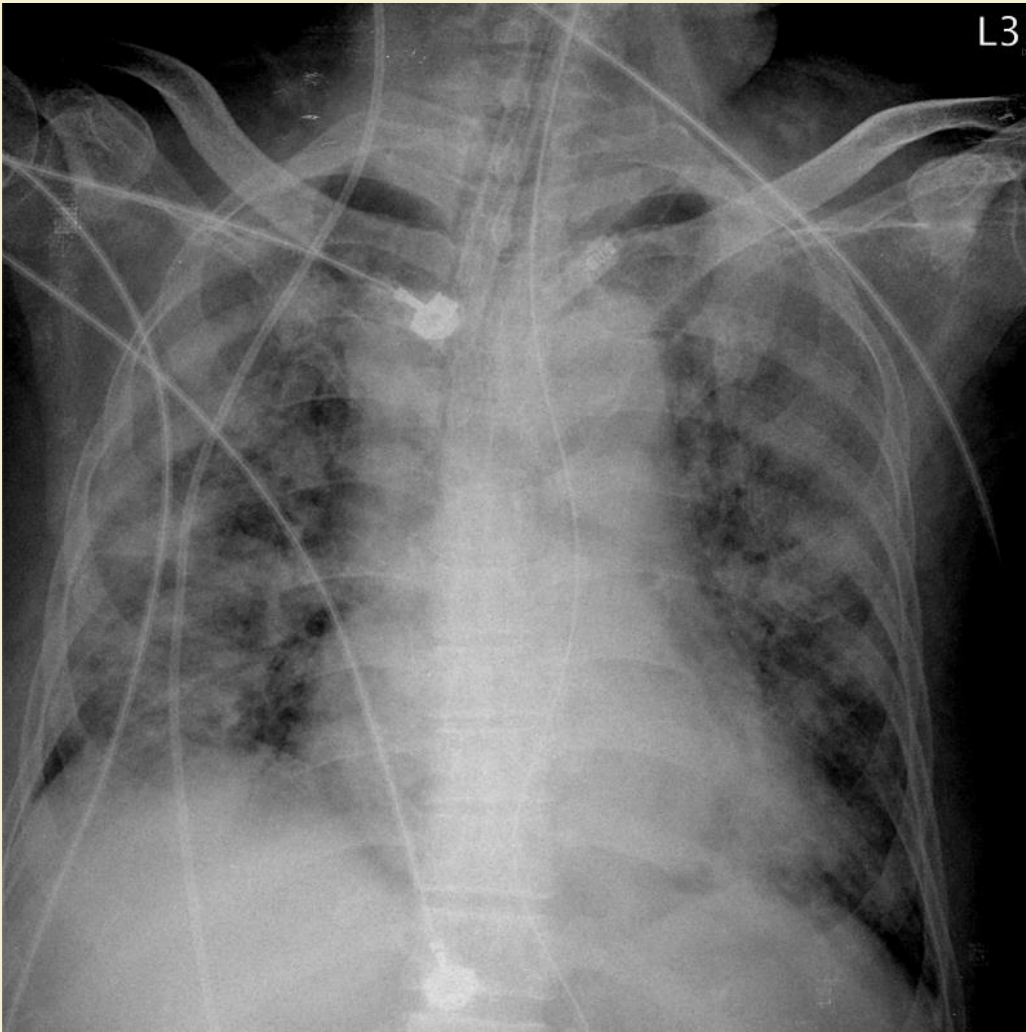
• Out 端

出來紅色的血

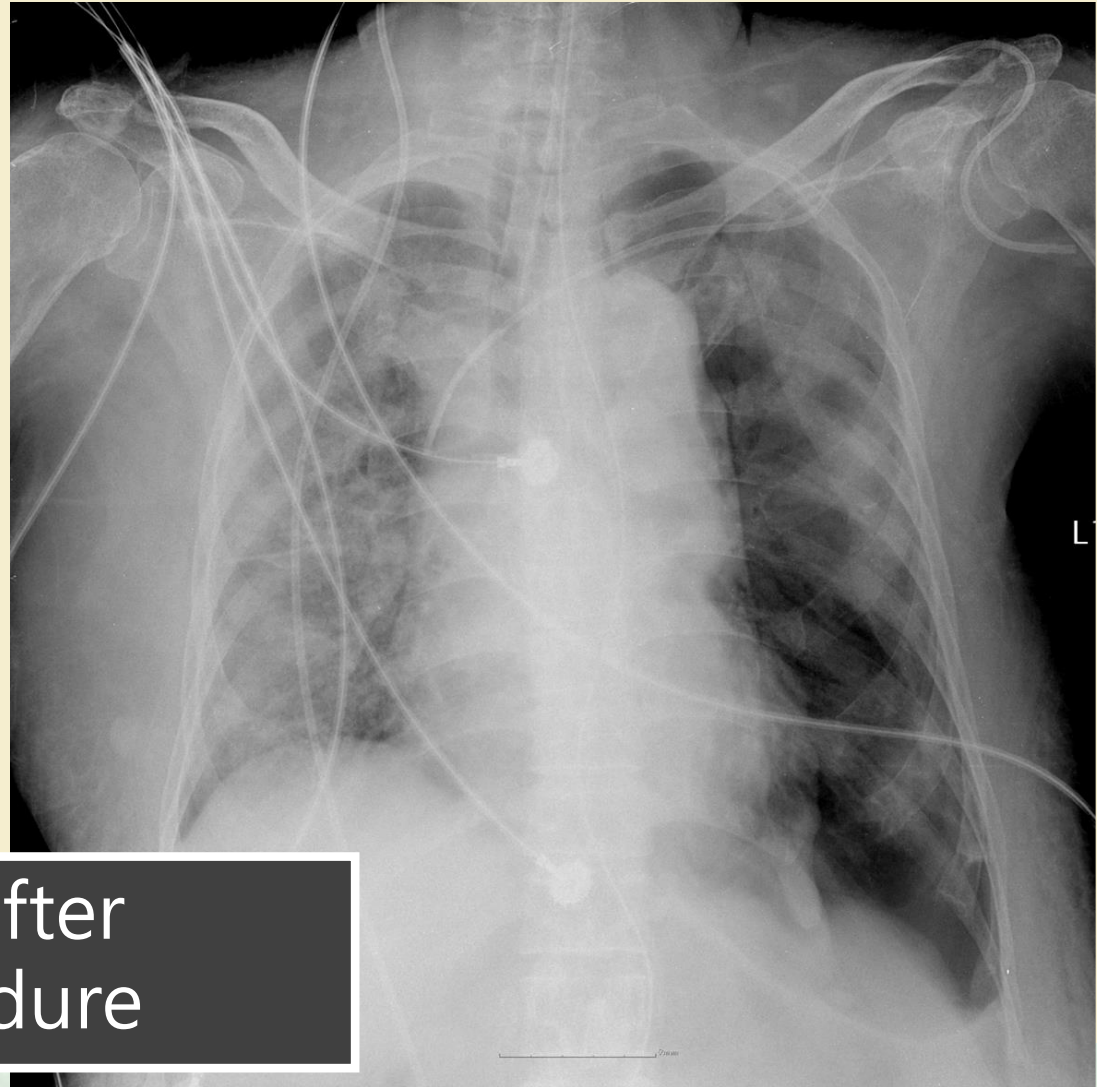
出來白色的血



“買一送一” 的故事



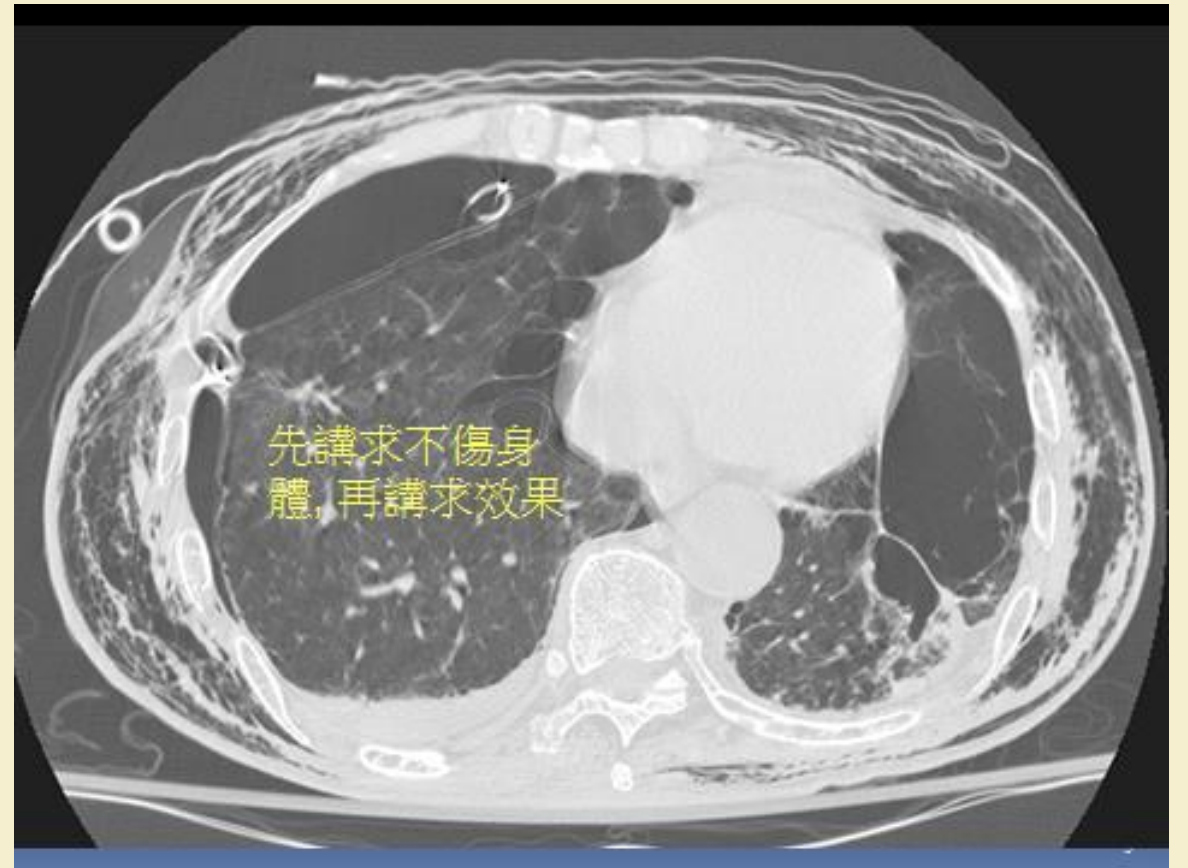
• 4/18 before procedure



* 4/18 after procedure

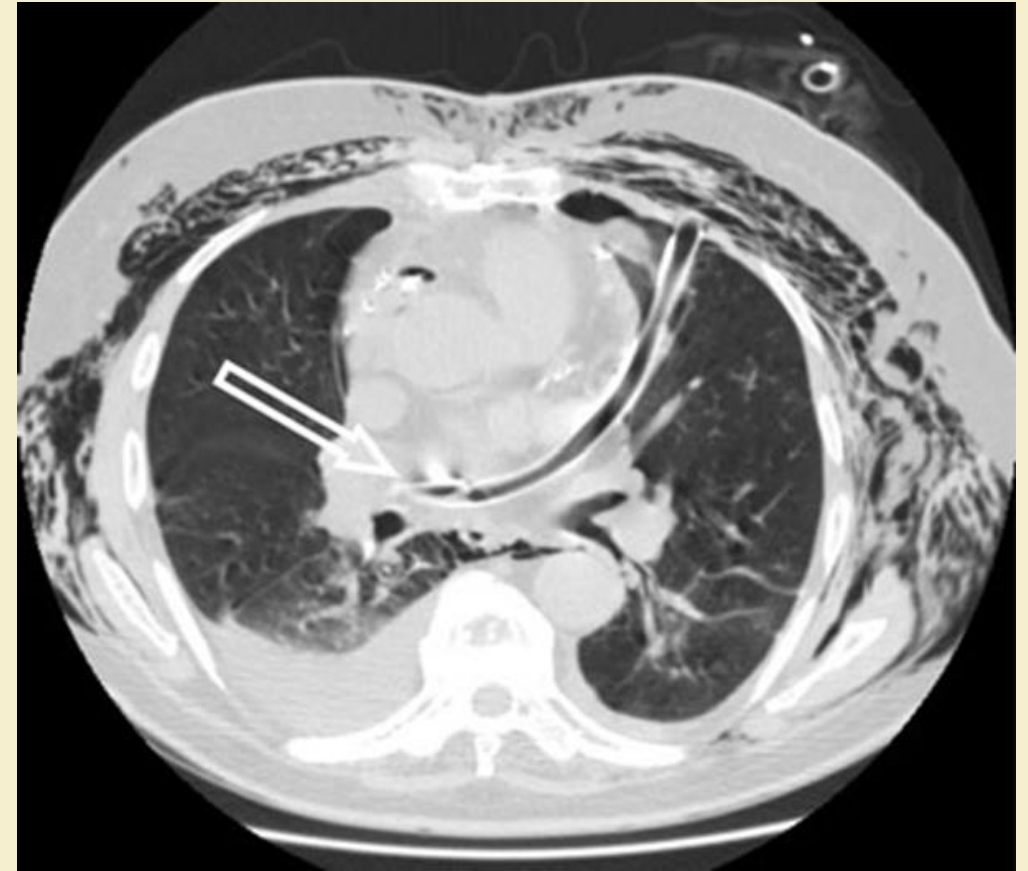
Chest tube thoracostomy

- 側孔應在肋膜腔內
- 不可折彎,
幫忙勸施作者不要用Troca
- CT 診斷率較好

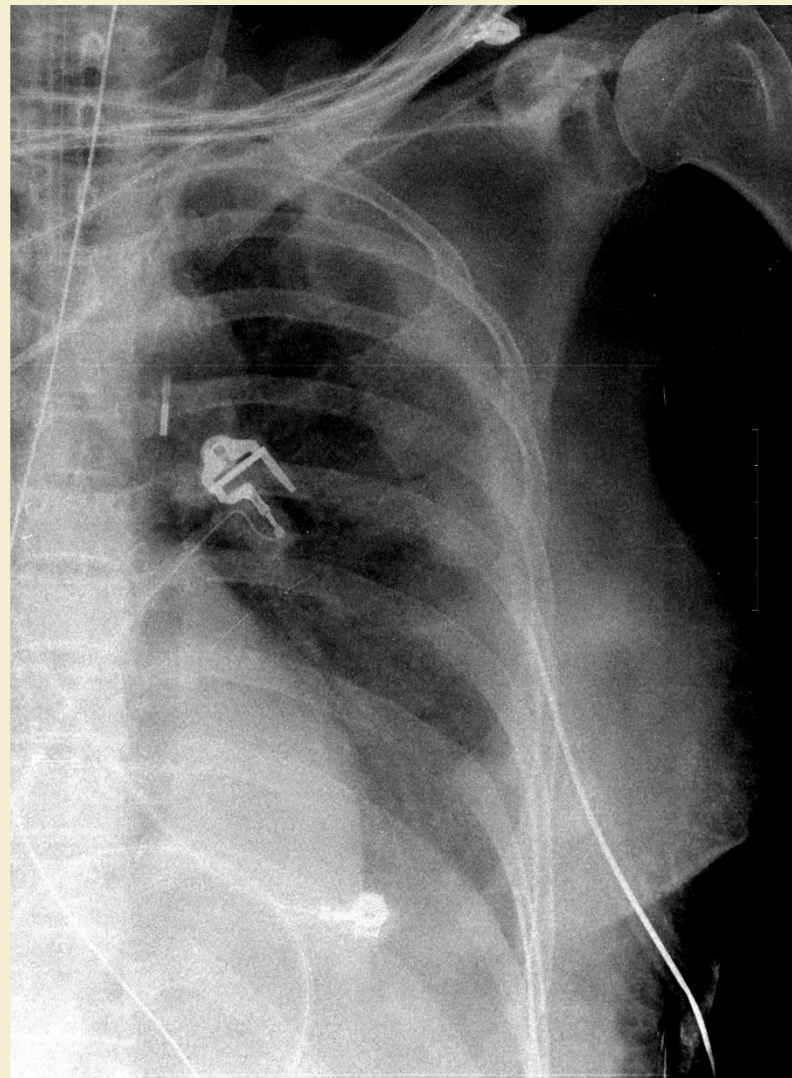
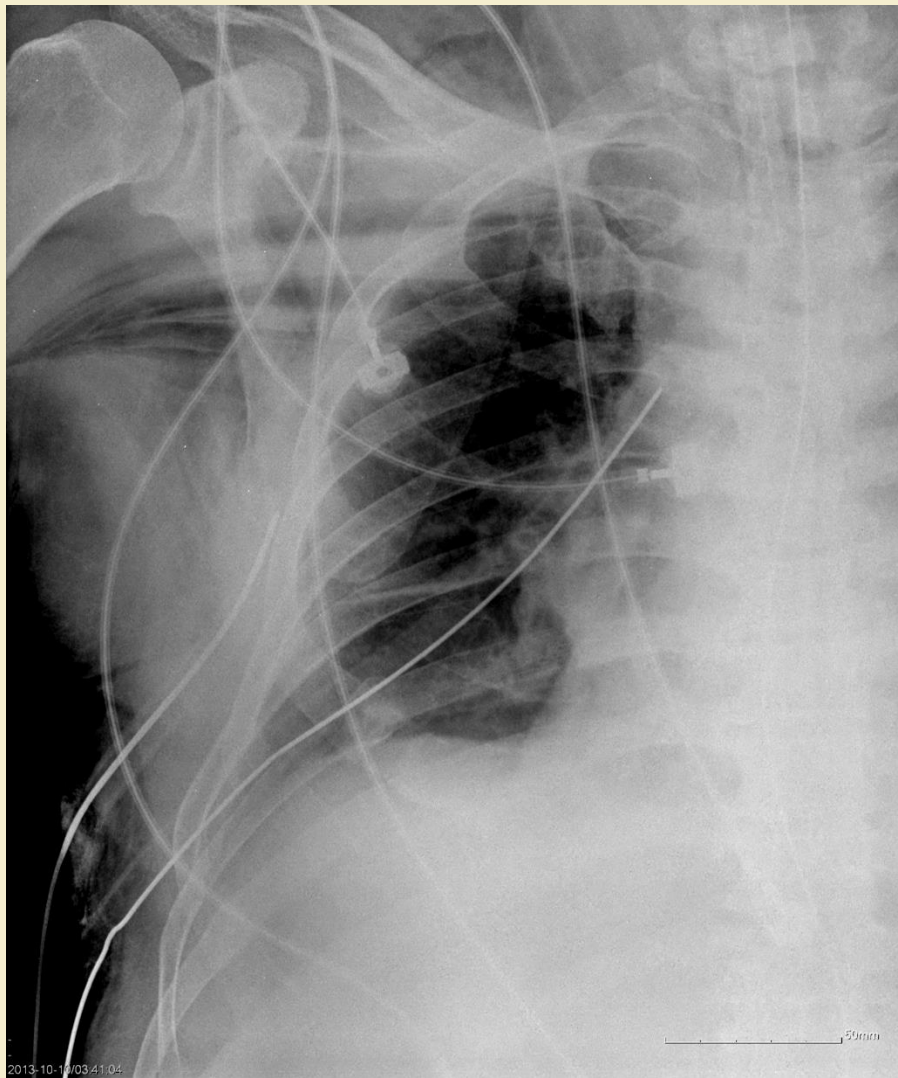


Blunt dissection technique

- 就是插胸管不要用Trocar
- From 2003 - 2008, 17 fatalities reported in the UK. (Most due to insertion of the chest tube into another organ.)
- Trocar是會插死人的!

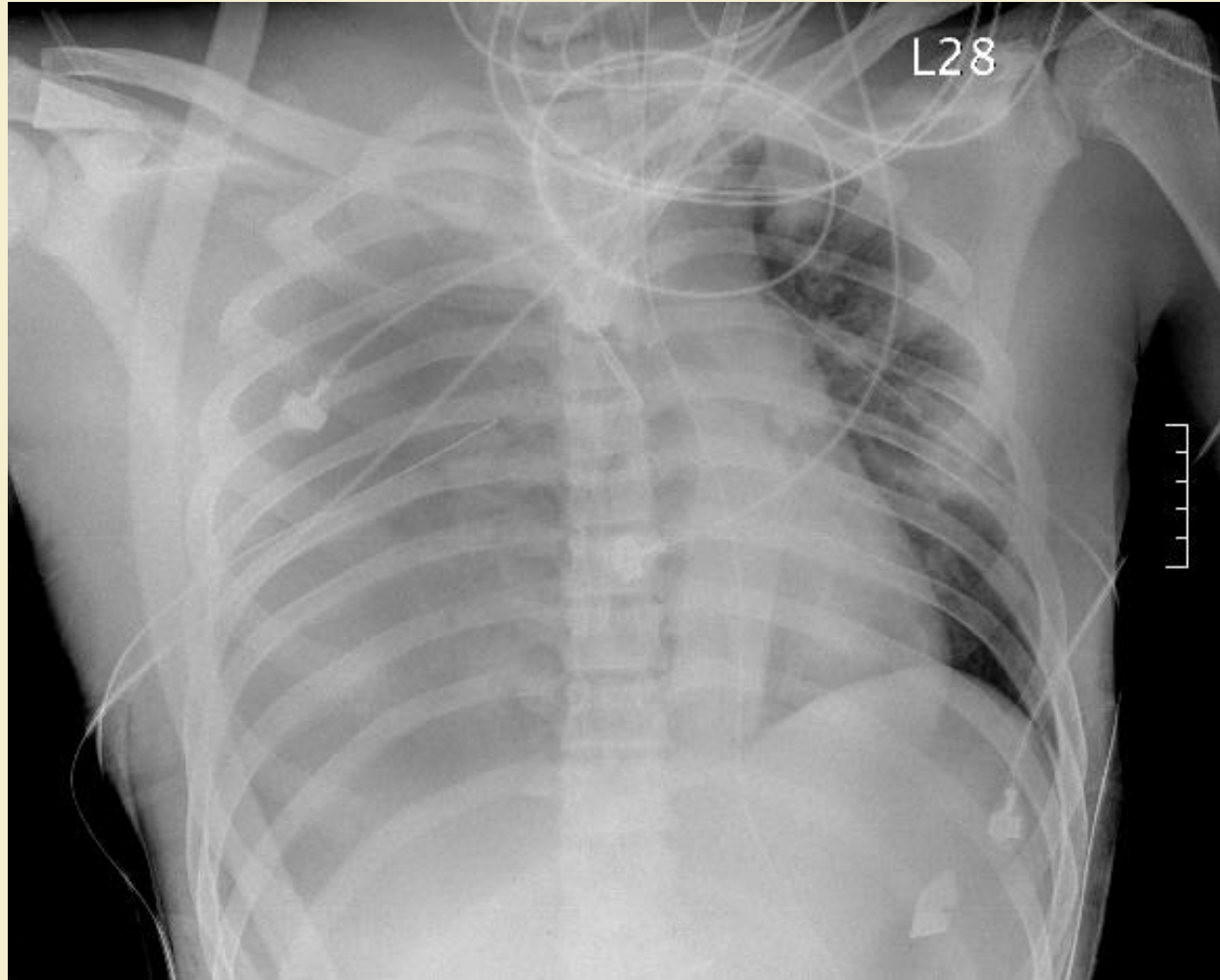


Outside chest tube

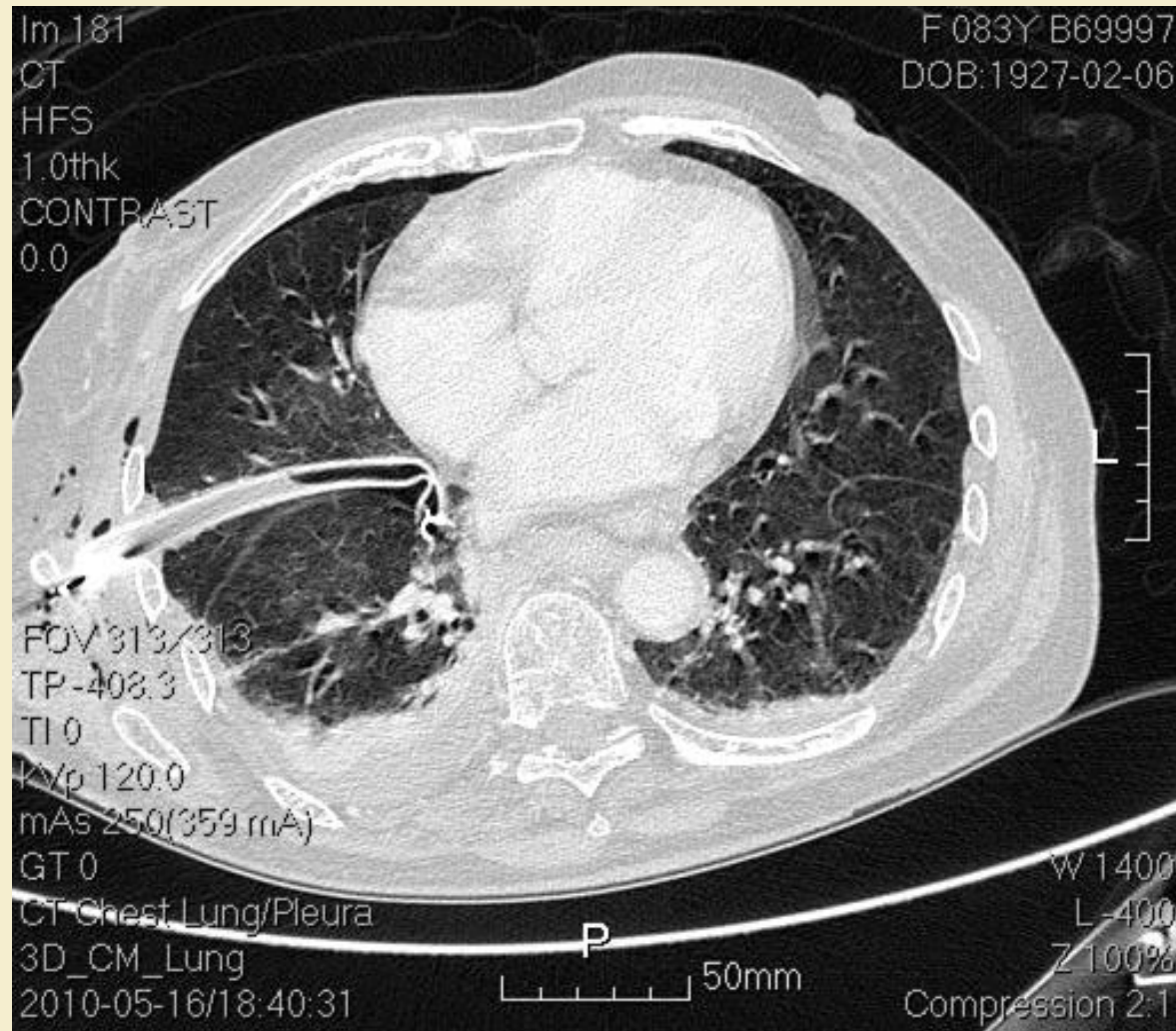
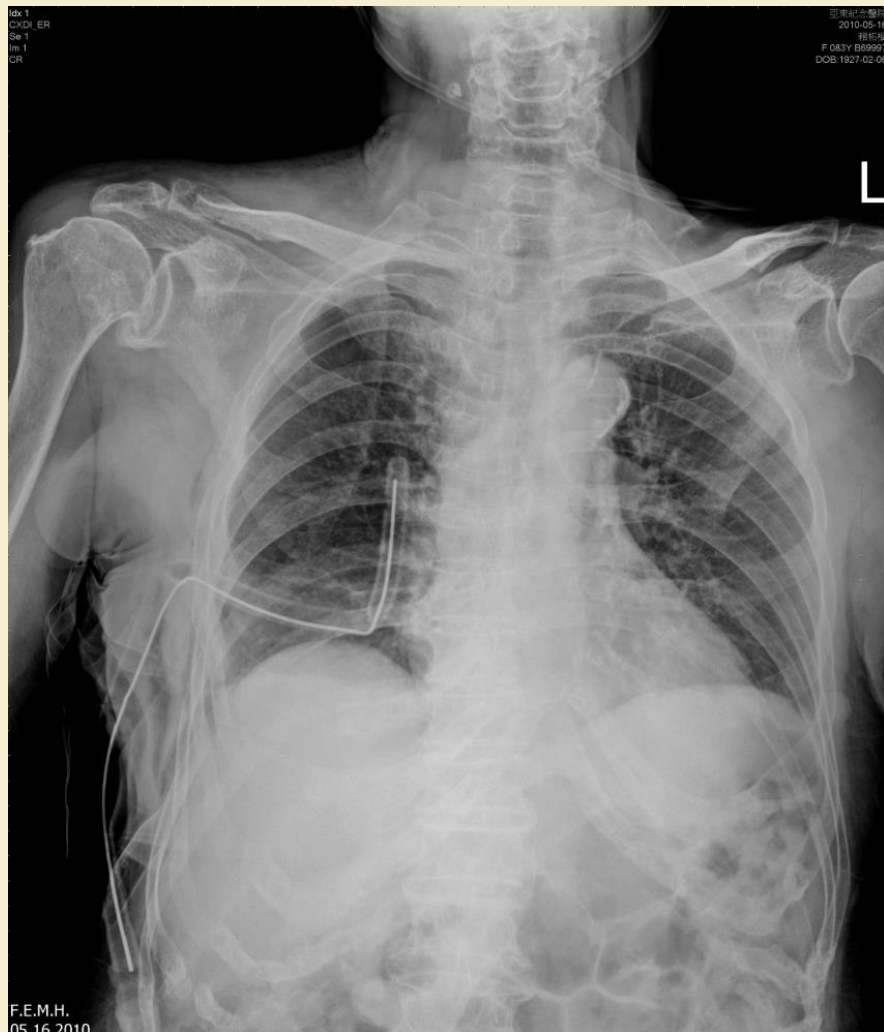

Tension Hemo-Pneumothorax

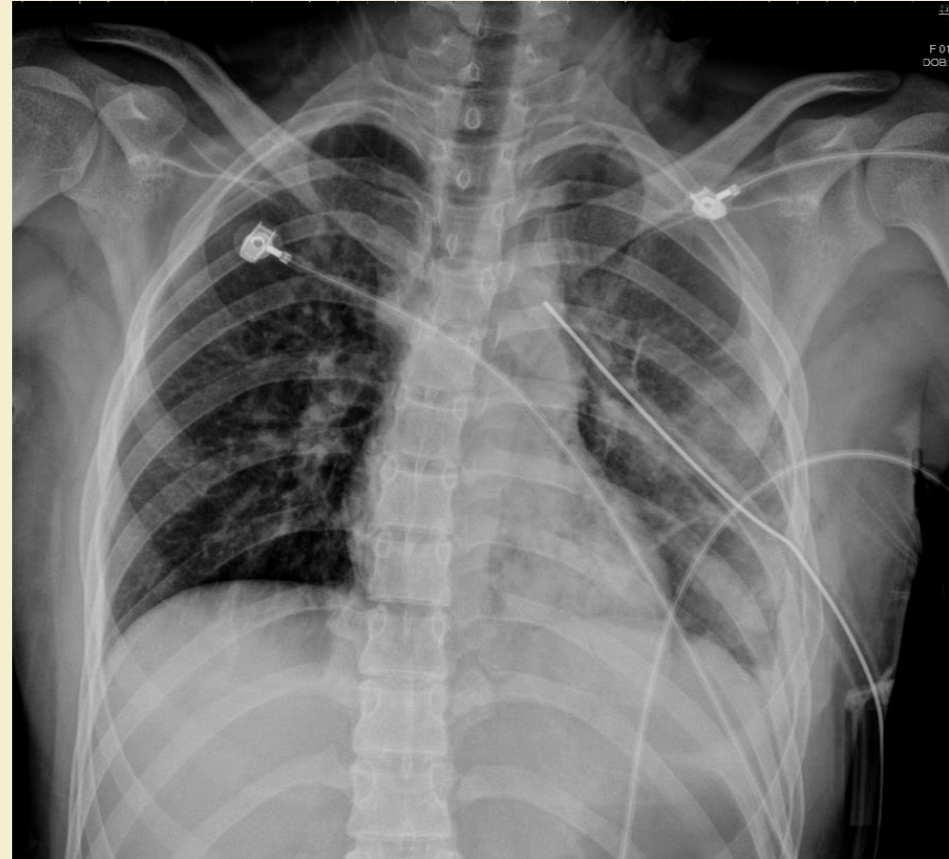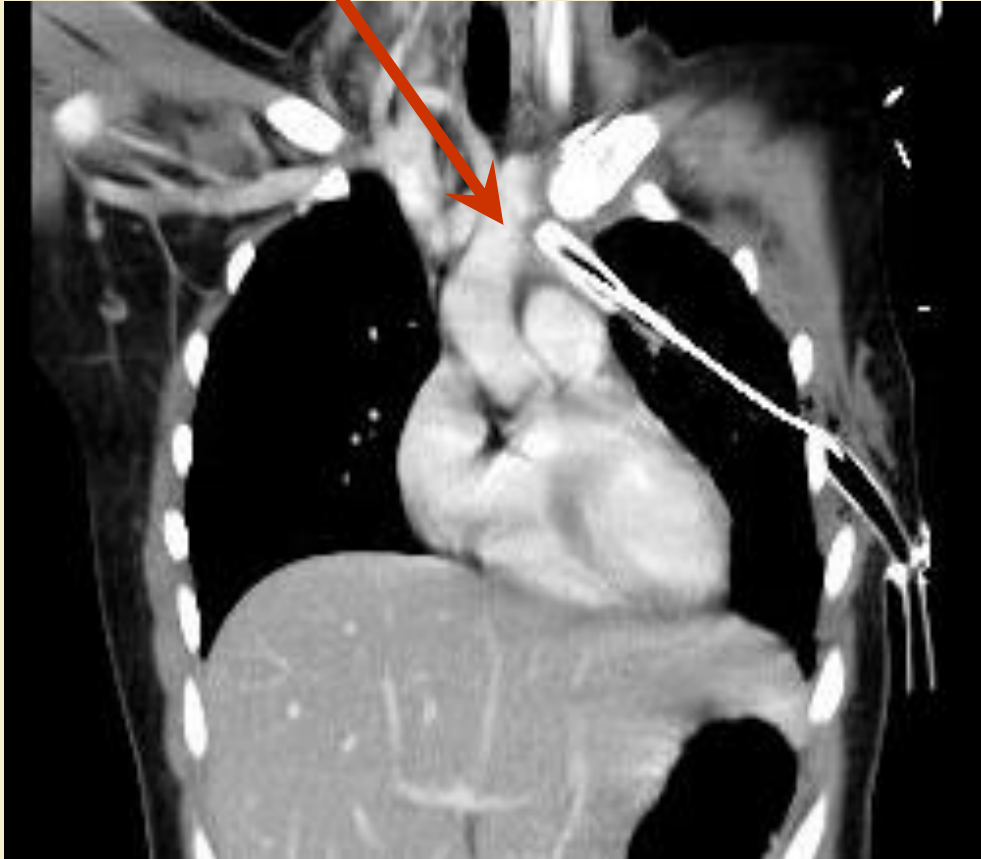
- 有chest tube仍然會發生 (不管是誰on的)
- 有ECMO不代表就安全
- PE一定比X光快



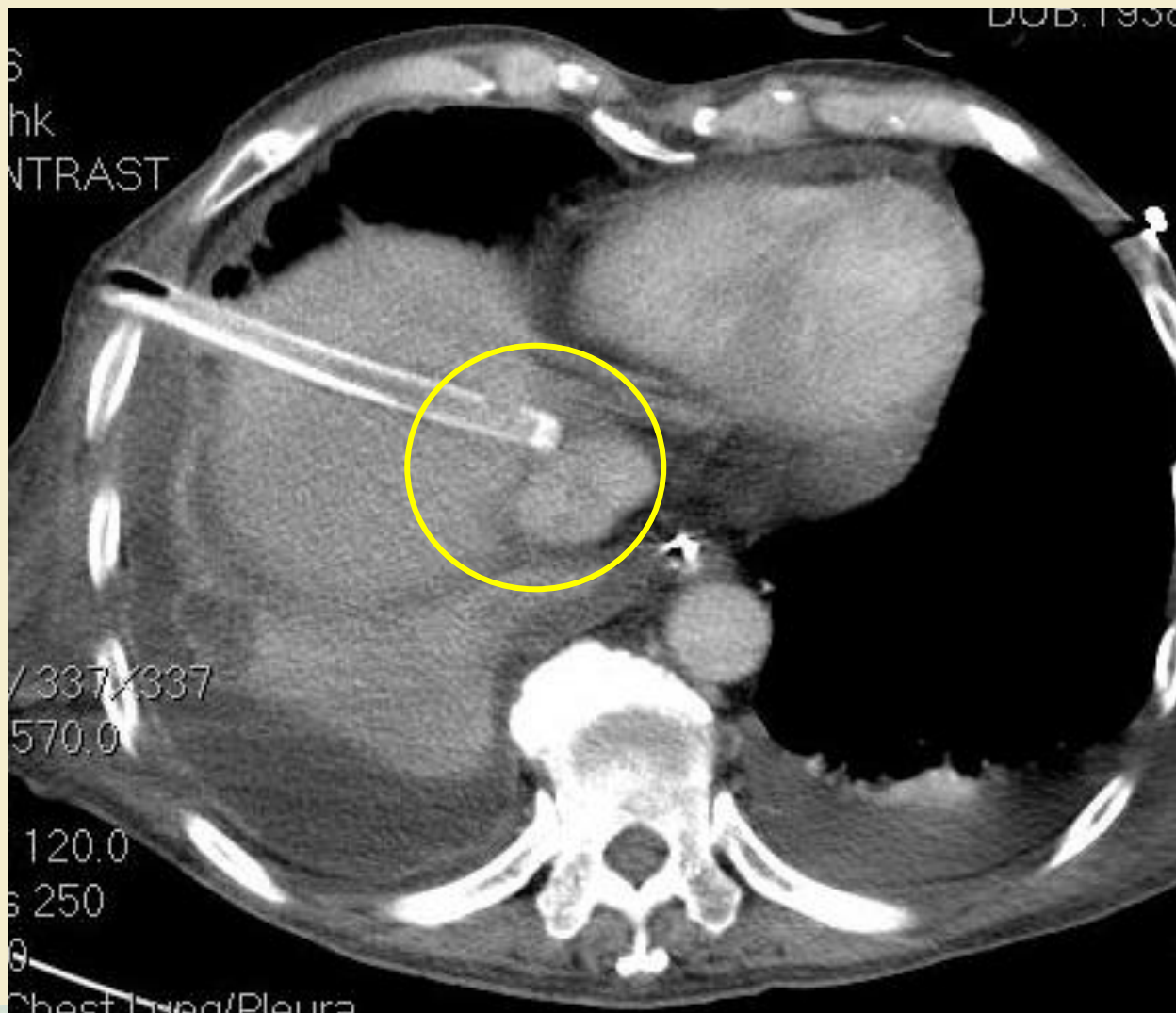
看! Y! 折到了



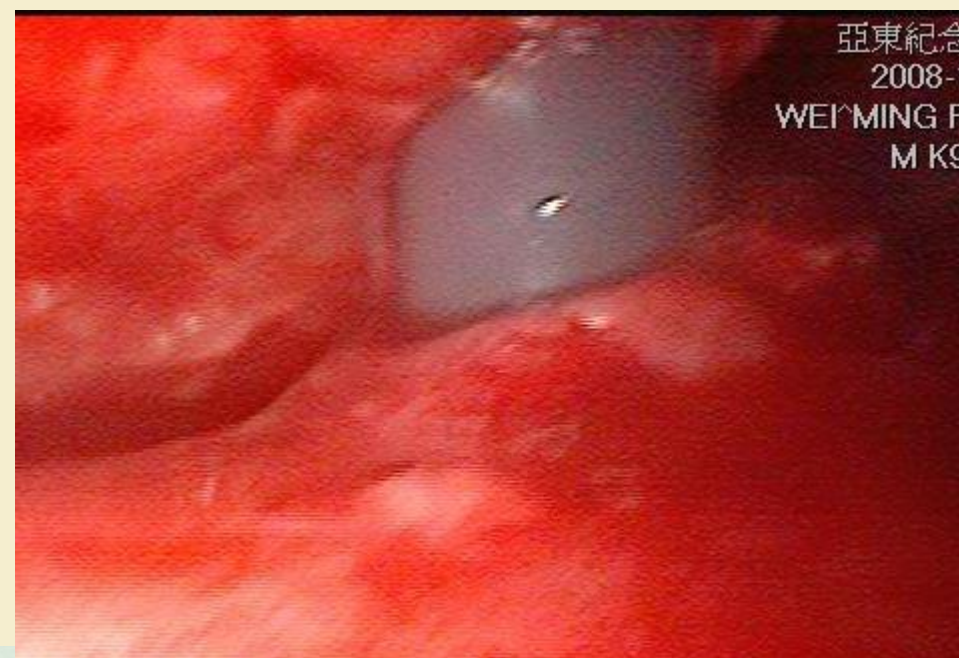
還差一點點....



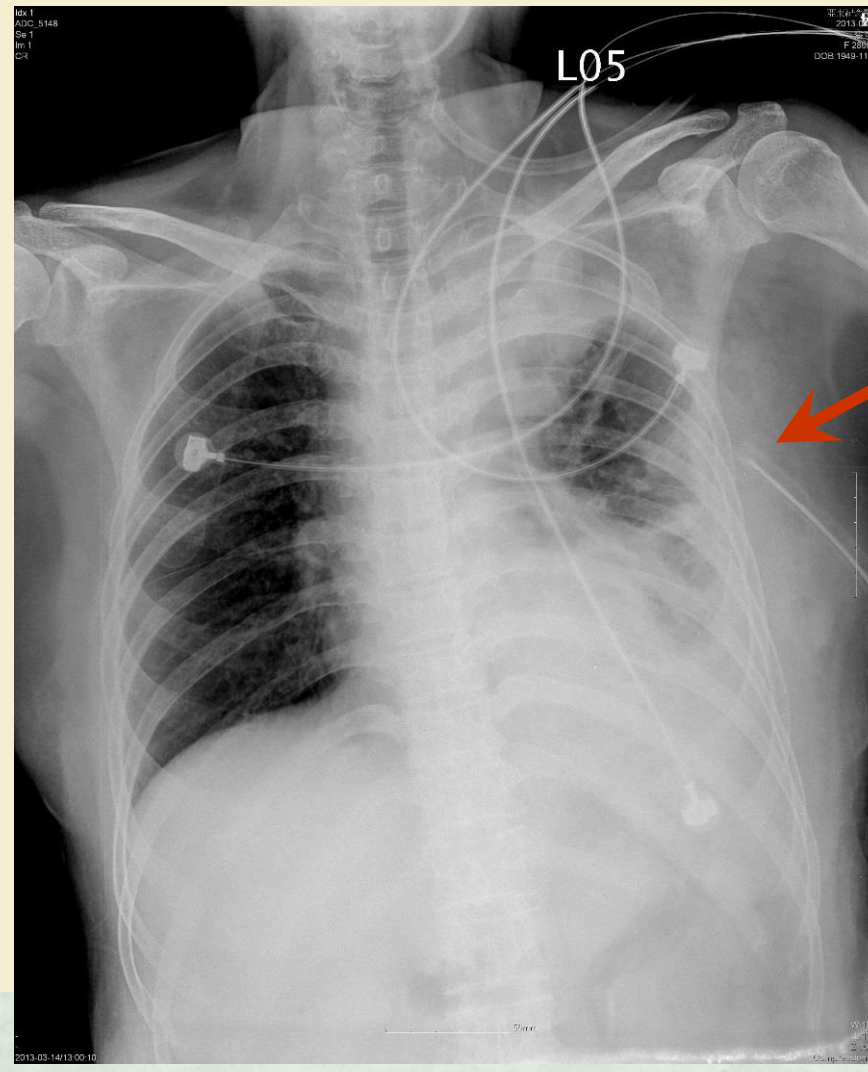
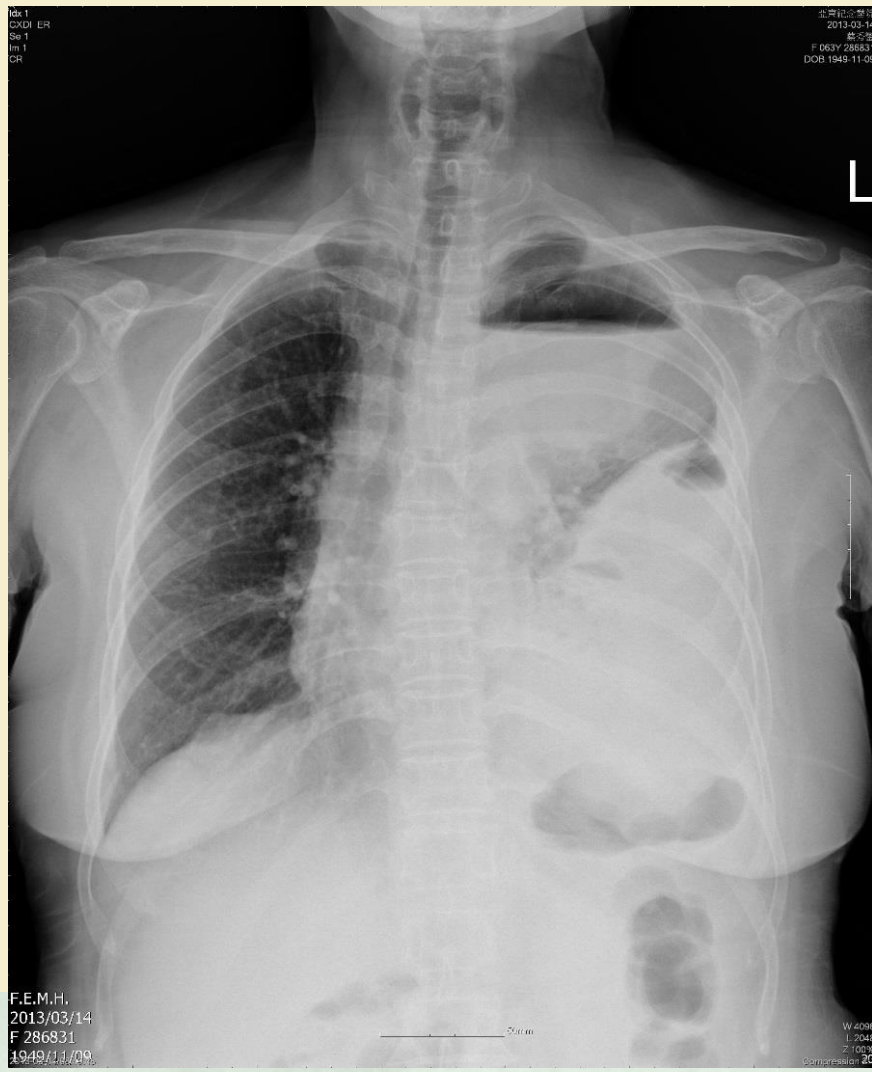
經典穿越鏡頭



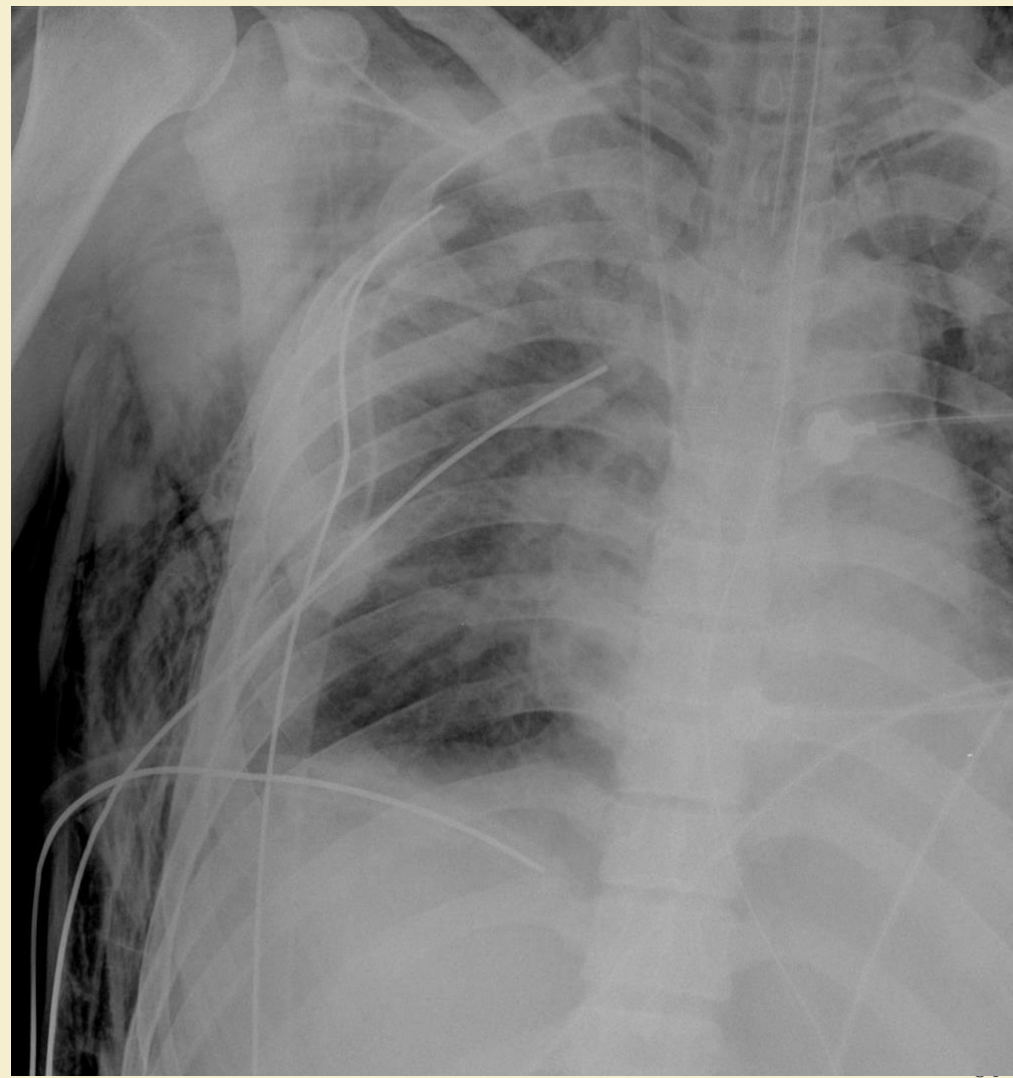
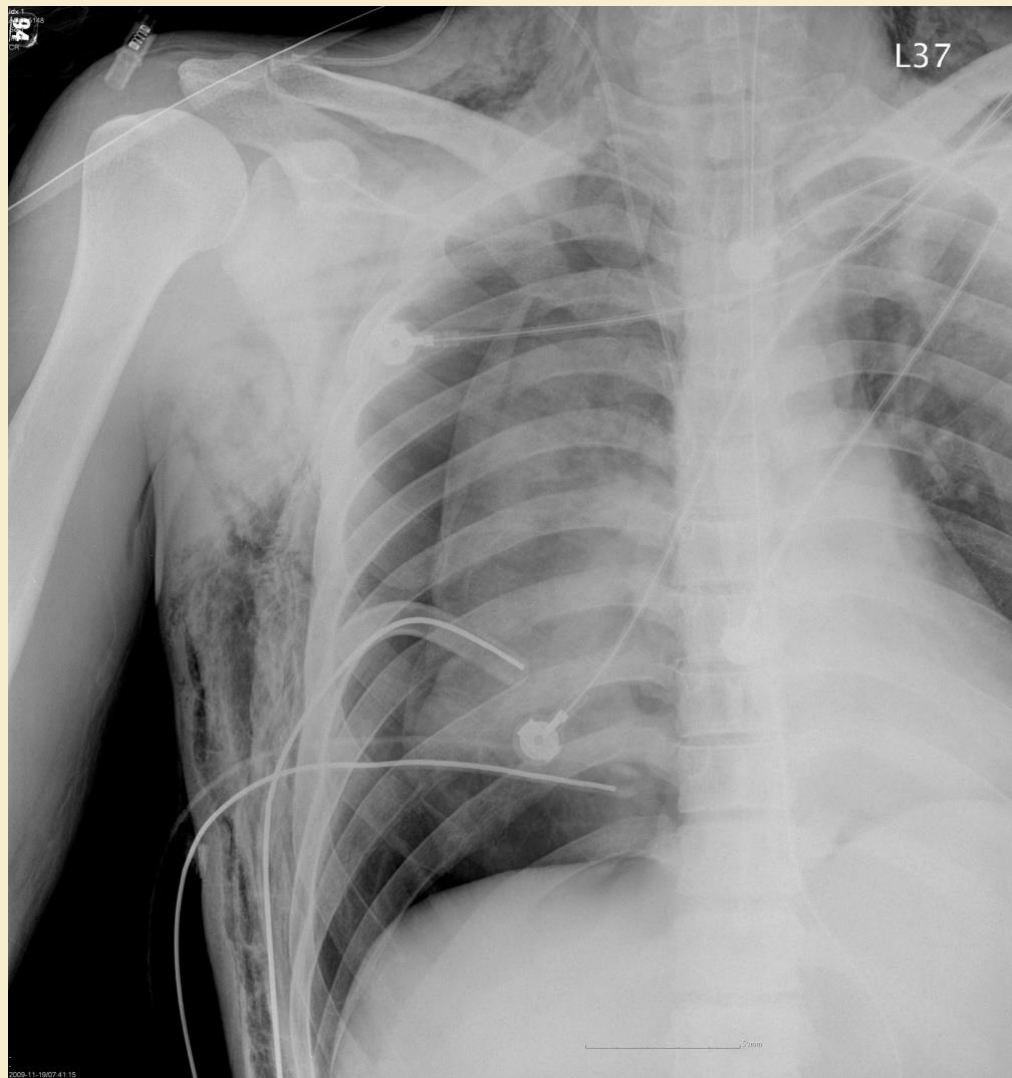
- “咫尺天涯” 就是這個意思



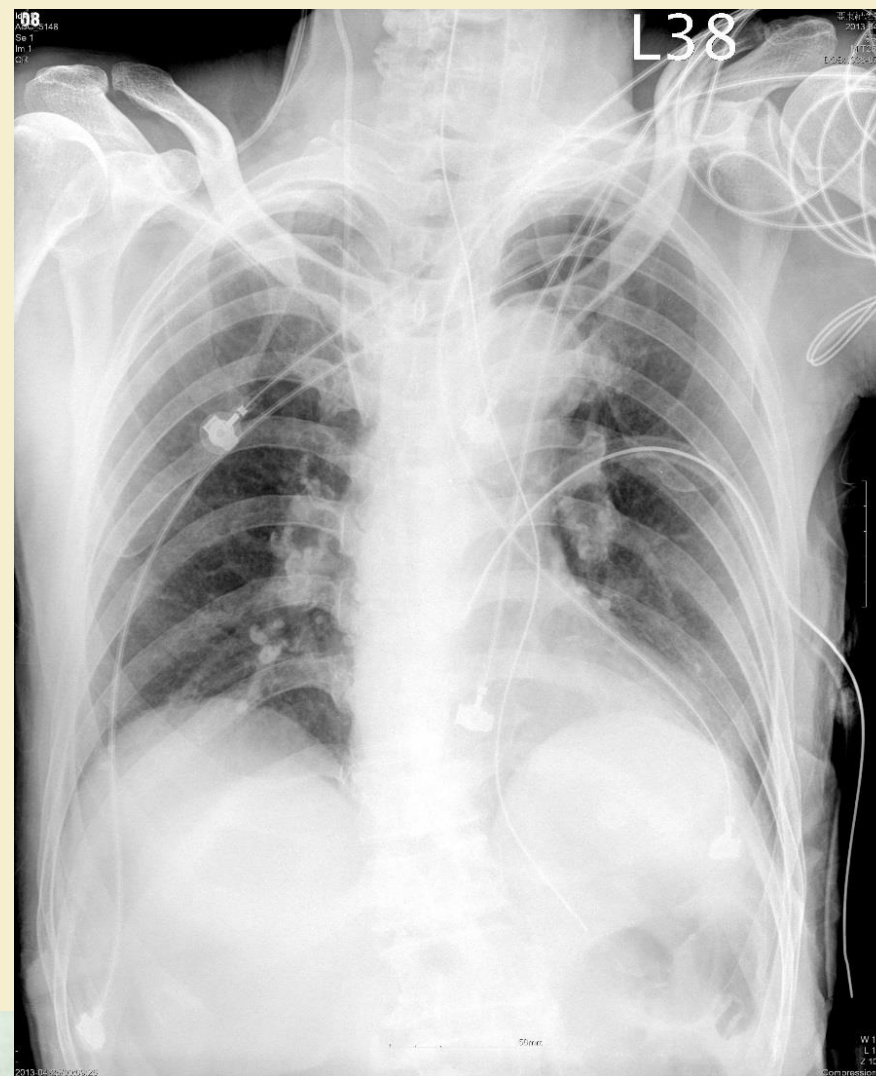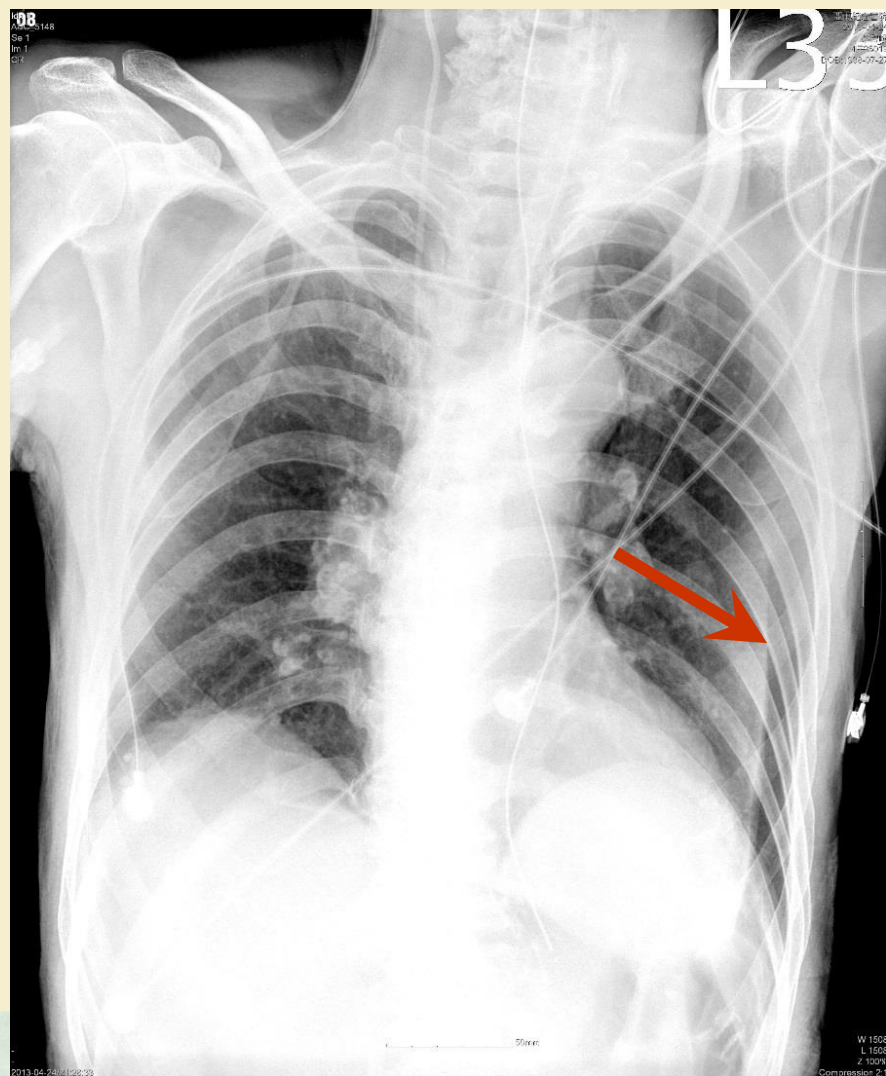
PUS引流到皮下~



萬箭穿心？

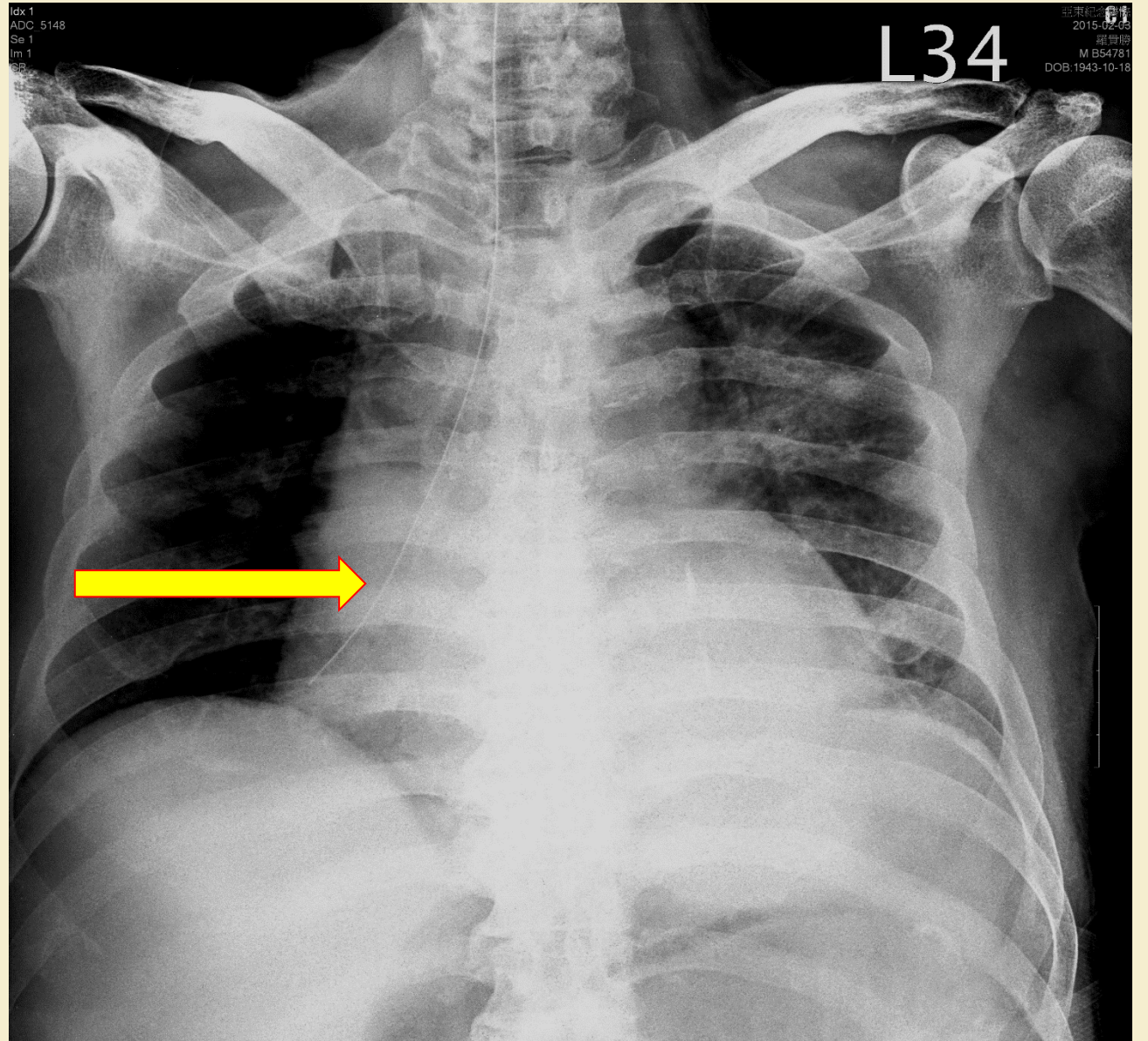


該發生的終究會發生

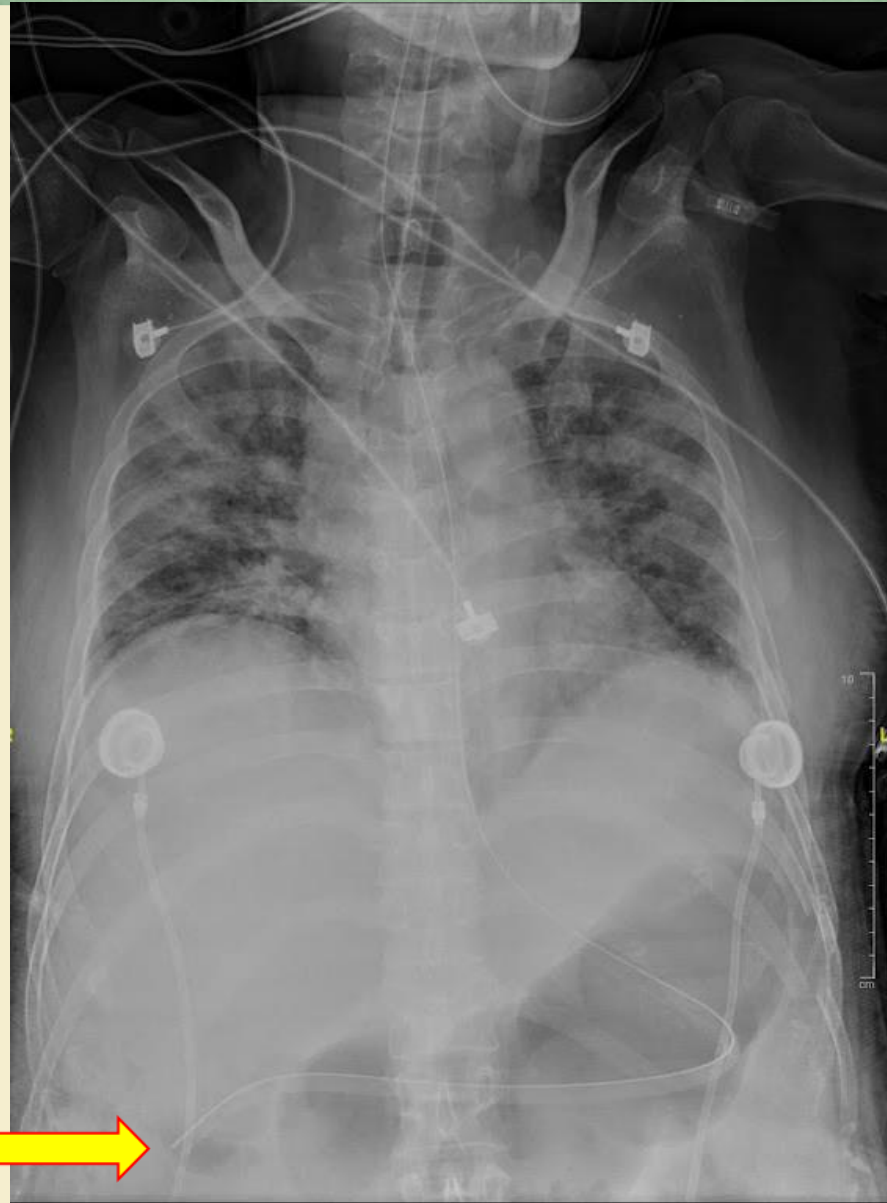

插鼻胃管，病患成 植物人 賠2500萬

插鼻胃管後，出現呼吸急速、
血壓及心跳下降，因缺氧過久
導致缺氧性腦病變。第一審判
賠31,008,804元，二審改判
28,008,804元。【臺灣高等法
院臺中分院民事判決99年度醫
上字第6號】



ND insertion
without PES

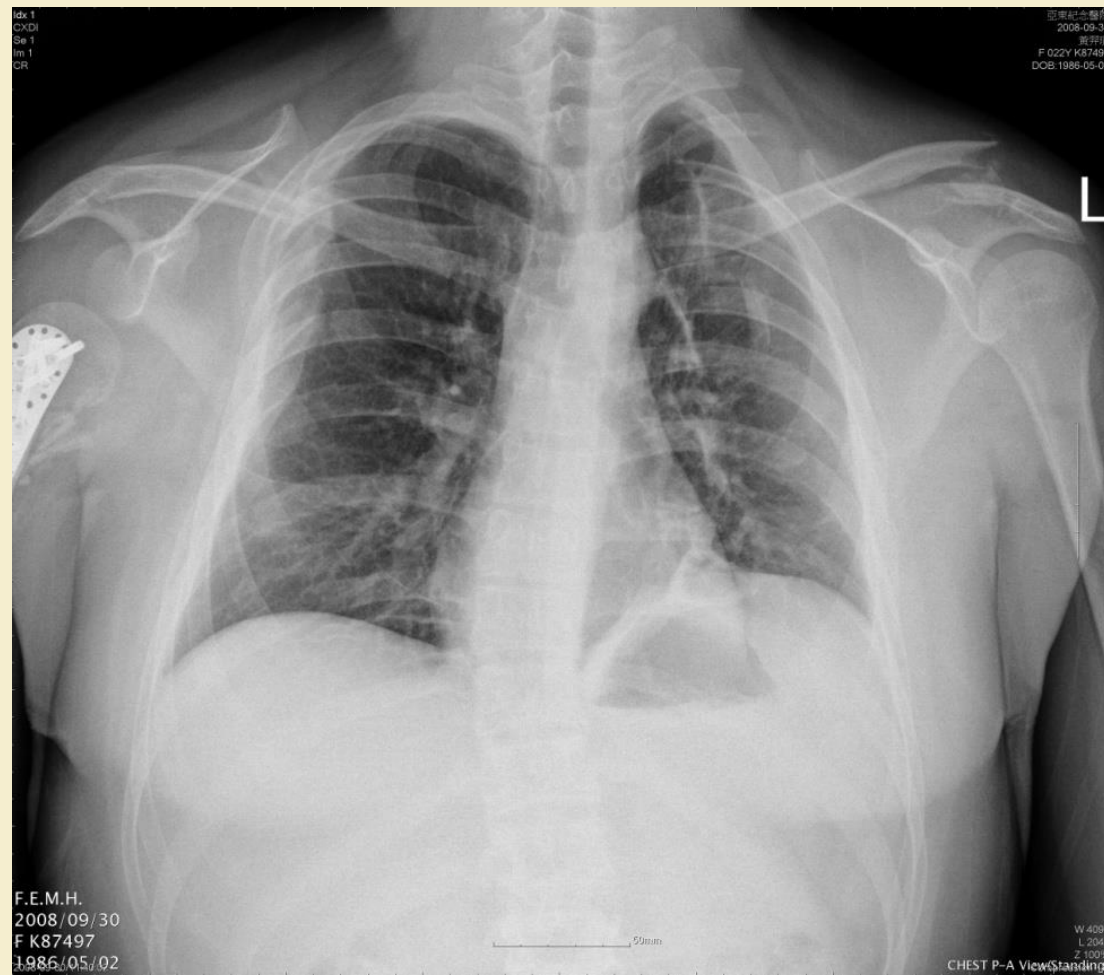
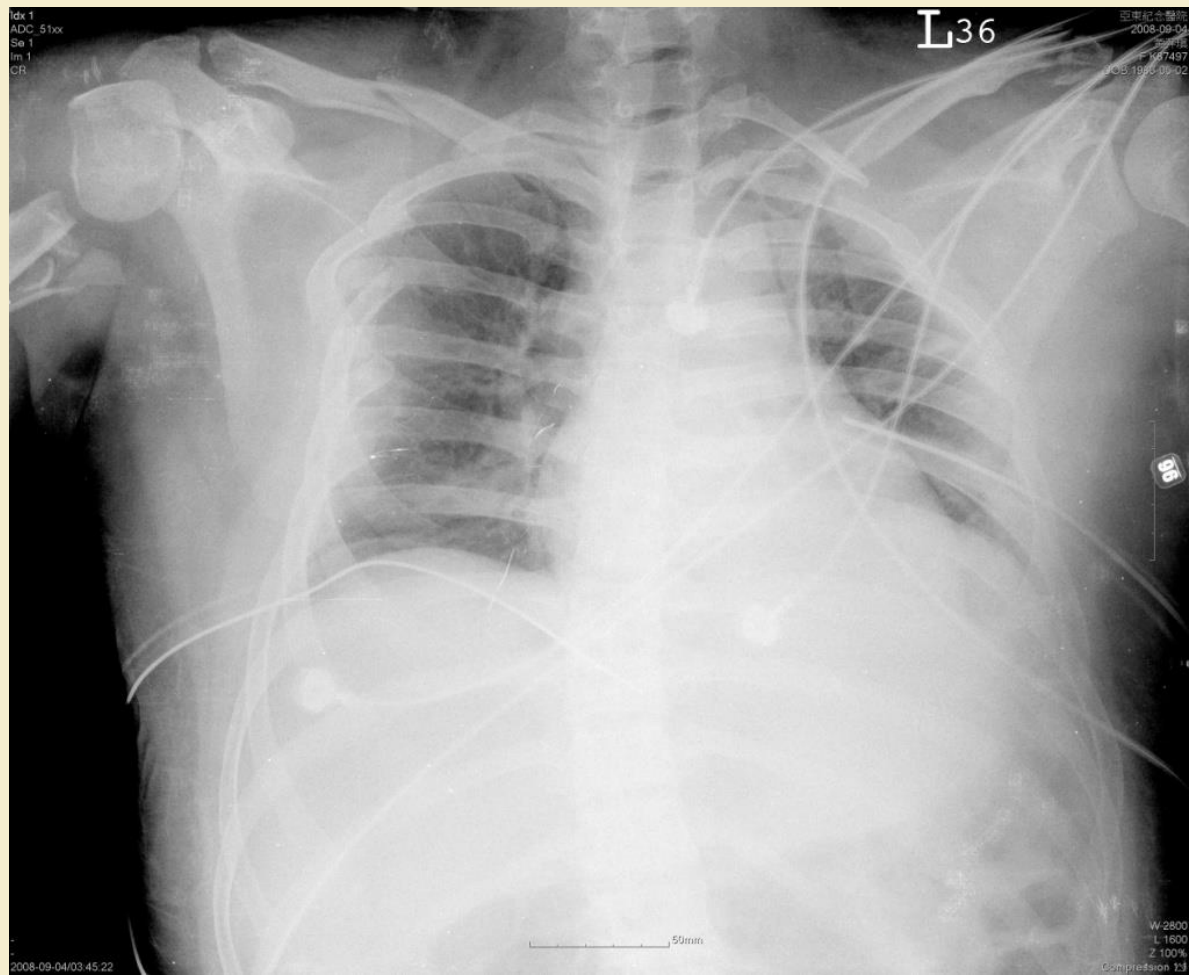


Chest radiograph is routinely used to assess the appropriate positioning of support devices

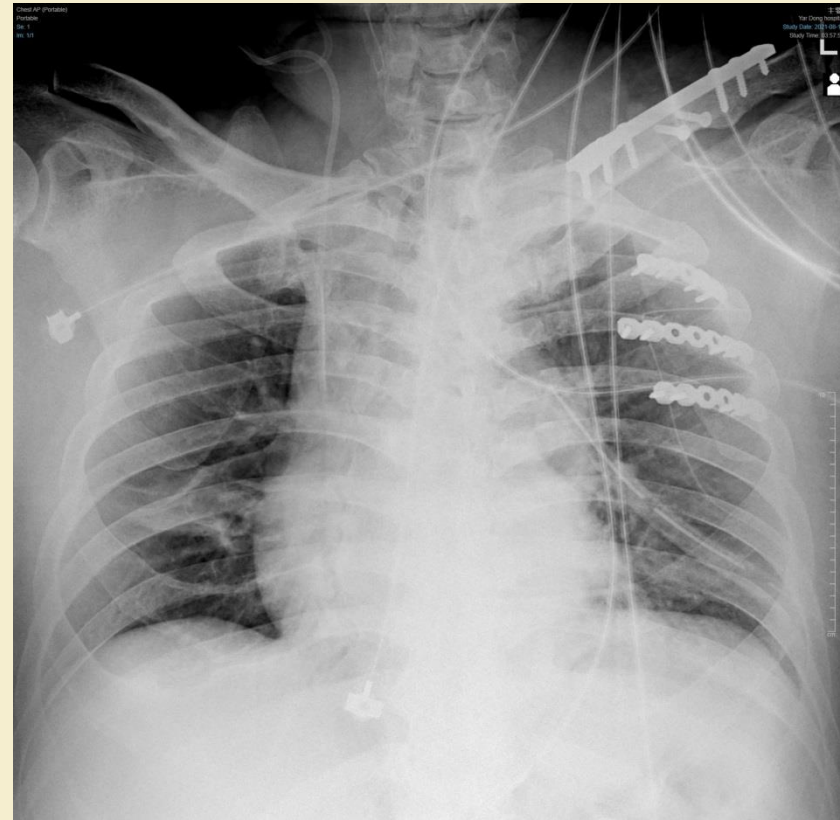
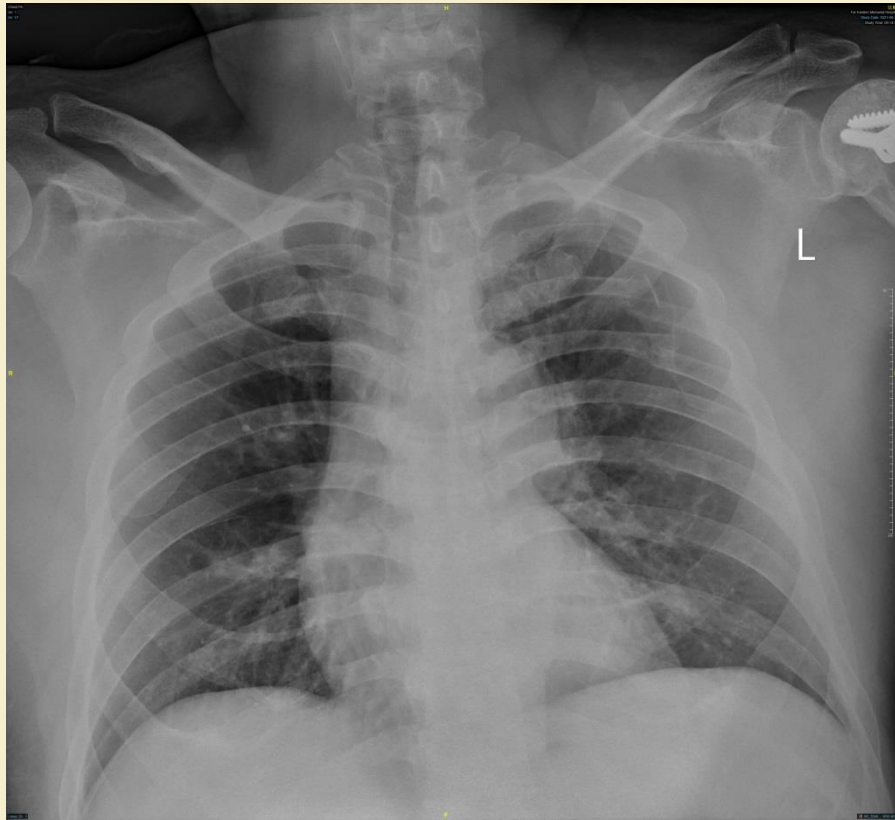
- An increased awareness of normal and incorrect positions of support devices on chest radiographs can prevent the development of adverse events.

The END: Chest Wall Deformity

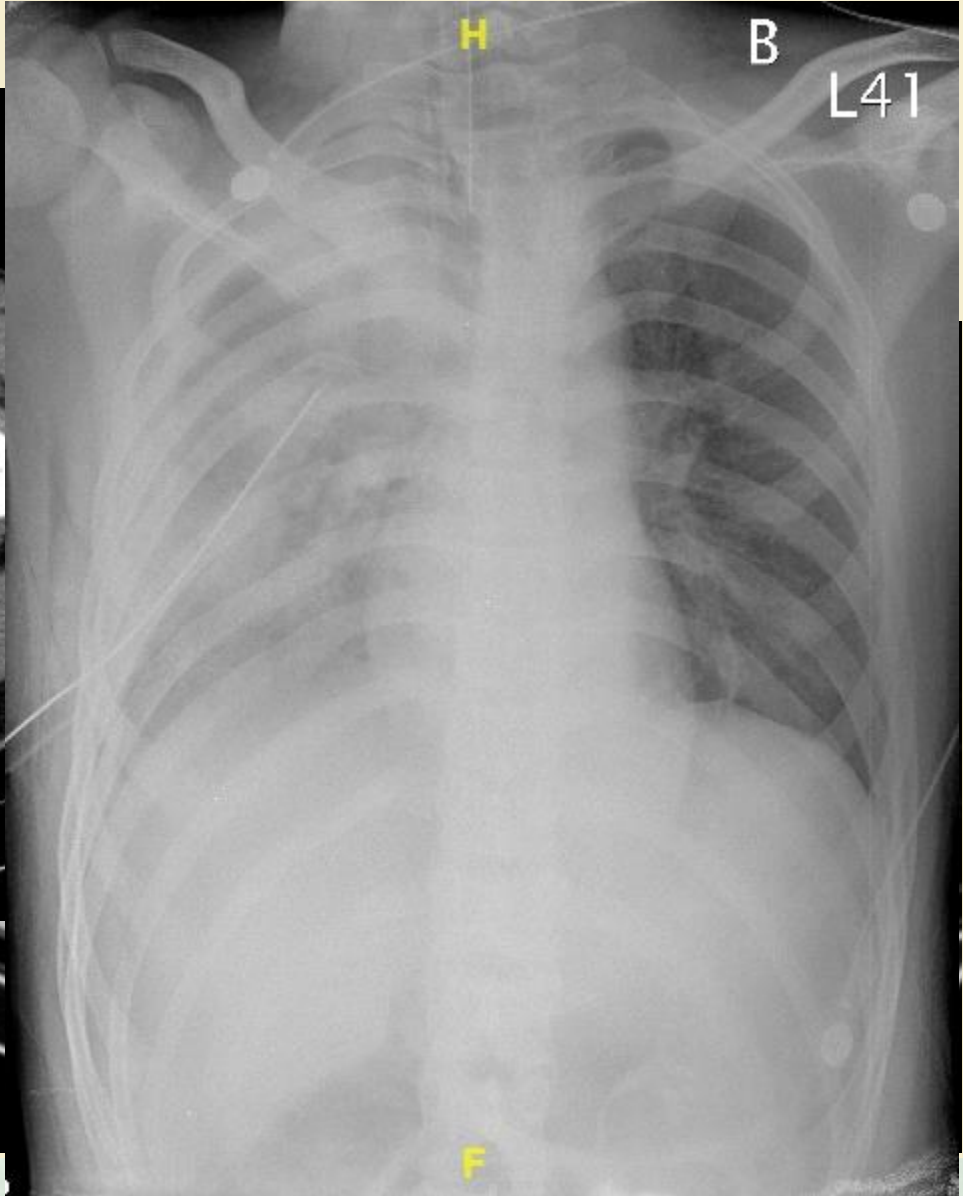
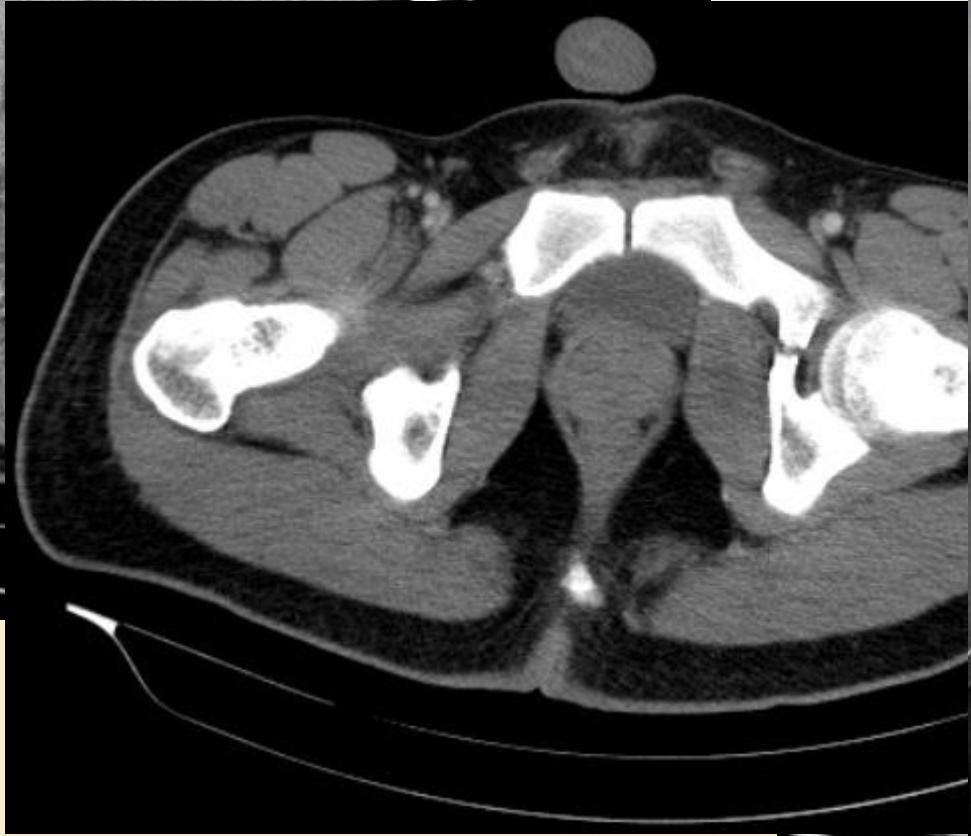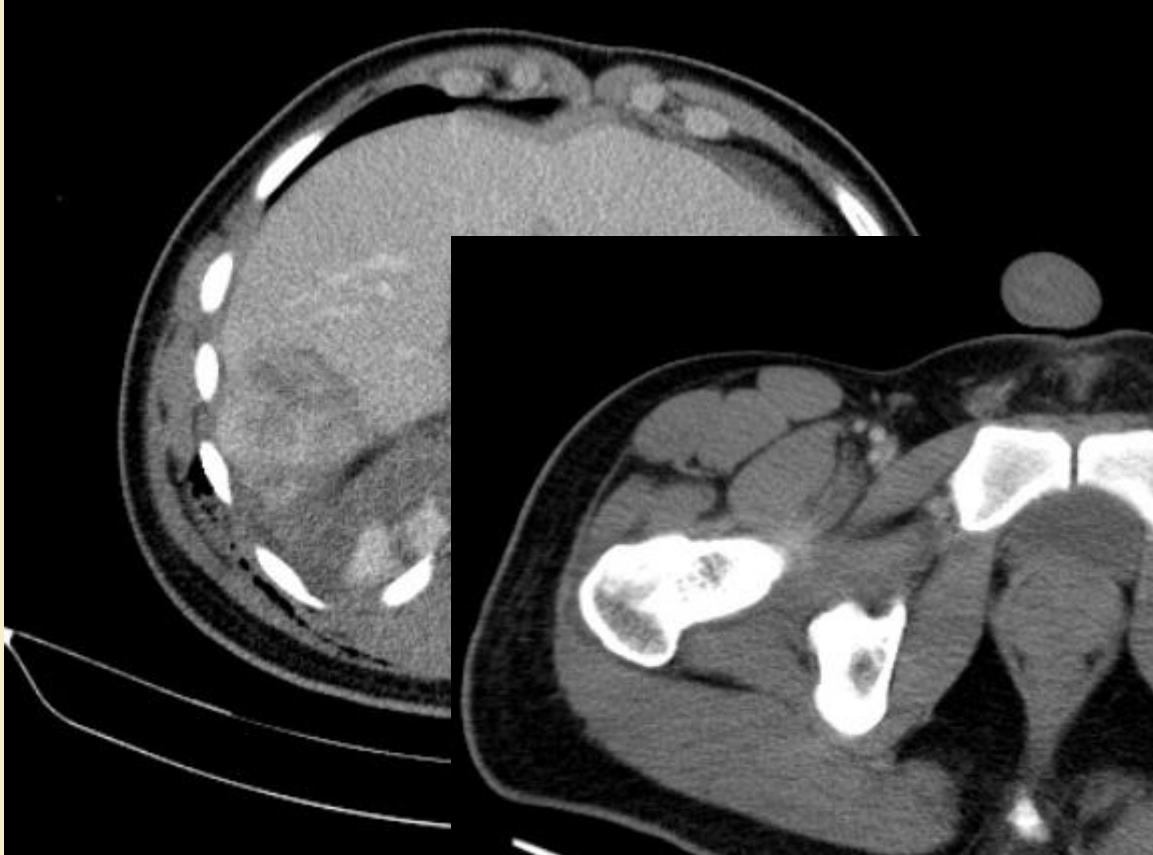
* 這位病人從未插管 *



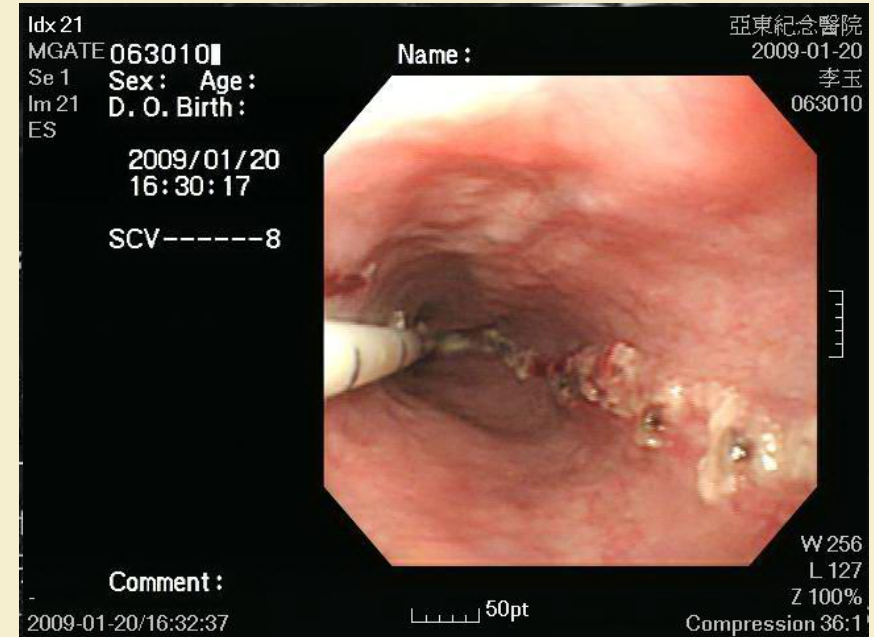
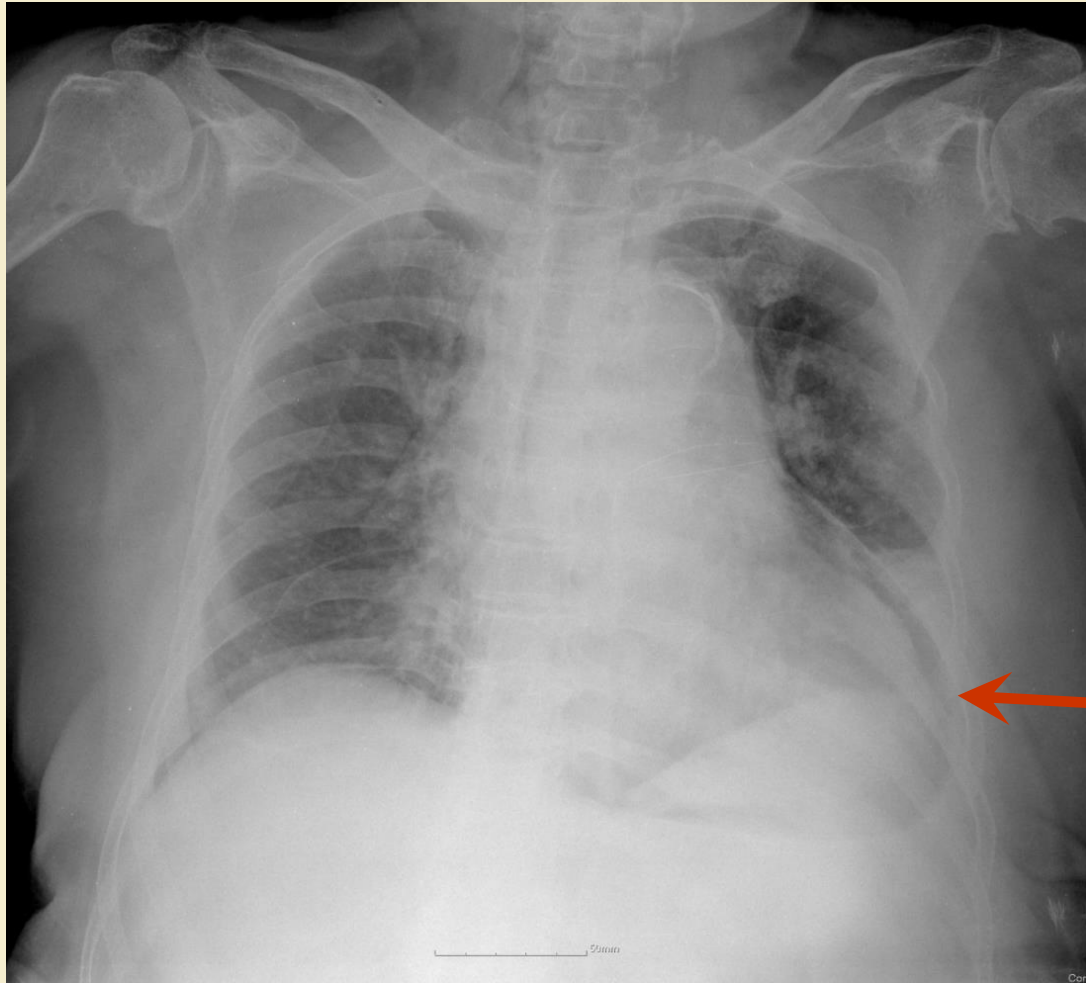
ORIF for Flail chest



所謂禍不單行

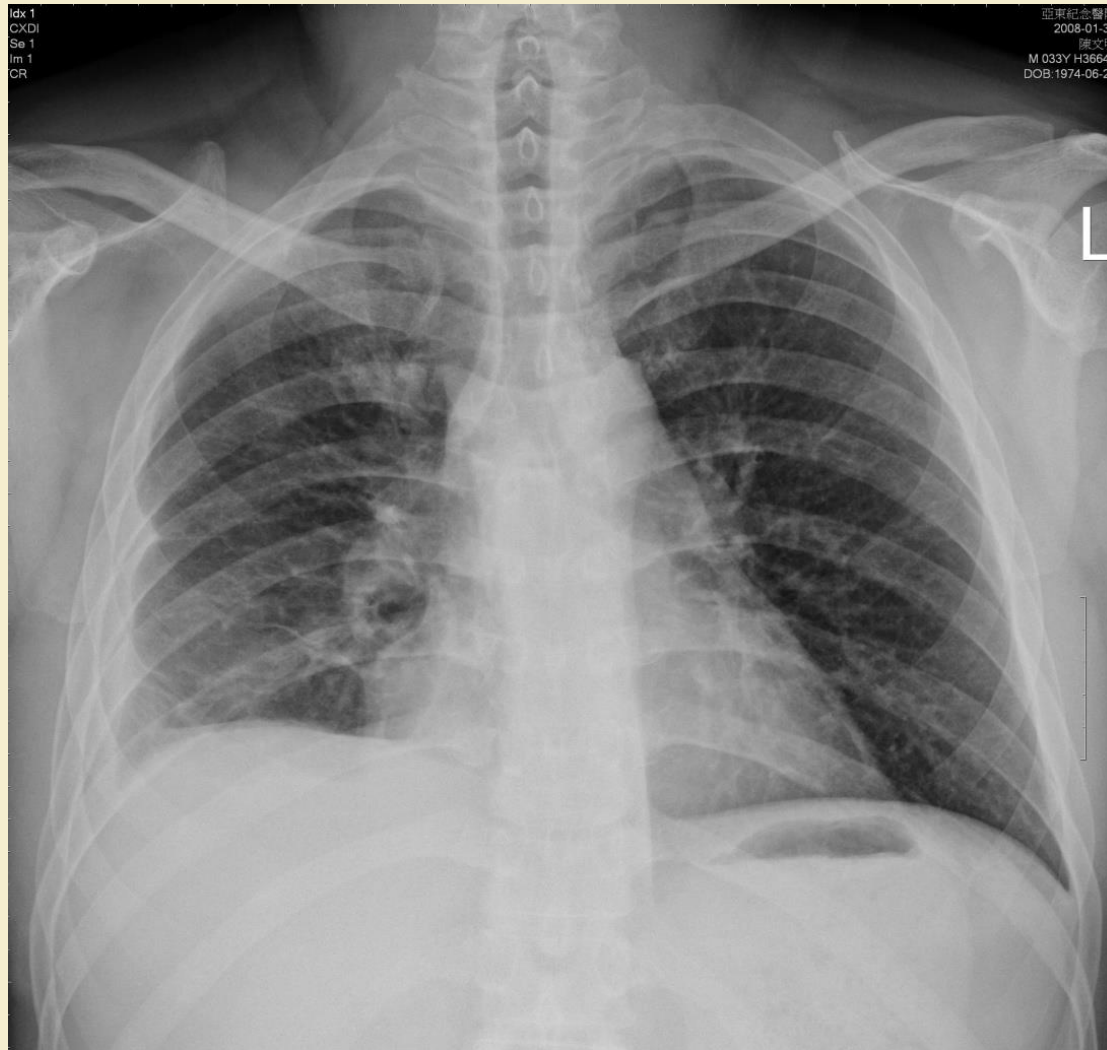


Pneumo - pericardium



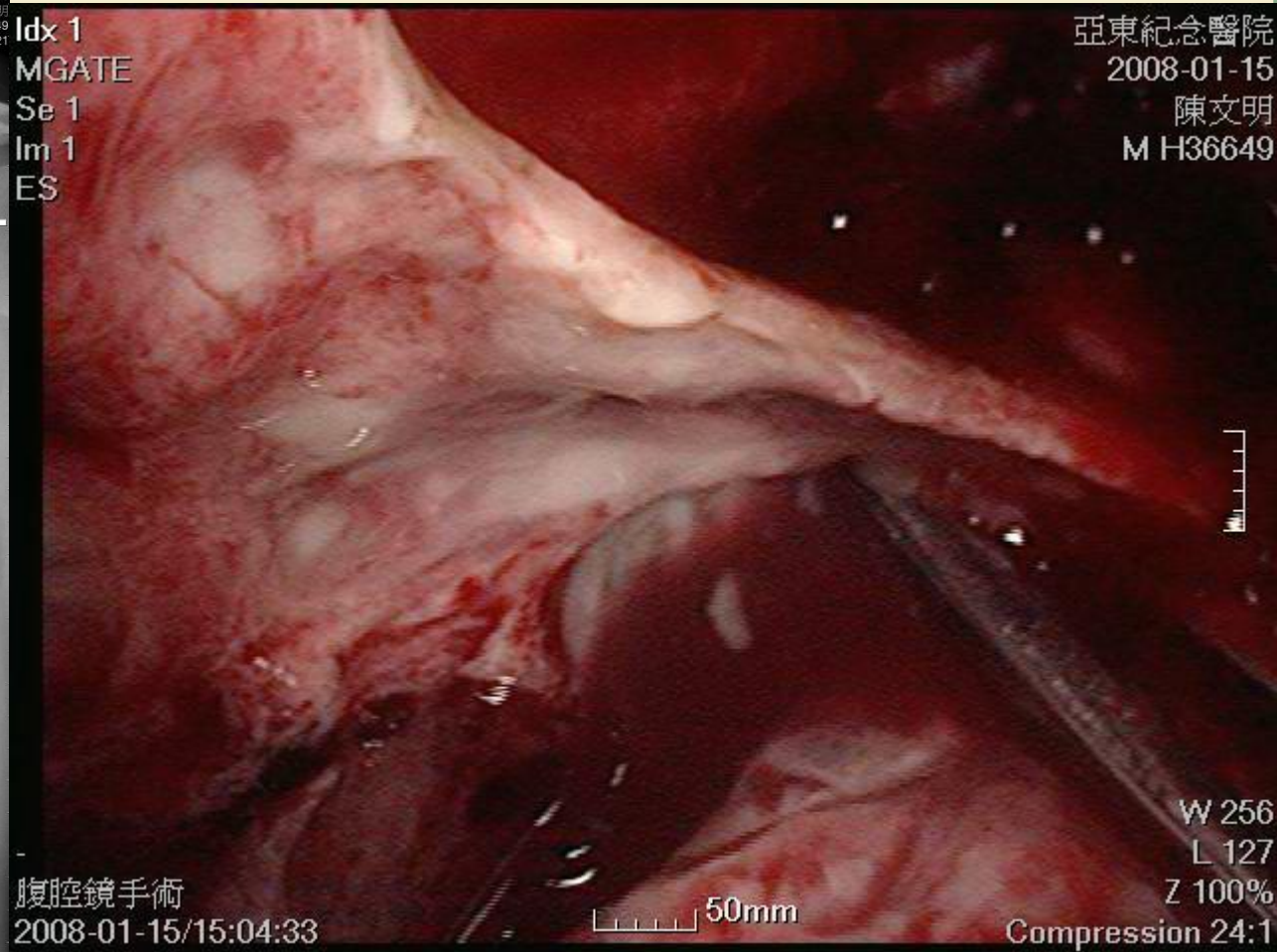
看到空氣了嗎?

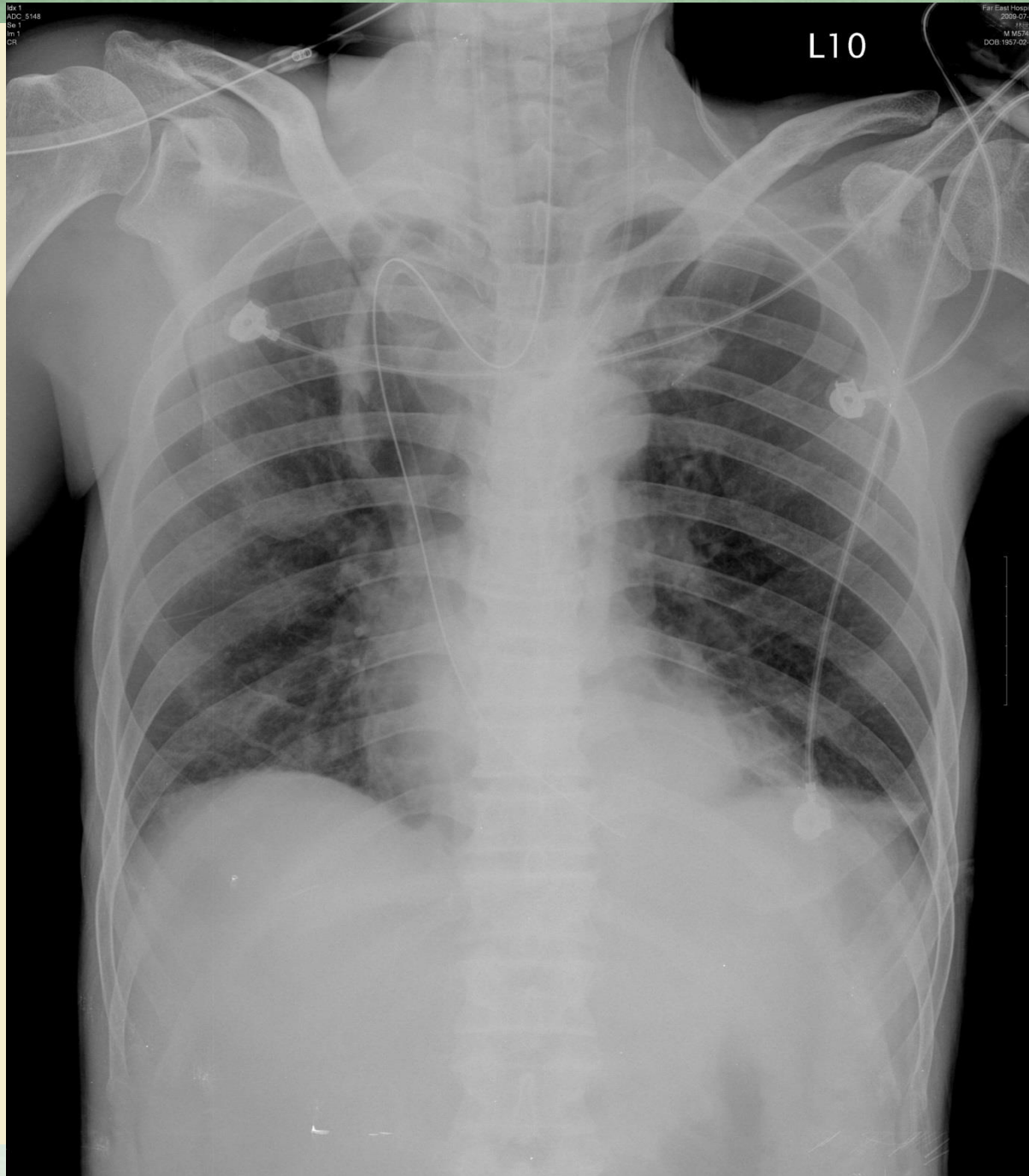
Empyema – VATs decortication



Idx 1
MGATE
Se 1
Im 1
ES

腹腔鏡手術
2008-01-15/15:04:33



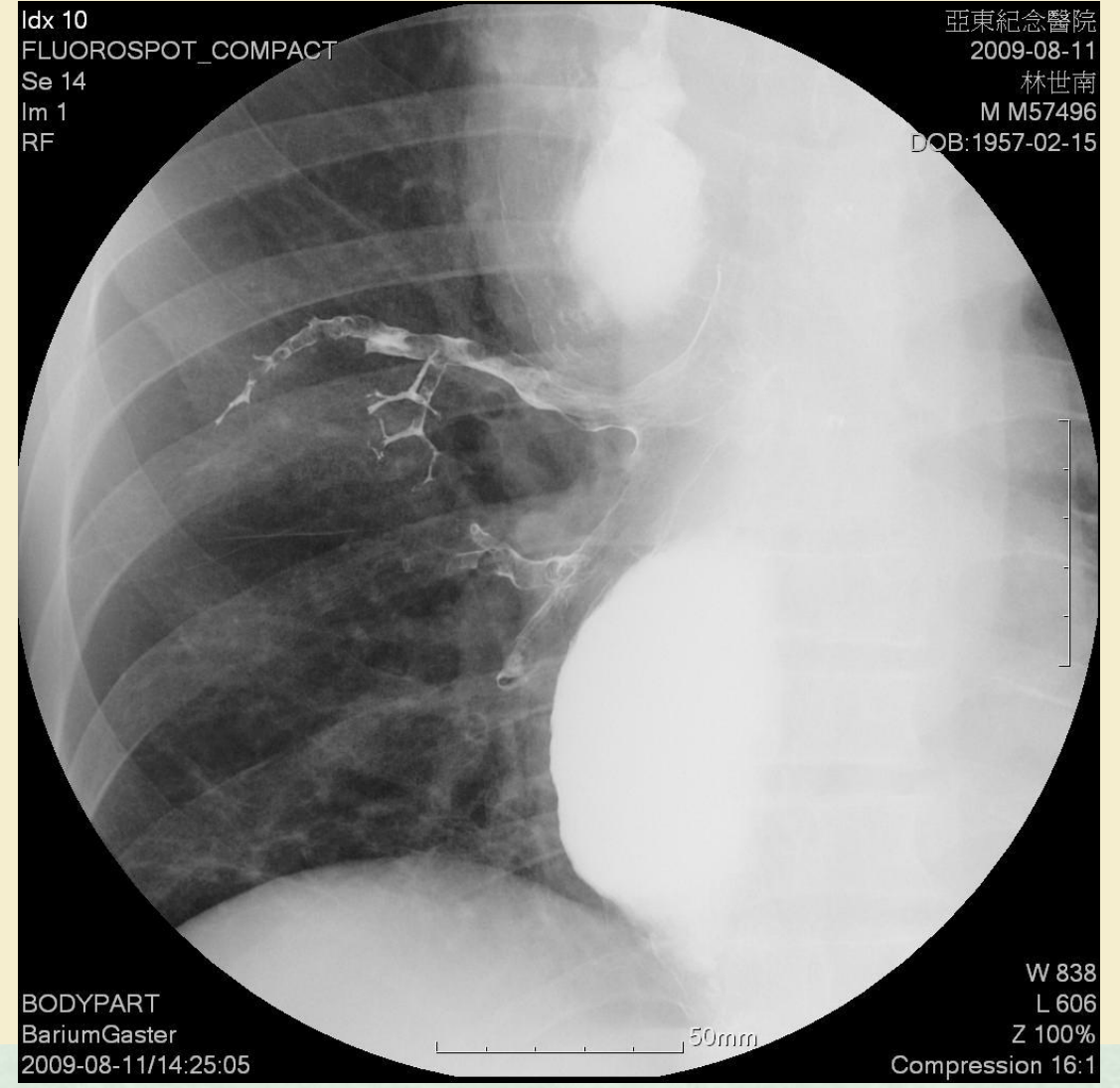


Idx 1
ADC 5148
Se 1
Im 1
CR

Fair East Hospital
2009-07-29
11:58:38
M M57496
DOB:1957-02-15

L10

GU perforation s/p op Is anything wrong?



Idx 10
FLUOROSPOT_COMPACT
Se 14
Im 1
RF

亞東紀念醫院
2009-08-11
林世南
M M57496
DOB:1957-02-15

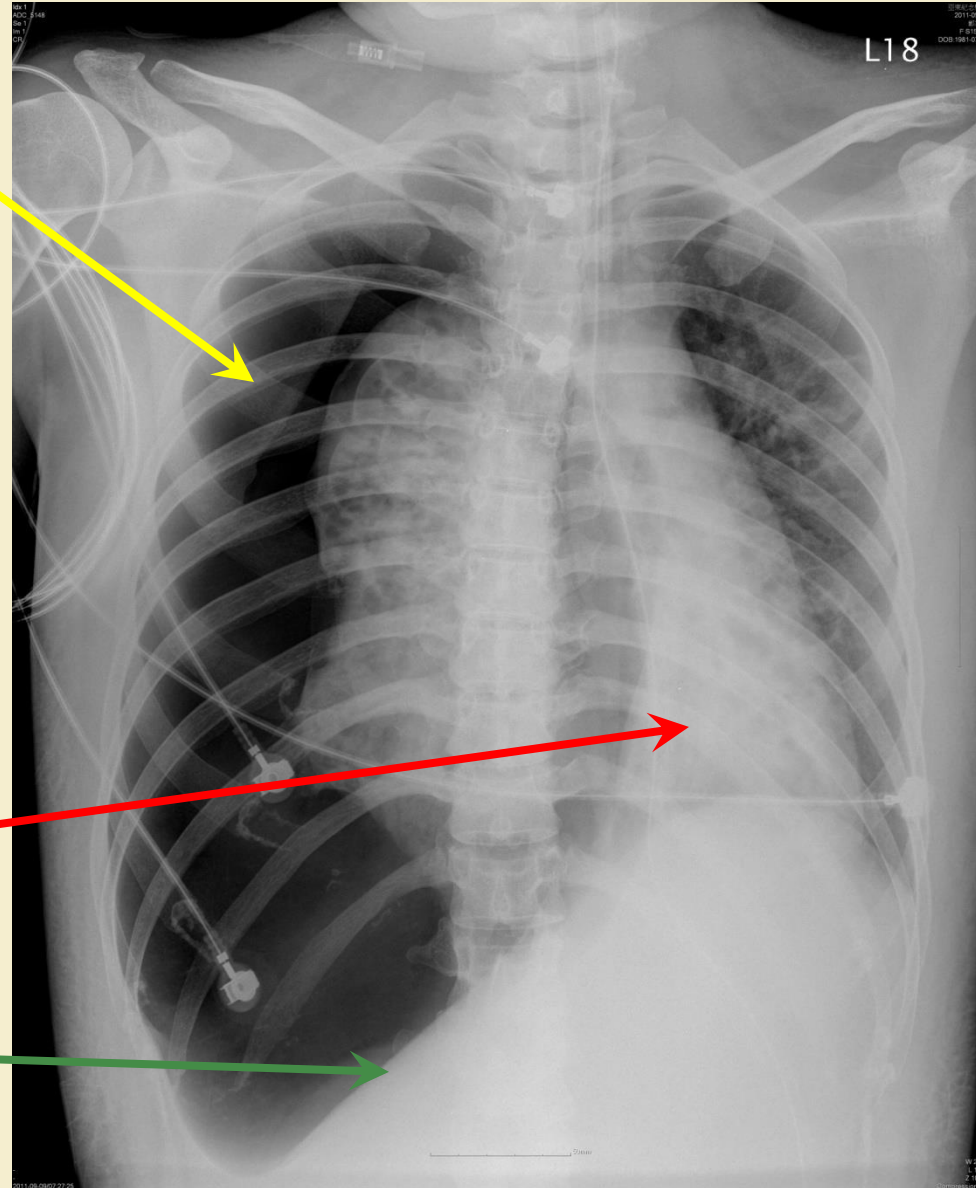
BODYPART
BariumGaster
2009-08-11/14:25:05

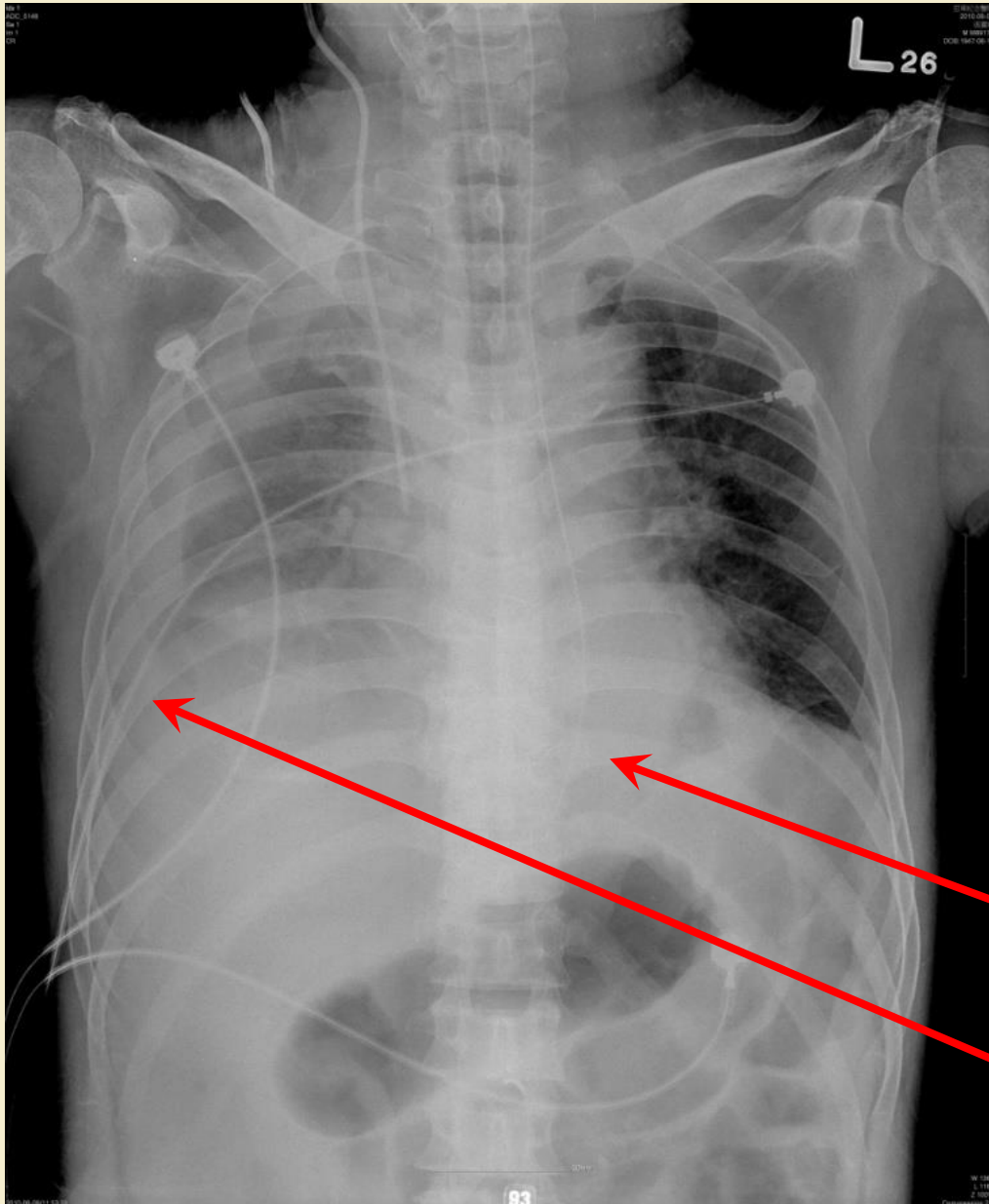
W 838
L 606
Z 100%
Compression 16:1

50mm

Tension pneumothorax

- PE一定比X光快
- Chest ECHO
- “理論上”，不應該看到這張X光片
- Heart
- Diaphragm

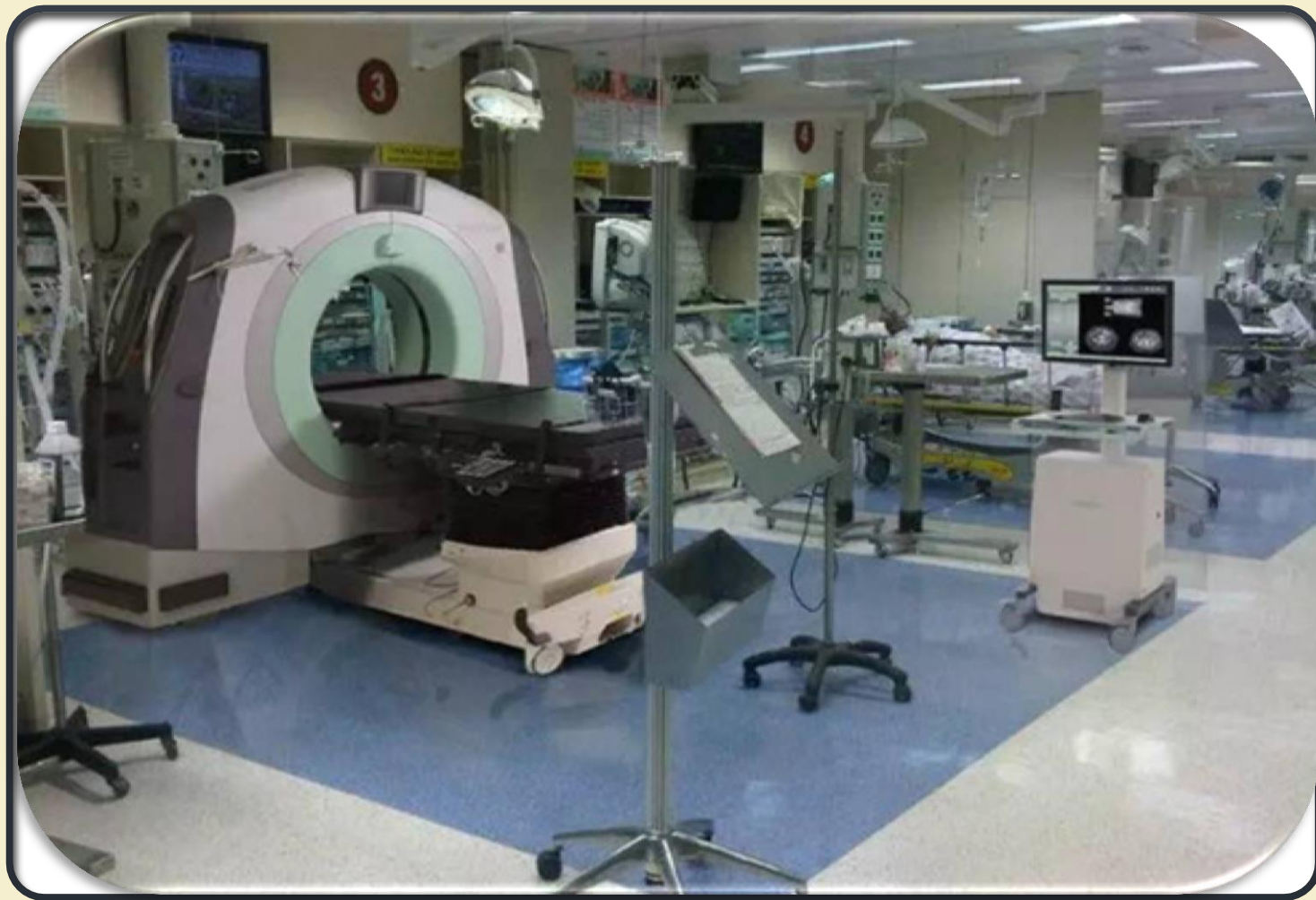



What can we do better ?

- LGI active bleeding
→ Hemorrhagic shock
→ Emergent operation
- What else?

20100606



不是只有X 光能推著走

首台由美國NeuroLogica
公司研製生產的超大口徑
(85cm) 移動式32排全
身CT BodyTom正式入駐
浙江大學醫學院附屬邵逸
夫醫院。2016/07/29

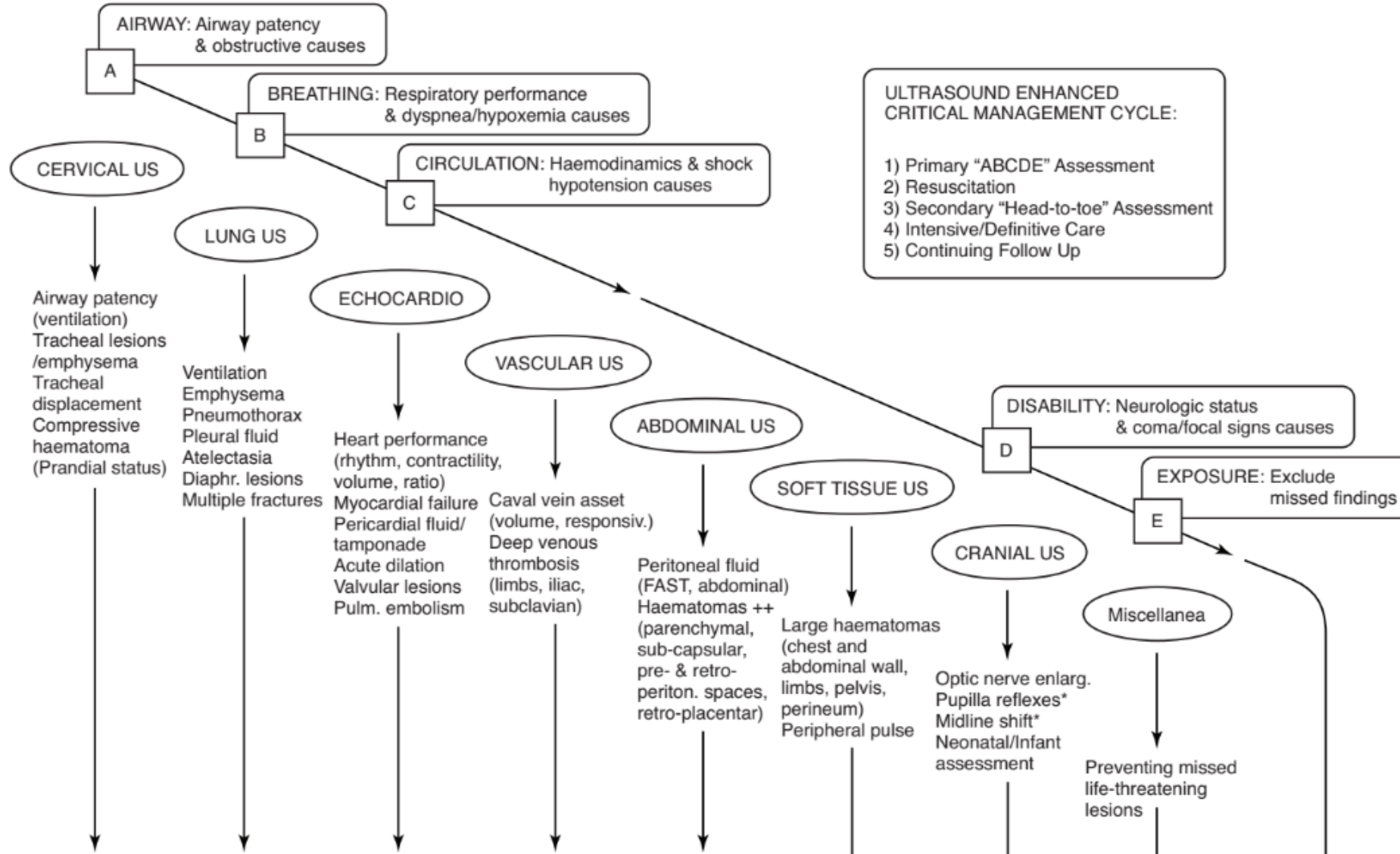
Ultrasonography in the Critical Care Unit , Point-of-care ultrasonography (POCUS)

whole body ultrasonography

- Lung Ultrasonography: pneumothorax, pulmonary edema, pleural effusion
- Cardiac function: tamponade signs
- Abdominal ECHO: Free fluid, Free air or other clinically indicated abdominal pathologies like hydronephrosis
- Lower extremity: DVT study

"LEVEL 1" ULTRASOUND LEARNING GOALS in TRAUMA CRITICAL CARE

1. "ABCDE" PRIMARY ASSESSMENT (Vital signs, anomalies, detectable causes, responses, complications)



2. "ABCDE" RESUSCITATION (Electric, Fluid/Drug, Interventional)

2. "ABCDE" RESUSCITATION (Electric, Fluid/Drug, Interventional)

Airway device management: naso-/oro-tracheal intub., cricothyrotomy, tracheotomy, tracheostomy

Needle torachocentesis
Chest tube insertion
Thoracotomy

Pericardio-centesis
Thoracotomy

Diagnostic paracentesis
DPL/Mini-laparotomy
Laparotomy (intra/post-operative)

Central & peripheral vascular puncture, venous cutdown, intraosseous puncture (confirmation)*
Nasogastric tube insertion, Urinary catheterization/Cystocentesis, Pre-/intra-/post- operative applications ...

Fluid therapy management (input, output)
Drug therapy management (inotropes, thrombolytics, diuretics, antidotes)

Defibrillation (recovery, PEA vs pseudo-PEA)
Pacing (mechanical capture, intra-venous guidance)

3. "HEAD-to-TOE" SECONDARY ASSESSMENT

Skull fractures
Maxillary hemosinus
Transcranial doppler
Ocular lesions

Liver, spleen, kidney, diaphragmatic lesions
Pneumoperitoneum
Retroper. haematomas
Ileum, Intest. Ischemia
Scrotal Trauma

Lung contusions
Rib, sternum fractures
Diaphyseal fractures
Muscular lesions ++
Articular fluid
Haematomas ++

+/- "ABCDE" evaluation

+/- "LEVEL 2" evaluation

4. INTENSIVE/DEFINITIVE CARE

Pre-/intra-/post- operative applications
Loco-regional anaesthesia
Foreign body detection/ extraction ... Others

+/- "ABCDE" applications

+/- "LEVEL 2" applications

5. CONTINUING FOLLOW UP

Serial examinations & monitoring

Assess vital functions, failures, lesions, causes, and anatomic areas - Address electrolyte, fluid/drug and interventional resuscitation
Provide pre-/intra-/post- procedural/operative guidance - Evaluate and monitor treatment efficacy - Detect and treat complications - Re-assess

Advantages

- Rapid
- Repeat
- Non-invasive
- Portable
- No radiation

亞東HBO高 壓氧中心

HBO需使用專用呼吸器
需專人陪艙，CXR，
Tempanostomy，Brain
evaluation



多人艙內急救設備以供危急重症使用呼吸器病人接受高壓氧治療

- 呼吸器



具有轉移艙供人員緊急進出

轉移艙



全民健保支付高壓氧治療之適應症

- 1.減壓症(俗稱潛水夫病)或急性氣栓塞症。
- 2.氣壞疽病(包含氣壞疽及厭氧細菌感染及壞死性軟組織感染及混合性細菌感染)。
- 3.一氧化碳中毒(氰化物及氣體中毒)。
- 4.慢性復發性骨髓炎。
- 5.肢體壓傷伴有創傷性出血，高壓氧壓力50呎與高壓氧時間120分鐘。
- 6.急性燒灼傷、二至三度燒傷，表面積介於15%~90%(限皮膚移植可能失敗或不能確定效果或以往有皮膚移植失敗病史病人)。
- 7.放射性組織壞死(放射性骨壞死及放射性膀胱炎、放射性腸炎)。

全民健保支付高壓 氧治療之適應症 需事前申請經核准之適應症

- 1.慢性復發性骨髓炎。
- 2.急性燒灼傷、二至三度燒傷，表面積介於15% ~ 90%(限皮膚移植可能失敗或不能確定效果或以往有皮膚移植失敗病史病人)。
- 3.肢體壓傷伴有創傷性出血，高壓氧壓力50呎與高壓氧時間120分鐘。

突發性失聰

傷口癒合不良(糖尿病、褥瘡)

視網膜中心動脈組塞

慢性中風復健病患

自費接受治療

急性大出血，不接受輸血者

血管傷害與肢體殘障

神經壓迫病變或斷裂(顏面神經麻痺、脊髓損傷)

部分運動傷害及肌肉痠痛

預防保健、抗衰老、皮膚美容

植牙傷口癒合不良

腦膿瘍

放線菌感染症

危象皮瓣移植

Hyperoxic hypoxic paradox

間歇性的高氧暴露引起許多在缺氧期間發生的生理反應
 HBOT誘導稱為低氧誘導因子 (HIF) 的轉錄因子的釋放，並增加其穩定性和活性。反過來，HIF-1 α 和HIF-2 α 調節血管生成因子血管內皮生長因子的釋放 (VEGF)，VEGF被認為是血管生成的主要調節劑

