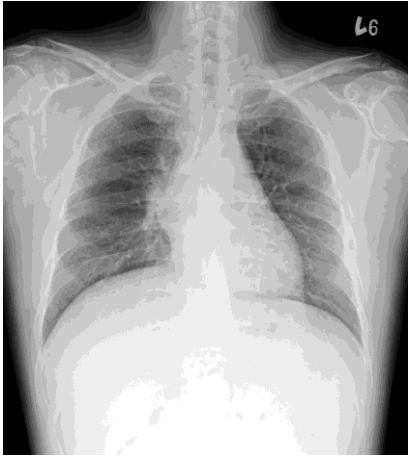

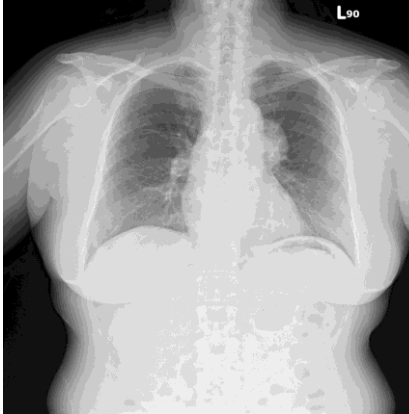


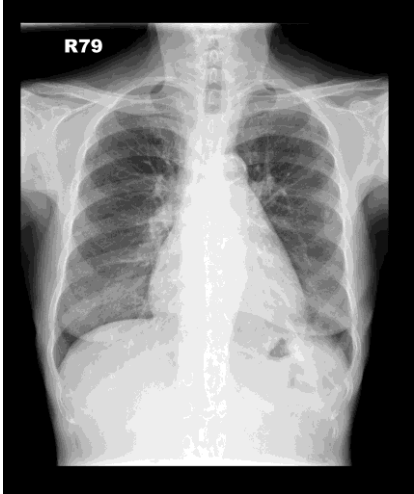




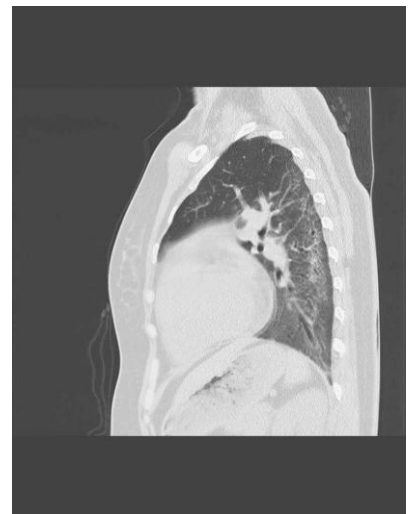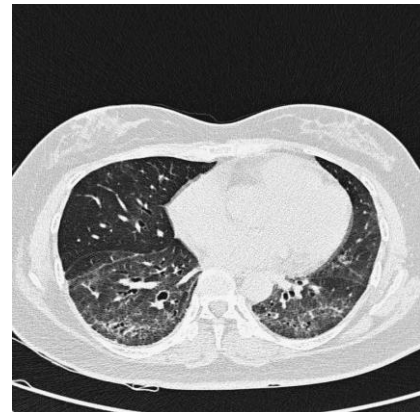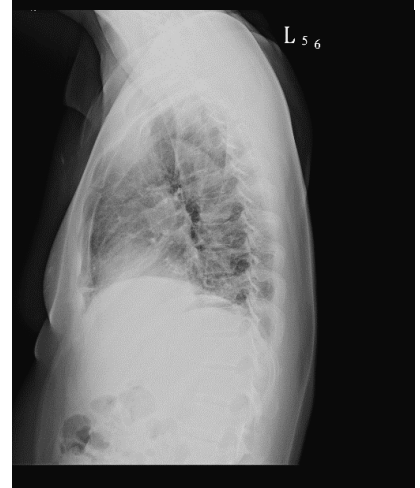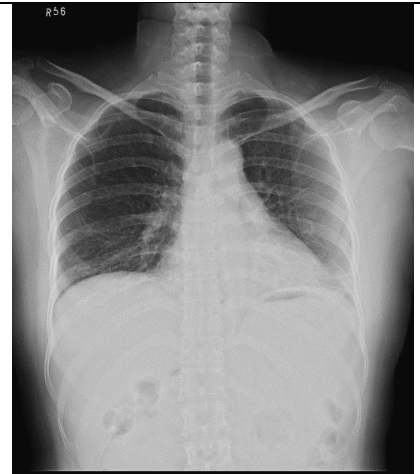
題目	答案	影像
1. A 36-year-old man had an incidental finding of an abnormal chest X-ray during a health examination. No any clinical symptoms.	Primary mediastinal diffuse large B cell lymphoma	
2. A 70-year-old female presented with a two-month history of shortness of breath.	Adenocarcinoma of lung, LUL, with bilateral lung metastasis and lymphangitic carcinomatosis	
3. A 52-year-old female had an incidental finding of an abnormal chest X-ray during a health examination. No any clinical symptoms.	Thymoma	
4. A 75-year-old male had right-sided chest pain for five months.	Mesothelioma	

題目	答案	影像
5. A 68-year-old man presented with an intermittent cough for six months.	Thymic carcinoma with bilateral lung metastases	 A frontal chest X-ray showing bilateral lung metastases and a large thymic mass. The label 'R 87' is visible in the top left corner.
6. A 74-year-old female presented swallowing difficulty for 2-3 months.	Adenocarcinoma of lung in LLL with dysphagia due to esophageal stricture secondary to compression by metastatic mediastinal lymphadenopathy	 A frontal chest X-ray showing a large mediastinal mass compressing the esophagus. The label 'R79' is visible in the top left corner.
7. A 25-year-old woman had blood-tinged sputum for months.	Sequestration Lung abscess Lung cancer	 A frontal chest X-ray showing a large lung mass and sequestration. The label 'R 87' is visible in the top right corner.

114 年 胸 腔 暨 重 症 專 科 醫 師 考 試 _ 影 像 學		
題目	答案	影像
8. A 74-year-old woman had fever and chillness for 1 week.	Septic emboli	

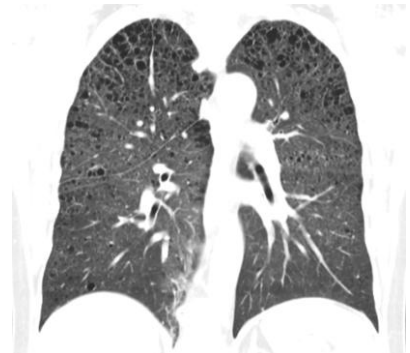
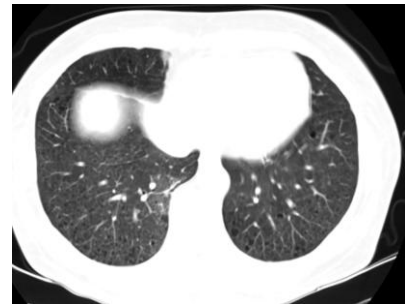
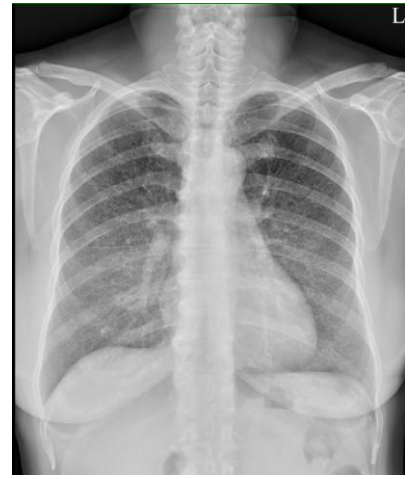9. A 46-year-old female, experienced exertional dyspnea and weight loss, and presented with puffy hands and Raynaud's phenomenon.

Interstitial lung disease (fibrotic NSIP)



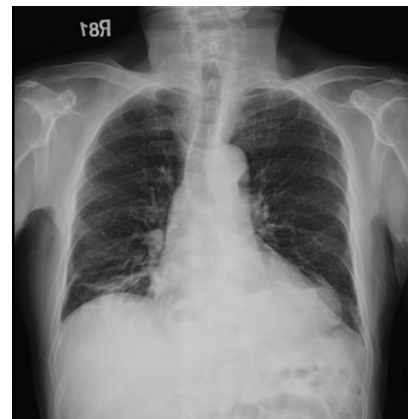10. Dyspnea


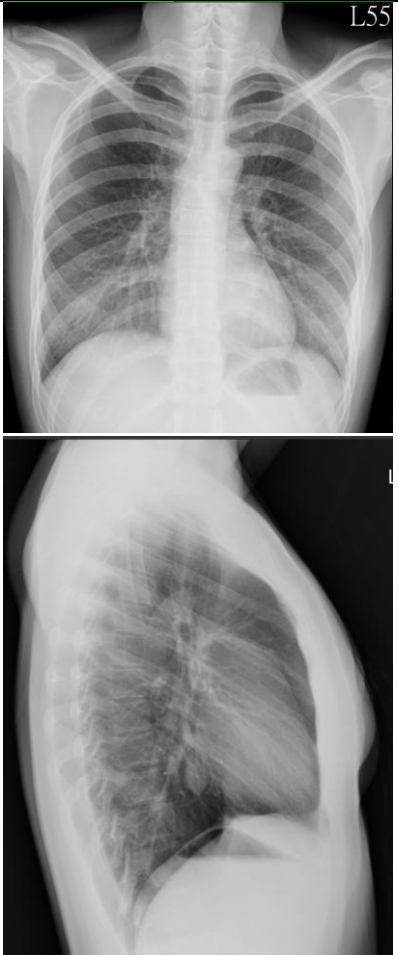

Lymphangioleiomyomatosis

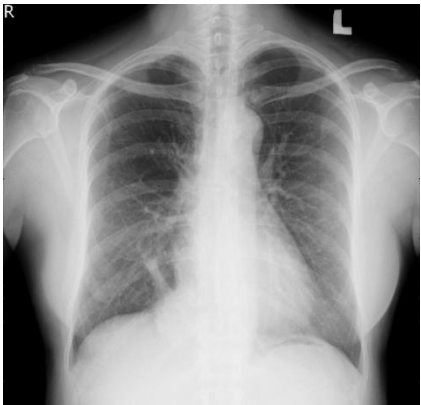




11. Chronic cough

Hiatus hernia

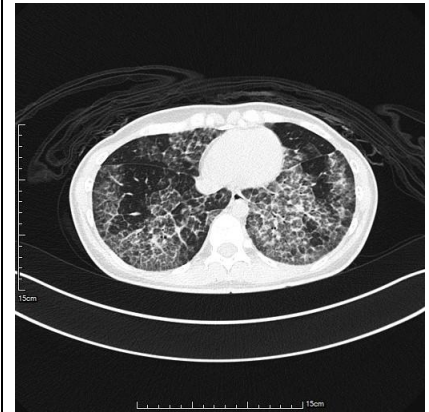
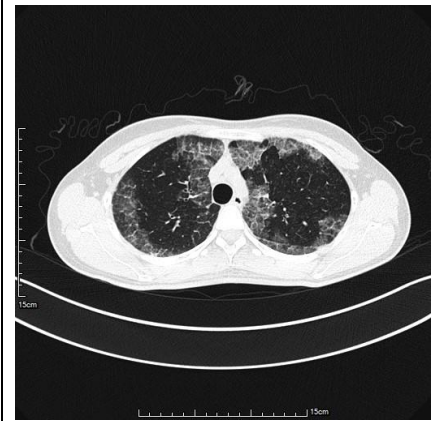


<p>12. A 22 y/o male had this chest X-ray on his regular check-up. No any clinical symptoms.</p>	<p>Funnel chest</p>	 <p>A frontal chest X-ray of a 22-year-old male. The image shows a significant depression of the sternum, characteristic of funnel chest (pectus excavatum). The lungs appear clear, and the heart size is within normal limits. The label 'P25' is visible in the top left corner.</p>
<p>13. A 36 y/o female had this chest X-ray on his regular check-up. No any clinical symptoms.</p>	<p>Bronchogenic cyst</p>	 <p>Two chest X-rays of a 36-year-old female. The top image is a frontal view showing a well-defined, rounded opacity in the lower lung field, consistent with a bronchogenic cyst. The label 'L55' is visible in the top right corner. The bottom image is a lateral view showing the same opacity, confirming its location in the posterior lower lung field.</p>
<p>14. A 30-year-old female presented with body weight loss 5kg within 6 months</p>	<p>Anterior mediastinal tumor / lymphoma</p> <p><alternate></p> <p>Thymoma, germ cell tumor</p>	 <p>A frontal chest X-ray of a 30-year-old female. The image shows a large, well-defined, rounded opacity in the anterior mediastinum, consistent with a thymoma or germ cell tumor. The label 'R-SITTING' is visible in the top left corner. The lungs appear clear, and the heart size is within normal limits.</p>

<p>15. A 51-year-old woman had this chest X-ray on her health exam. No clinical symptoms.</p>	<p>Pulmonary sequestration</p>	
<p>16. A 68-year-old man presented with loss of voice and progressive shortness of breath for 1 month.</p>	<p>Thyroid cancer with lung metastasis Airway compression</p>	
<p>17. A 72-year-old man presented with intermittent chest pain for 2 weeks.</p>	<p>LUL lung cancer (with nodal metastasis)</p>	

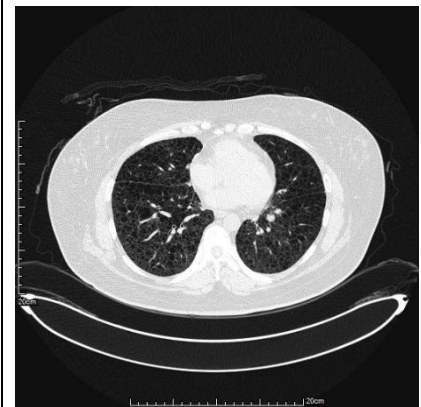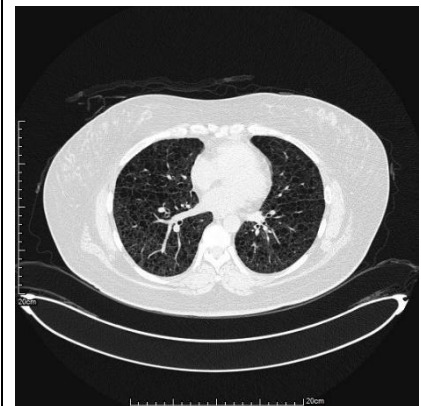18. A 28 y/o female with slight chronic cough

Pulmonary alveolar proteinosis



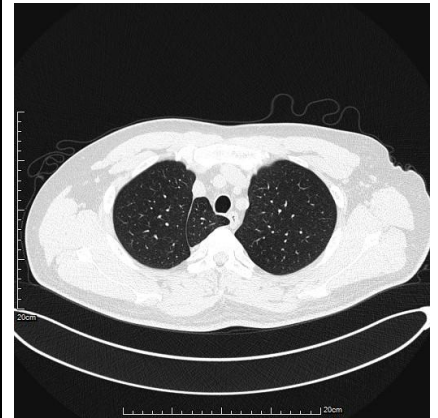
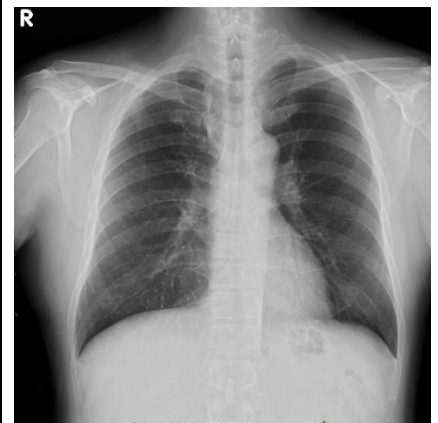
19. A 35-year-old with progressive short of breath

LAM(Lymphangioliomyomatosis)



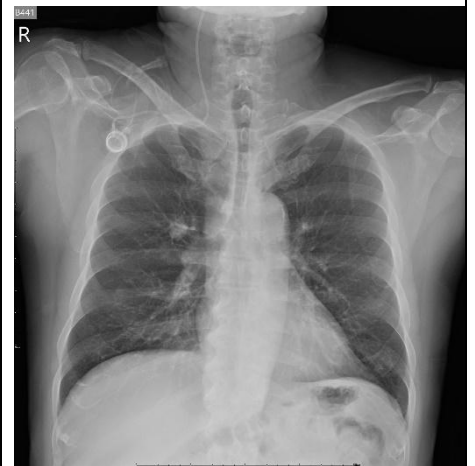
20. A 54year-old man had this chest X-ray on his health exam. No any clinical symptoms.

Azygos lobe



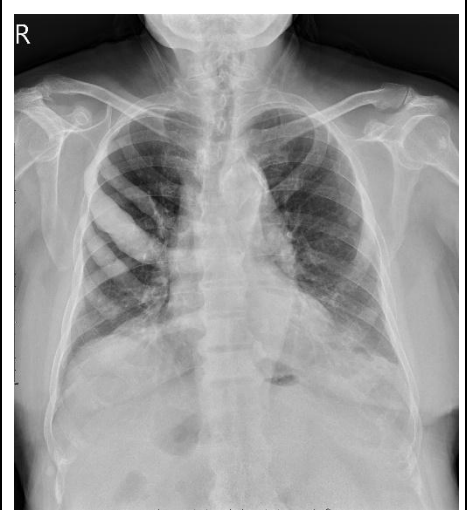
21. A 54 year-old male with SCLC

Malposition of Port-A catheter (with the tip in jugular vein)



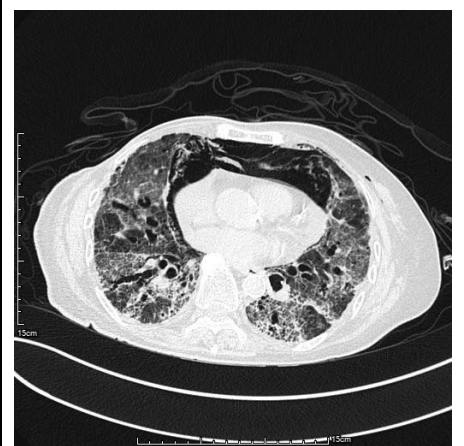
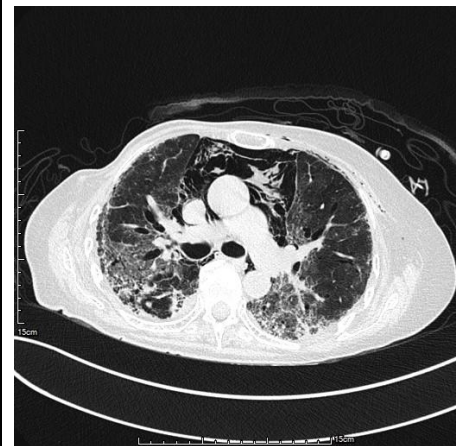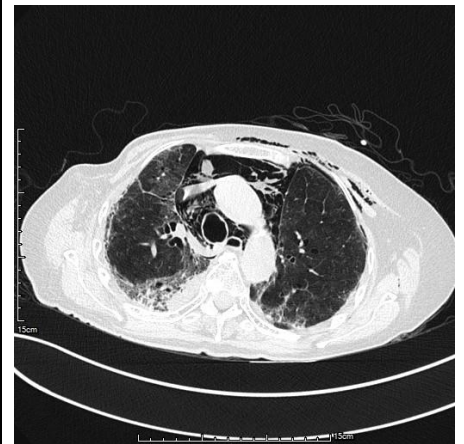
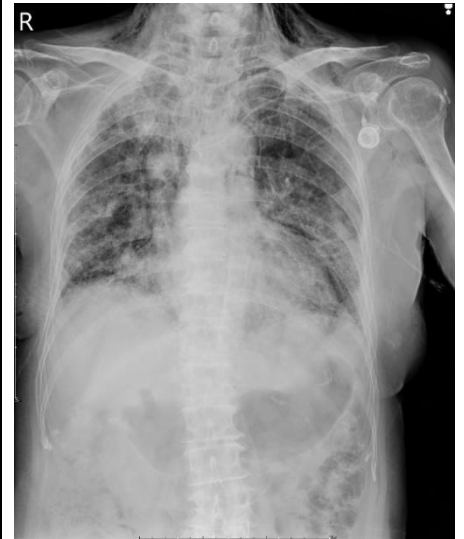22. A 93 y/o male patient with slight breathing difficulty

Osteoblastic bony metastasis of ribs (Prostate cancer)



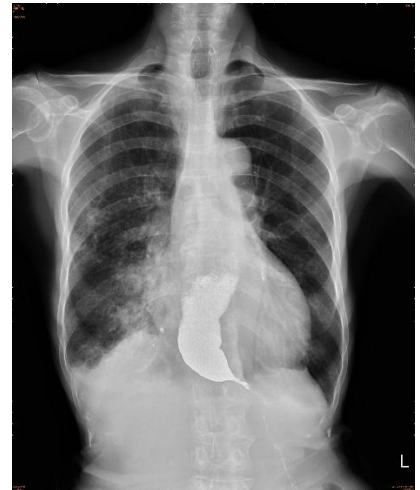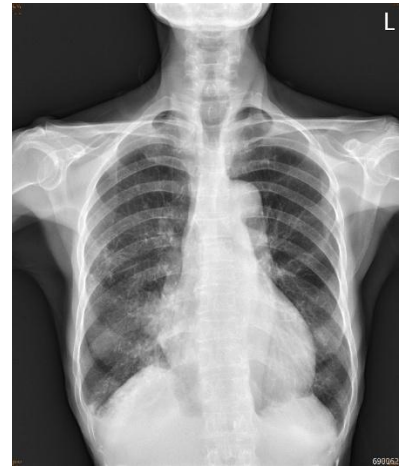23. A 74 year-old female with
Right breast cancer,s/p
operation, post-
radiotherapy & adjuvant
chemotherapy

Pulmonary fibrosis (stiff lung),
Abemaciclib (CDK4/6 inhibitor)
drug-related, with right
pneumothorax &
pneumomediastinum



24. A 70 year-old female complained of dysphagia and fever.

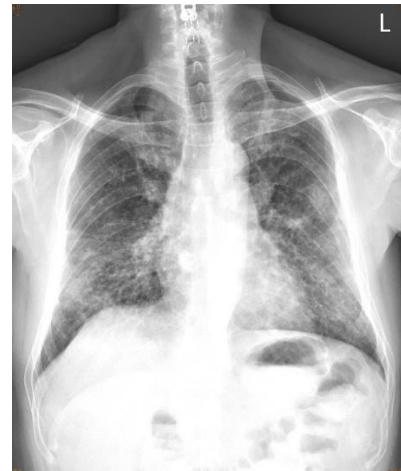Achalasia






25. A 45 year-old, male, carpenter; intermittent dyspnea during his working days

Fibrosing hypersensitivity pneumonitis

CT available: three density sign



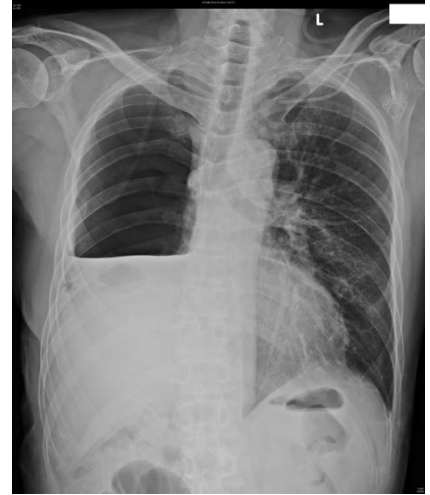<p>26. A 71 year-old, chronic cough with yellowish sputum, dyspnea</p>	<p>Kartagener's syndrome (situs inversus, bronchiectasis)</p>	
<p>27. A 25 year-old male, recurrent pneumonia and hemoptysis</p>	<p>Pulmonary sequestration (CT: feeding artery from aorta)</p>	
<p>28. A 36 year-old male, asymptomatic, for abnormal CXR</p>	<p>Right side aorta</p>	

29. A 54 y/o man, dry cough
without dyspnea

Status post right pneumonectomy

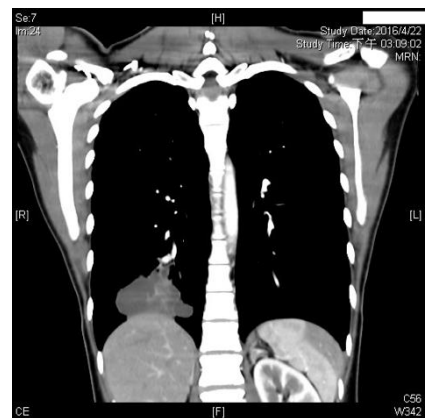
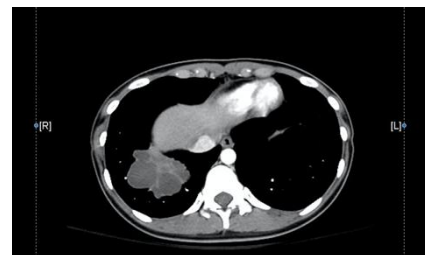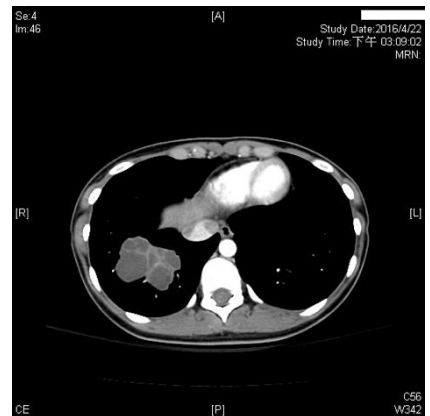
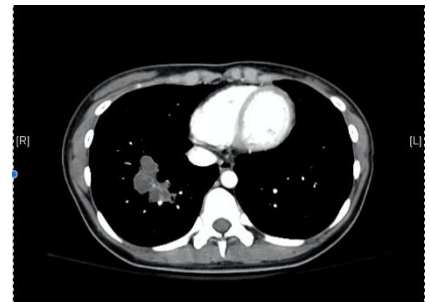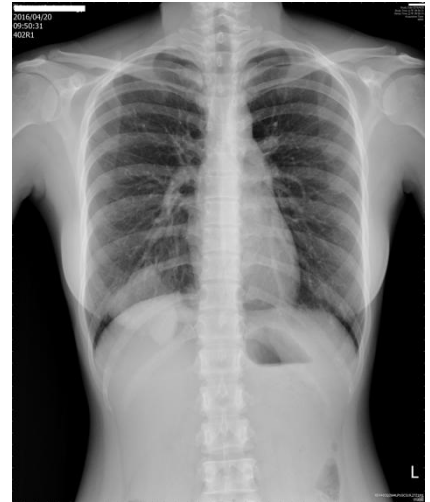Right hydropneumothorax

s/p left chemo-port implantation



30. A 21 y/o women, no cough,
no dyspnea

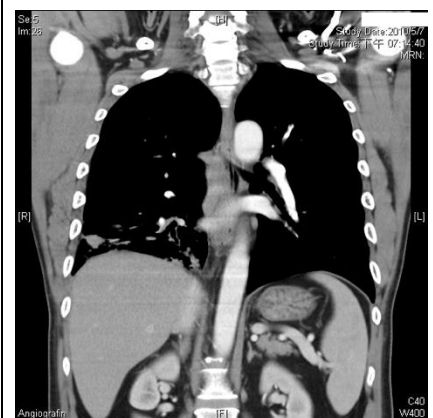
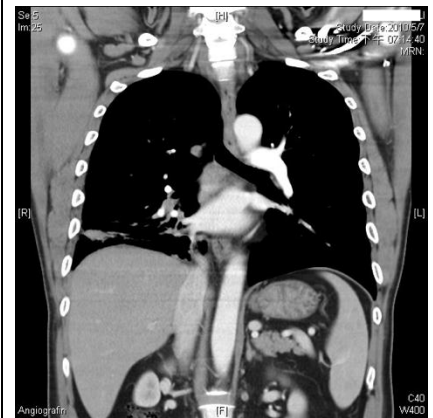
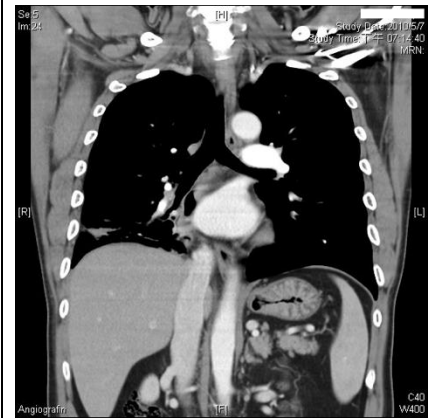
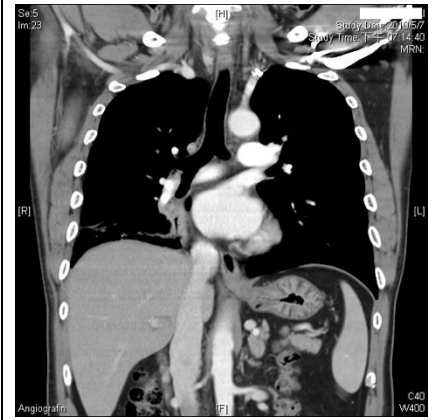
Congenital cystic adenomatous
malformation, type I

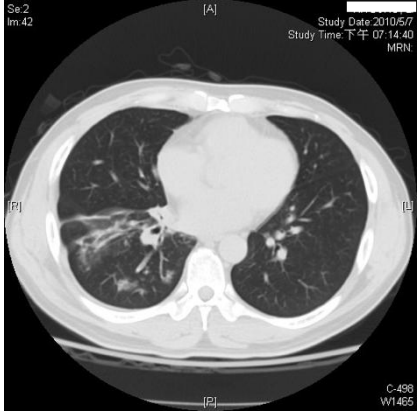
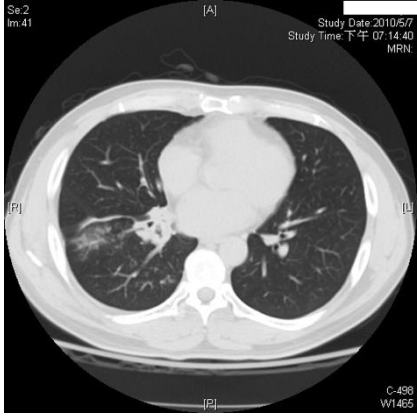
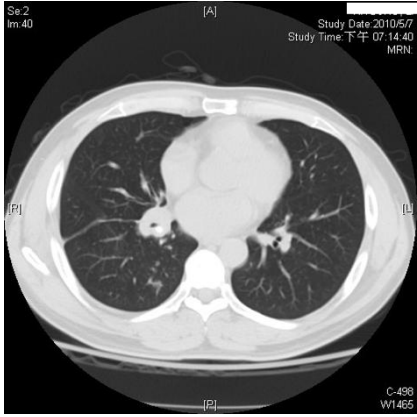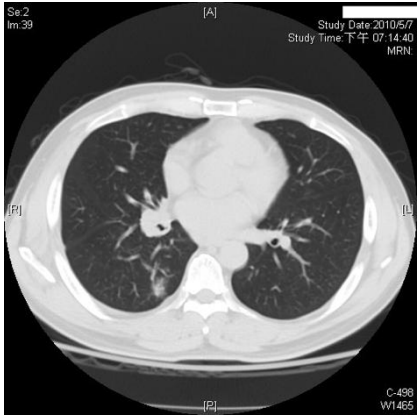


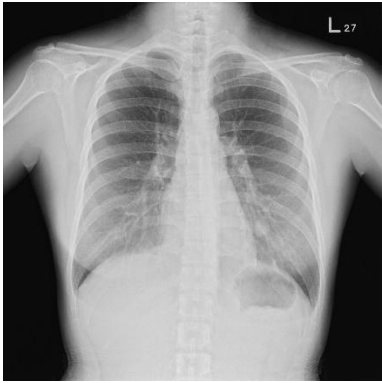

31. A 51 y/o man, foul smell sputum was noted for one year

Right lower lung bronchus foreign body impaction

Right lower lung consolidation





<p>32. A Female, 28 y/o, Routine check-up</p>	<p>Pulmonary hamartoma, LLL</p>	 
<p>33. A Male, 51 y/o, Left chest pain for one week</p>	<p>Thymoma with pleural seeding</p>	